



This is a digital copy of a book that was preserved for generations on library shelves before it was carefully scanned by Google as part of a project to make the world's books discoverable online.

It has survived long enough for the copyright to expire and the book to enter the public domain. A public domain book is one that was never subject to copyright or whose legal copyright term has expired. Whether a book is in the public domain may vary country to country. Public domain books are our gateways to the past, representing a wealth of history, culture and knowledge that's often difficult to discover.

Marks, notations and other marginalia present in the original volume will appear in this file - a reminder of this book's long journey from the publisher to a library and finally to you.

Usage guidelines


Google is proud to partner with libraries to digitize public domain materials and make them widely accessible. Public domain books belong to the public and we are merely their custodians. Nevertheless, this work is expensive, so in order to keep providing this resource, we have taken steps to prevent abuse by commercial parties, including placing technical restrictions on automated querying.

We also ask that you:

- + *Make non-commercial use of the files* We designed Google Book Search for use by individuals, and we request that you use these files for personal, non-commercial purposes.
- + *Refrain from automated querying* Do not send automated queries of any sort to Google's system: If you are conducting research on machine translation, optical character recognition or other areas where access to a large amount of text is helpful, please contact us. We encourage the use of public domain materials for these purposes and may be able to help.
- + *Maintain attribution* The Google "watermark" you see on each file is essential for informing people about this project and helping them find additional materials through Google Book Search. Please do not remove it.
- + *Keep it legal* Whatever your use, remember that you are responsible for ensuring that what you are doing is legal. Do not assume that just because we believe a book is in the public domain for users in the United States, that the work is also in the public domain for users in other countries. Whether a book is still in copyright varies from country to country, and we can't offer guidance on whether any specific use of any specific book is allowed. Please do not assume that a book's appearance in Google Book Search means it can be used in any manner anywhere in the world. Copyright infringement liability can be quite severe.

About Google Book Search

Google's mission is to organize the world's information and to make it universally accessible and useful. Google Book Search helps readers discover the world's books while helping authors and publishers reach new audiences. You can search through the full text of this book on the web at <http://books.google.com/>



Library
of the
University of Wisconsin



16-D-11

A Text Book of Veterinary Pathology

A TEXT BOOK
OF
**VETERINARY
PATHOLOGY**

FOR
STUDENTS AND PRACTITIONERS

BY
A. T. KINSLEY, M. Sc., D. V. S.
Pathologist, Kansas City Veterinary College

FULLY ILLUSTRATED

CHICAGO
ALEXANDER EGER
1910

Copyrighted at Washington, D. C., by
ALEXANDER EGER
1910

LINDEN BROS. PRESS, CHICAGO

151250

MAR 22 1911

RSL

K52

ATD 11-10

PREFACE.

A knowledge of pathology is essential to practitioners and to students of medicine. The general considerations of pathology, whether in reference to diseases of the human or diseases of domestic animals, are practically identical. Many textbooks on this subject are available, but they are especially written for the practitioner and student of human medicine, and the illustrations and examples are all in reference to diseases of the human. Such textbooks have been used by the author for several years in veterinary classes and it was thought that if the same general pathological principles could be exemplified by cases and illustrations in veterinary medicine, the subject matter would be more readily understood by the veterinary student. This explains the issuance of the present volume.

The writer has endeavored to place every phase of pathology from the veterinarian's point of view. The entire subject matter has been expressed as far as possible in common everyday language, with the hope that all readers will have no trouble in grasping the pathologic facts. An extensive glossary has been appended and will be of considerable aid because practically every technical term, with its analysis and definition, will be found therein.

The author is greatly indebted to Dr. S. Stewart, Dean of the Kansas City Veterinary College; Dr. D. M. Campbell, editor of *The American Journal of Veterinary Medicine*; Prof. W. E. King, Bacteriologist of the Kansas State Agricultural College; Dr. F. J. Hall, Chief of the Food Inspection Department Kansas City, Mo., and formerly pathologist of the Medical Department University of Kansas; Dr. L. Rosenwald, formerly pathologist of the Kansas City Veterinary College; Dr. Geo. F. Babb, Milk Inspector of the city of Topeka, Kansas; Dr. D. Champlain, editor of *The Milk-Man*, for suggestions made by them concerning the text matter. Also Dr. R. F. Bourne, physiologist of the Kansas City Veterinary College; Dr. C. D. Folsie, City Milk and Meat Inspector of Marshall, Texas, and Mr. Chas. Salsbery, microscopic laboratory assistant in the Kansas City Veterinary College, for their assistance in the preparation of the illustrations.

The author consulted various text-books, journals and other publications while preparing the text for which acknowledgment is hereby made.

If this book supplies the practitioner and the student of veterinary medicine with clear, concise statements of veterinary pathology, the purpose of the book has been fulfilled.

A. T. K.

ERRATA.

- On Page iii—Line 13 from top—should read—"Epithelioma,"
instead of Epitheloma.
- On Insert I next to page 44—Title should be "Botanical Names"
instead of "Botanical Name."
- On Page 68—Last line Fig. 39, "Filaria Papillosa after Neuman,"
should be placed a line above.
- On Page 230—Headline should read "Calculi," instead of Caculi.
- On Page 34—Line 7 from bottom—Should read "Digestic,"
instead of Digestice.
- On Page 75—Fig. 50—Should read "Echinorhynchus." instead of
Echinorynchus.

CONTENTS.

	PAGE
Preface	5
CHAPTER I.	
Definitions	19
The Cell	20
CHAPTER II.	
General Consideration of Disease	34
Table of Vegetable Parasites	48
Saccharomyces	51
Schizomycetes	52
Animal Parasites	62
Protozoa	63
Helminthes	63
Arthropoda	69
CHAPTER III.	
Immunity	78
CHAPTER IV.	
Malformations	92
CHAPTER V.	
Circulatory Disturbances	110
Hemorrhage	112
Lymphorrhagia	117
Oedema, Dropsy or Hydrops	118
Thrombosis	122
Embolism	128
Ischemia	132
Hyperemia (Passive)	133
Hyperemia (Active)	135
CHAPTER VI.	
Inflammation	138
CHAPTER VII.	
Progressive Tissue Changes	177
Regeneration	177

	AGE
Wound Healing	183
Hypertrophy	188
Hyperplasia	191
Metaplasia	193

CHAPTER VIII.

Retrogressive Tissue Changes	195
Atrophy	196
Cloudy Swelling	200
Fatty Changes	203
Amyloid Changes	210
Hyaline Changes	212
Mucoid Changes	214
Colloid Changes	217
Serous Infiltration	220
Glycogenic Infiltration	221
Uratic Infiltration	223
Keratosis	224
Ossification	226
Calcareous Infiltration	227
Calculi	230
Concrements	238
Pigmentary Changes	241
Excessive Pigmentation	243
Absence of, or Diminished Pigmentation.....	249

CHAPTER IX.

Necrosis and Death	251-262
Physiologic Death	262
Pathologic Death	263

CHAPTER X.

Tumors	267
Fibroma	278
Mixoma	282
Chondroma	283
Osteoma	288
Glioma	289
Odontoma	289
Neuroma	293
Angioma	293
Myoma	296
Sarcoma	298

	PAGE
Papilloma	318
Embryonic Epithelial Tumors	321
Placentoma	331
Teratoma	332
Cysts	335
 CHAPTER XI. 	
Fever	339
 CHAPTER XII. 	
Infective Granulomata	344
Tuberculosis	344
Actinomycosis	345
Glanders	361
Epitheloma Contagiosum	371
Glossary	373

LIST OF INSERTS.

Insert I—Botanical Names	Next to page 45
Insert II—Bacteria	Next to page 62
Insert III—Protozoa	Next to page 63
Insert IV—Helminthes	Next to page 66
Insert V—Arthropoda	Next to page 71
Table I— Table of Tumors	Next to page 335

A LIST OF THE ILLUSTRATIONS.

FIGURE	PAGE
1—Diagram of a Typical Cell.....	21
2, 3—Amitosis	25
4—Division of Nucleus.....	26
5—Division of Cell.....	26
6—Cell in Resting Stage.....	27
7—Prophase, Showing Division of Centrosome.....	27
8—Prophase, Showing Separation of Centrosomes.....	27
9—Metaphase	27
10, 11, 12, 13—Indirect Cell Division—Metaphase, Anaphase, Telophase	28
14—Ciliated Epithelium, Trachea.....	29
15—Spermatozoa	30
16—Red Buckeye.....	46
17—Astragalus Molissimus	47
18—Trichophyton Tonsurans	49
19—Aspergillus Fumigatus	50
20—Saccharomyces Farcimosus	51
21—Group Bacteria	53
22, 23—Group Bacteria	53
24—Flagellate Bacteria	54
25—Capsulated Bacteria	54
26—Bacterial Fission	56
27—Sporulation	57
28—Bacillus Anthracis	59
29—Bacillus Tetani	60
30—Piroplasma Bigeminum	62
31—Trypanosoma Evansi (From Kaupp Parasites).....	63
32—Sarcocystis Miescheri (From Kaupp Parasites).....	64
33—Taenia Marginata	65
34—Taenia Canina	66
35—Taenia Echinococcus	66
36—Taenia Solium	67
37—Strongylus Micrurus	67
38—Strongylus Paradoxus	68
39—Filaria Papillosa	68
40—Oxyuris Curvula	69
41—Syngamus Trachealis	70
42—Sclerostoma Hypostomum	70
43—Trichocephalus Depressiusculus	70
44—Melophagus Ovinus	71

FIGURE	PAGE
45— <i>Gastrophilus Equi</i>	72
46— <i>Oestrus Ovis</i>	72
47— <i>Culex Pungens</i>	73
48— <i>Ascaris Mystax</i>	74
49— <i>Distoma Hepaticum</i>	74
50— <i>Echinorhynchus Gigas</i>	75
51— <i>Trichina Spiralis</i>	76
52— <i>Trichodectes Latus</i>	76
53— <i>Hematopinus Phalanges Ovis</i>	79
54— <i>Pulex Serraticeps</i>	79
55— <i>Margarapus Annulatus, Female</i>	80
56— <i>Margarapus Annulatus, Male</i>	80
57— <i>Margarapus Annulatus, Female laying eggs</i>	80
58— <i>Margarapus Annulatus Larva</i>	80
59— <i>Ixodes Ricinus</i>	81
60— <i>Psoroptes Communis Ovis</i>	82
61— <i>Demodex Folliculorum Canis (From Kaupp Parasites)</i>	83
62—Immunity, Bacterial	85
63— <i>Hematoba Serrata</i>	86
64—Immunity, Toxin	86
65— <i>Uncinaria Canina</i>	88
66—Cranio, Schisis	95
67—Chelio, Schisis	96
68—Palato, Schisis	97
69—Abdomino, Schisis	97
70— <i>Synophthalmia</i>	98
71— <i>Solipedia</i>	99
72—Polydactilism	100
73—Prognathism	101
74—Schistosis, <i>Melus Anticus</i>	102
75—Ectocardia	104
76—Dicephalic, Calf	108
77—Dicephalic, Calf	108
78—Petechial Hemorrhage	113
79—Hematoma	114
80—Ascites, Dog	119
81—Subcutaneous Oedema, Horse	120
82—Thrombus in Vessels	125
83—Thrombus, Red	126
84—Embolism	129
85—Infarction, Spleen	130
86—Hyperaemia Hemorrhage and Oedema Intestine	135
87—Hyperaemia Kidney	136
88, 89, 90, 91—Vascular Variations in Inflammation.....	147-148-149-150
92—Types of Cells in Inflammatory Exudates	151
93—Gastritis	153
94—Acute Pleurisy	154

FIGURE	PAGE
95—Acute Meningitis	156
96—Grey Hepatization	157
97—Fibrinous Pleurisy	158
98—Myositis, Acute	160
99—Chronic Pneumonia	162
100—Chronic Hepatitis	165
101—Pus, from a case of Strangles	168
102—Suppurative Nephritis	170
103—Red Hepatization	172
104—Vascular Regeneration	178
105—Fibrous Regeneration	179
106—Wound Healing	185
107—Exuberant Granulation	187
108—Hyperplasia Interstitial Testicular Cells	191
109—Hyperplasia Ureter	192
110—Metaplasia	194
111—Cloudy Swelling	201
112—Fatty Infiltration, Liver	206
113—Fatty Degeneration, Liver	209
114—Amyloid Degeneration, Liver	212
115—Hyaline Degeneration, Vessels	213
116—Mucoid Degeneration	216
117—Colloid Degeneration	218
118—Colloid Degeneration	219
119—Keratotic Growth	225
120—Atheromatus Degeneration	229
121—Group Calculi	230
122—Vesicular Calculi	233
123—Preputial and Renal Pelvic Calculi	234
124—Salivary Calculi	235
125—Intestinal Calculus	236
126—Biliary Calculi	237
127—Hair Balls	239
128—Inspissated Pus	240
129—Hemosiderin Pigmentation	244
130—Icteric Pigmentation	246
131—Necrosis	253
132—Bacillus Necrophorus	254
133—Ergot	255
134—Ergot Poisoning Cattle	256
135—Fatty Necrosis	258
136—Necrotic Center of Tubercle	259
137—Sarcoma	270
138—Metastatic Sarcomata	273
139—Epithelioma, Horse Head	275
140—Hard Fibroma	279
141—Soft Fibroma	280

FIGURE	PAGE
142—Myxoma	282
143—Chondroma	284
144—Lipoma, Horse	286
145—Lipoma, Ox	287
146—Osseous Tumor, Maxilla	288
147—Odontoma, Horse	290
148—Odontoma, Epithelial	292
149—Hemangioma, Simplex	294
150—Hemangioma Cavernosum	295
151—Hemangioma Hypertrophicum	296
152—Leiomyoma, Small Intestine	297
153—Leiomyoma, Microscopic	298
154—Sarcoma, Horse	299
155—Sarcoma Mediastinum (Sections of Tumor)	300
156—Sarcoma, Round Cell	301
157—Lympho-Sarcoma Heart	302
158—Lympho-Sarcoma	303
159—Spindle Cell Sarcoma, Mule	304
160—Spindle Cell Sarcoma	305
161—Myeloid or Giant Cell Sarcoma	306
162—Mixed Cell Sarcoma, Horse	307
163—Mixed Cell Sarcoma, Jaw	308
164—Mixed Cell Sarcoma	309
165—Alveolar Sarcoma	310
166—Endothelioma	311
167—Endothelioma	312
168—Uterine Sarcoma	313
169—Melano-Sarcoma, Horse	314
170—Melano-Sarcoma, Hog Skin	315
171—Melano-Sarcoma, Microscopic, of Horse's Liver	316
172—Myxo-Sarcoma	317
173—Papillomatosis, Horse	319
174—Papilloma, Microscopic	320
175—Carcinoma	322
176—Epithelioma, Microscopic	323
177—Epithelioma, Microscopic	324
178—Epithelioma, Pearl Cell	325
179—Adenoma, Mammae	326
180—Adenoma, Microscopic	327
181—Adeno-Sarcoma, Microscopic	328
182—Cystadenoma	329
183—Hypernephroma	330
184—Dermoid Cyst	332
185—Dermoid Cyst, Eye	333
186—Dentigerous Cyst	334
187—Cyst, Dog Neck	336
188—Uterine Cyst	337

FIGURE	PAGE
189—Fever—Crisis and Lysis	340
190—Continuous Fever	342
191—Remittent Fever, Curve	342
192—Intermittent Fever, Curve	343
193—Bacterium Tuberculosis, Bovine	345
194—Small Cellular Tubercular Liver	348
195—Tuberculosis Lesion Later	350
196—Tuberculosis Mammary Gland	351
197—Ray Fungus (Actinomyces)	356
198—Actinomycotic Tongue	359
199—Bacillus Mallei	362
200—Glanders Lesion, Farcy	365
201—Glanders, Nasal Ulcer	366
202—Glanders, Microscopic	367
203—Epithelioma, Contagiosum	369
204—Epithelioma, Contagiosum	370
205—Epithelioma, Contagiosum, Microscopic	371

CHAPTER I.

DEFINITIONS.

Pathology is the science of disease. It is the science which treats of the nature, causes, progress, symptoms and termination or result of disease. It includes etiology, i. e., the study of the causes of disease, and pathogenesis, that is, the study of the course, abnormal functions and lesions produced in disease.

General Pathology is confined to the explanation of the summary of the facts obtained in the study of special pathology. It is concerned essentially in the solution of general principles of those morbid conditions that are common to the entire organism, as malformation, degeneration, regeneration, inflammation, neof ormation and fever.

Special Pathology deals with all the abnormalities or diseased conditions of one part or organ as the diseases of the ear, skin, etc., and consequently special pathology is further subdivided into otologic pathology, dermatologic pathology, etc.

Pathologic Physiology, is that part of pathology which has to do with the investigation and description of abnormal functions of a diseased organ or animal. The pathologic physiology is, in many cases, the principle symptom of a disease, e. g., paralysis of the radial nerve. Abnormal function is frequently the only evidence discernible in a disease, e. g., epilepsy.

Pathologic Anatomy, or morbid anatomy, is concerned in the structural changes in a diseased tissue or organ. Pathologic changes in the structure of a tissue or organ are collectively termed lesions. Lesions may be sufficiently gross that they are readily observed with the unaided eye or they may be so minute that the microscope is necessary for their detection. The investigation and the recording of facts observed in the study of gross and minute lesions are included in gross, or macroscopic pathologic anatomy and minute, or microscopic pathologic anatomy respectively.

Human Pathology has to do with the facts observed in the study of the diseases of the human.

Comparative Pathology, is the name applied to the study of the diseases of all animals in which the diseases of one genus, (group of animals) is taken as a standard and the diseases of all other animals are discussed in comparison with the type selected.

Veterinary Pathology, is a discourse on the diseases of domestic animals.

THE CELL.*ANATOMIC.**Structure.**Body.**Nucleus.**Centrosome.**Membrane.**Shape.**Size.**PHYSIOLOGIC.**Growth.**Reproduction.**Motion.**Metabolism.**Anabolism.**Katabolism.**IRRITABILITY.*

Structurally, an animal body is composed of definitely arranged parts, called organs. An organ is a portion of the body having a particular function and is, structurally, a tissue-complex in which each tissue has a certain definite proportion and relation. A tissue is composed of like or similar cells with more or less intercellular substance interposed. The intercellular substance is usually a product of the cells. A cell has been defined as a microscopic mass of protoplasm containing sufficient individuality to possess a life history.

The function of an animal body is the sum total of the correlated functions of its component tissues. The function of a tissue is the sum total of the function of its cells. Thus a cell represents the anatomical or structural unit and the physiologic or functional unit of all animal bodies.

In ancient times disease was thought to be the result of the entrance into the body of some "evil spirit," and the symptoms presented during disease was evidence of the struggle between the body and the "evil spirit." During the middle ages, Hippocrates, "The Father of Medicine," established the Hippocratic Theory of disease. Hippocrates taught, 1st, that the body was composed of four humors, viz., blood, phlegm, yellow bile and black bile; 2nd, that health consisted of the proper balance of the humors; and 3d, that disturbed proportions of the humors resulted in disease.

Modern pathology is based upon the knowledge of cell activities. Virchow was the father of cellular pathology. He first taught the cellular theory to students of pathology and he first advocated it in published articles. Cellular physiology was really an outgrowth of cellular pathology. A knowledge of cells is

indispensable in the study of pathology and a brief description is here appended.

Structure—Cells are variable in structure. The active constituent of all animal cells is protoplasmic in nature. The essential parts of animal cells are the cell-body, nucleus and centrosome.

The cell-body is present in practically all cells. It is composed of semisolid protoplasm, a portion of which is of a stringy

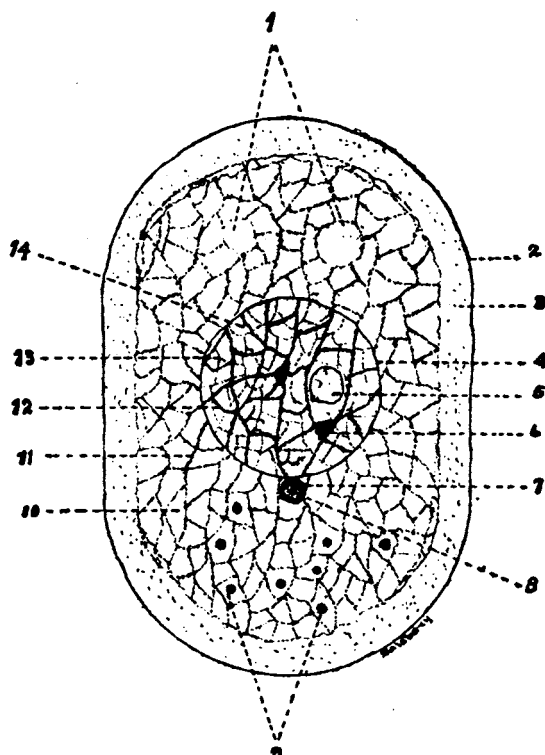


Fig. 1.—Diagram of a Typical Cell, after Böhm-Davidoff-Huber.

- | | |
|------------------------|------------------------|
| 1. Vaxuoles. | 8. Centrosome. |
| 2. Cell-membrane. | 9. Foreign inclosure. |
| 3. Exoplasm. | 10. Hyaloplasm. |
| 4. Nuclear membrane. | 11. Spongioplasm. |
| 5. Nucleolus. | 12. Chromatin network. |
| 6. Chromatin net-knot. | 13. Linin network. |
| 7. Centrosphere. | 14. Nucleoplasm. |

consistency and is termed spongioplasm. In the meshes of the spongioplasm there is found a fluid protoplasm, designated hyaloplasm. The relative proportion of spongioplasm and hyalo-

plasm varies in different cells and even in different parts of the same cell. Particles of food and various other insoluble substances are not uncommon in the cell body. Vacuoles are frequently observed, especially in wandering cells.

The nucleus is constant in all functioning or active cells except the mammalian red blood corpuscles, and some of the pulmonary alveolar epithelial cells. The nucleus appears as a dense body and is usually centrally located in the cell body. The relative proportion of nucleus to cell body is inconstant, e. g., the lymphocyte is practically all nucleus; some epithelial cells have a very small nucleus and a very large cell body. The nucleus varies in shape from a sphere to an irregular mass, and is surrounded by an incomplete membrane. The essential structure of the nucleus is a chromatin network. The spongioplasm and hyaloplasm of the cell body are continuous through the incomplete nuclear membrane into the nucleus where they are designated linin and nucleoplasm respectively. The nucleus may also contain a nucleolus which is probably a knot in the chromatin network.

The centrosome is a dense refractile body found in the nucleus or in the cell body just outside the nuclear membrane. Many fine radiating fibres may extend outward from the centrosome.

A cell membrane may or may not be present. This membrane is formed by a condensation of the substance of the cell body. The sarcolemma of a muscle fibre is perhaps the most typical cell membrane found in animal cells, the red corpuscle has a modified cell membrane. A nerve cell possesses a neurilemma, although it is probably not a true cell membrane.

Shape.—Embryonic cells are usually spherical in shape and it is probable that sphericity is a primitive quality of cells. The shape of matured cells is determined by their function and location. External surface cells are usually flat and when subject to pressure and friction they are arranged in strata, i. e., they are stratified. The cells lining the air vesicles are flat because of the necessity of the exchange of gases through them. Muscle cells are elongated to allow of contraction to produce motion. Goblet cells are large and more or less spherical because of the elaboration of mucus in them. Accommodation to space produces variation in the shape of cells, thus; fat cells are originally spherical, but because of pressure, they become polyhedral. Cells vary from the flat pavement cells to those spherical in shape.

Pressure is probably the most important factor in the produc-

tion of pathologic variation in cell morphology. Thus parenchymatous cells, as hepatic and renal cells, frequently become compressed by hyperplastic interstitial tissue sufficiently to change their shape from polygonal or cuboidal to irregularly flattened or fusiform. Columns of tumor cells may become pressed sufficiently by the invaded tissue to produce scale like cells or the so-called pearl cells. On the other hand, the same variety of tumor cells developed in tissue in which mutual pressure is limited, assume sphericity.

Size.—Cells vary in size from the lymphoid cells that are from 4 to 8 microns in diameter to the marrow cells that are from 30 to 60 microns in diameter. The size of the cell is characteristic of the tissue they compose. Equalization of the surface and mass is a factor in the determination of the size of cells. Function of cells also has some bearing upon their size; thus, cells that have the power of independent motion and rapidly acting cells are usually small. Food is no doubt a determining factor in the size of cells. Ova are large because of the storage of food.

Pathologic variation in the size of cells is of common occurrence. Hypertrophy is the abnormal enlargement of individual cells. The size of red blood cells is variable in pernicious anemia, (swamp fever), of the horse. Several cells may fuse, forming a cell-complex, syncytium, or giant cell in and around foreign bodies, and in tubercular and actinomycotic lesions.

Growth.—Growth in cells is the exercise of that property or function which results in their enlargement or it is the process by which they are increased in size. That cells do grow is self-evident and is common knowledge. A central, polymeric protein-molecule is supposed to be the essential structure of all active cells. This central, polymeric molecule is probably unsaturated and new simple molecules may be serially combined with it and then the cell becomes larger and grows. This property of cells is especially evident during the embryonic period but gradually diminishes to the time of maturity, when it is largely supplanted by other functions. The growth of cells is accompanied by the accumulation of energy. The larger a cell, other things being equal, the greater the potential energy. All functioning of cells, except growth, is accompanied by the liberation of energy. Growth results in accumulation of potential energy and other functions convert potential into kinetic energy, though both types of energy may be produced simultaneously and may be interdependent; thus the growth of muscle is

dependent upon frequent and appropriate exercise (liberation of kinetic energy).

Growth within the normal cell is dependent upon inherited tendencies and a sufficient supply of nutrition. Other functions, as motion, are apparently entirely governed by environmental stimuli plus the required nutrition. The growth of cells continues until they, and the part they compose, become of such a size that the economic relation of surface and mass becomes disproportionate. The disproportionate relation of surface to mass is corrected by rapid cell division or cell dissociation. In either case the total cell surface is increased. According to Harris, "Physiologic inertia" is of considerable importance in growth of cells. When a cell is stimulated to action, the action does not cease immediately when the stimulus is removed or suspended. Thus when a cell starts to grow, it tends to grow continually because of the "physiologic inertia." Abnormal variation in cell growth is characteristic of hypertrophy.

Reproduction.—Cell reproduction is the process by which the number of cells is increased. The ultimate outcome of cell reproduction and cell growth, is to increase the mass or volume. Cell reproduction is not distinct and separable from cell growth, in fact growth always precedes division. Reproduction is one means of regulating the relation of surface to mass. Two types of normal cell reproduction have been described by cytologists. These methods are amitosis, (direct cell division), and mitosis, (indirect cell division.)

1. **DIRECT CELL DIVISION, AMITOSIS,** is simple cell division in which the nucleus and cell body divide without any previous nuclear changes. This type of cell reproduction or division is normal in some lower forms of life and possibly in some embryonic tissues of higher animals. However, it is not very common in normal adult tissues of higher animals. The polynuclear leucocytes occasionally reproduce by amitosis; endothelial cells are also thought to reproduce in the same way. It is possible that cells of any tissue may multiply by amitosis. Cells reproduced by amitotic division are considered abnormal by most investigators. Direct cell division is especially evidenced in rapidly growing tumors, chronic inflammatory areas, leukemic tissue and many other pathologic conditions. The process is briefly as follows: There are one or more depressions in the nucleus which gradually extend until the nucleus is divided into two or more parts, (this is the origin of polynuclear cells; possibly it may also account for the giant cells). After, the nuclelets

has divided, each part migrates to a different part of the cell body and the cell body is so divided that one or more nuclei are found in each segment. Thus the process is completed. In some instances, one or even two centrosomes may be present.

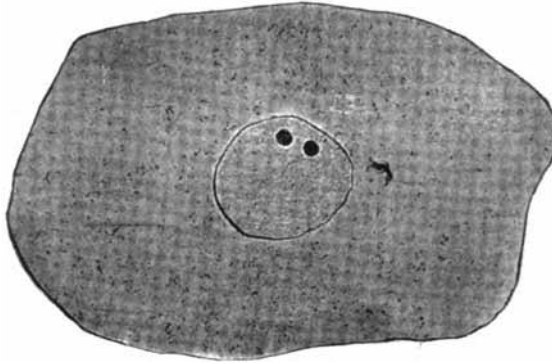


Fig. 2.—Amitosis, showing division of the nucleolus.

4. **INDIRECT CELL DIVISION, MITOSIS, OR KARYOKINESIS,** is the usual mode of cell reproduction. The frequency and intricacy of this complicated process is indicative of the exactness of nature's methods. An equal division of the nucleus, or more specifically




Fig. 3.—Amitosis, showing migration of the nucleoli to opposite poles of the nucleus.

of the nuclear chromatin, is apparently the object of this type of reproduction. It is more delicate and exact than direct cell division. The following four stages are recognized in indirect cell division, but they are not separate and distinct.

A. Prophase. This is the preparatory stage. The nuclear chromatin which, in the resting cell, is an irregularly arranged net-work, becomes a continuous single thread, forming the so-

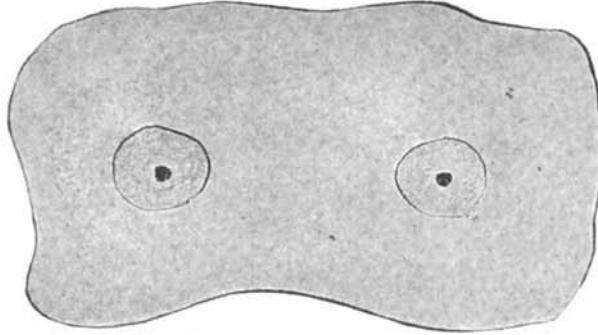


FIG. 4.—Division of nucleus

called spirem or loose skein. The chromatin thread divides into a definite and even number of segments, (the number varying in different animals, but always constant in the same species) known as chromosomes. These chromosomes are equal in length

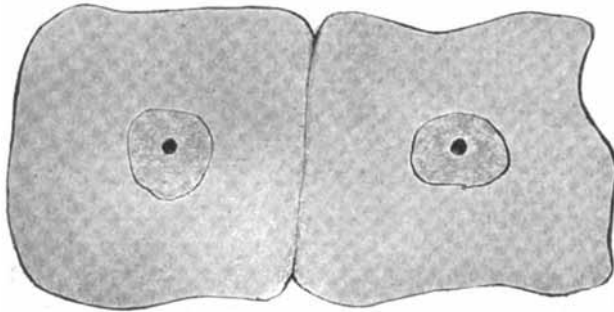


FIG. 5.—Division of cell.

and are usually bent like the letter "u." The chromosomes are radially assembled around the central point in the nucleus, thus forming the monaster or single star. The nuclear membrane becomes less and less distinct as the spirem is forming and finally disappears. As the nuclear changes are progressing, a centrosome becomes prominent either within the nucleus or in the cell body just outside the nuclear membrane. The centro-

some divides, the daughter centrosomes separate and wander to opposite sides of the nucleus. Radiating lines, known as mantle fibres, appear and extend from each centrosome to the chromosomes.

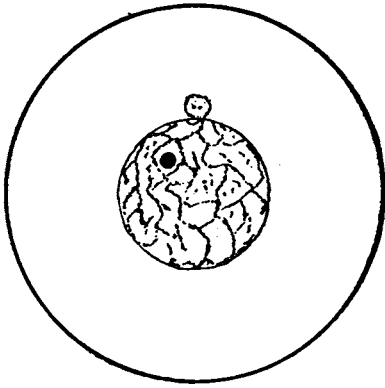


Fig. 6.

Fig. 6.—Cell in resting stage.

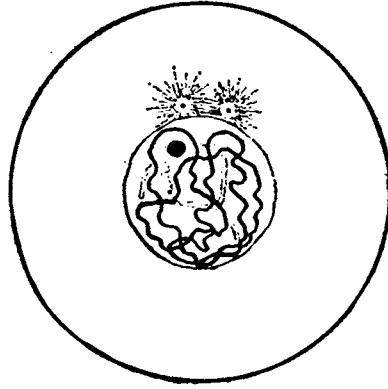


Fig. 7.

Fig. 7.—Prophase showing division of centrosome.

B. Metaphase. During this stage the chromosomes are split or cleaved longitudinally into daughter chromosomes apparently by the traction of the mantle fibres of the centrosomes.

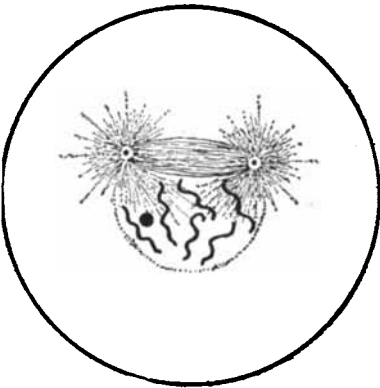


Fig. 8.

Fig. 8.—Prophase showing separation of centrosomes.




Fig. 9.

Fig. 9.—Metaphase.

C. Anaphase. The daughter chromosomes are attracted along the mantle fibres until they reach the centrosomes around which they are ultimately assembled, forming an aster or star at either pole. This particular portion of the anaphase is designated the diaster or double star. There is also evidence of transverse indentation of the cell body near the median line.

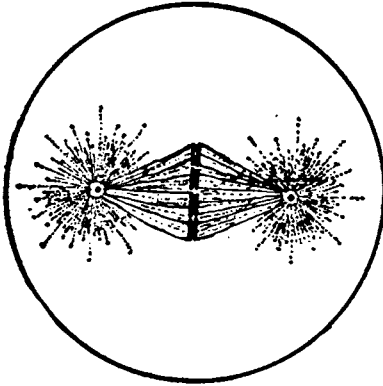


Fig. 10.

Fig. 10.—Metaphase.




Fig. 11.

Fig. 11.—Anaphase.

D. Telophase. The nuclear changes during this phase are practically the reverse of those occurring in the prophase, i. e., the chromosomes fuse forming a chromatin thread which later forms the chromatin network. The nuclear membrane appears and the centrosome loses its mantle fibres and may even entirely disappear. The cell body is completely divided by invagination from the margins, and then the daughter cells are completed and assume the appearance of their ancestors.

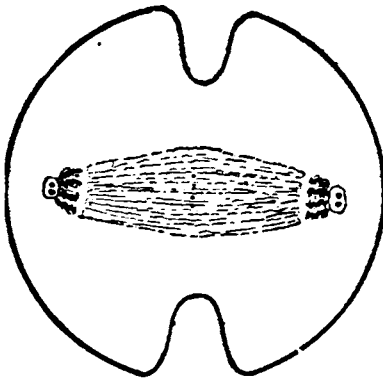


Fig. 12.

Fig. 12.—Anaphase.

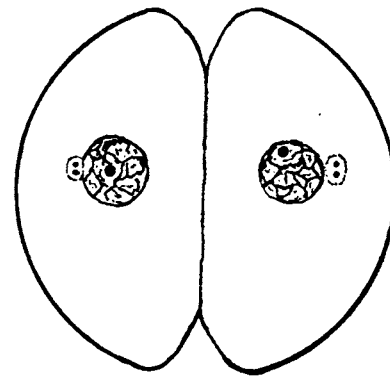


Fig. 13.

Fig. 13.—Telophase.

Morbid cell reproduction is especially evident in neoplasms and in hyperplastic formation. The type of reproduction in neoplasms is variable, being normal or modified, direct or indirect. Indirect division is of most frequent occurrence in hyperplasia, the rapidity of multiplication being the only apparent difference from that occurring in normal reproduction. All variations of division occur in tumors.

Motion.—Motility is that property of a cell which refers either to the intracellular movement of its parts, the position of the cell as a whole remaining fixed, or it signifies the independent movement of the cell. All movement is dependent

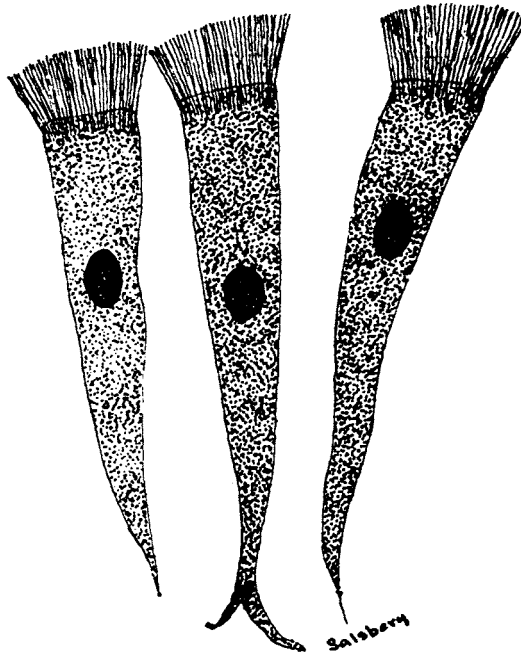
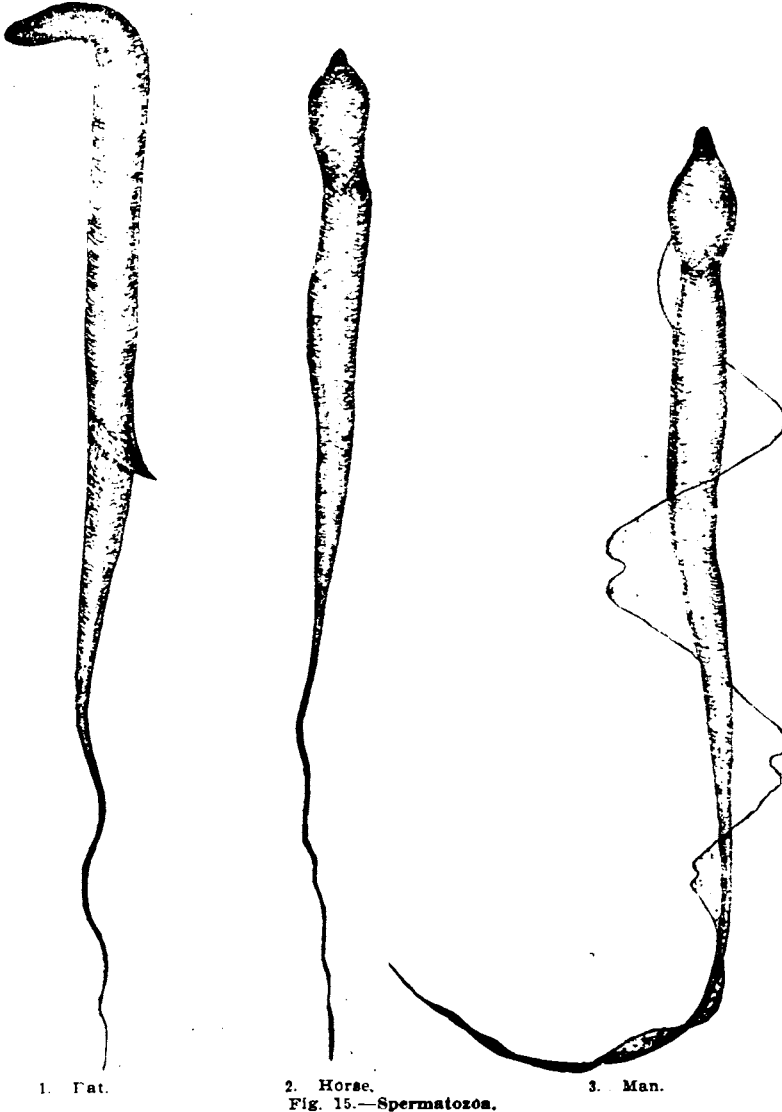


Fig. 14.—Ciliated Epithelium, Trachea.

upon activity of the cell protoplasm. The cells of specialized tissues, except blood, are fixed i. e. not motile.

Intracellular movement is due to the circulation or streaming of the protoplasm from one portion of the cell to another. This type of movement may become so extensive that the shape of the cell will be changed. It is common in the cells of lower forms of life as well as in some of the cells of higher animals. The specific cause of the intracellular protoplasmic circulation has never been positively determined but it is probably the result of a disturbed chemic equilibrium of the cell margins and their

surroundings. Leucocytic amoeboid movement is due to intracellular protoplasmic circulation. Leucocytic immigration probably is the result of chemic attraction, (positive chemotaxis), which stimulates the circulating protoplasm within the cell to constantly flow toward the point of greatest chemical affinity and finally the cell reaches that point. Leucocytic emigration is based upon the same principal except that the chemic in-



fluence is negative, (negative chemotaxis), and the cell is forced away from the center of the disturbed chemic equilibrium.

Ciliary movement is the wave like motion of small hair like protoplasmic projections of cells known as cilia. Ciliary motion occurring in migrating or wandering cells produces movement of the entire cell and in stationary cells, produces movement of fluids or semifluids that contact the cilia. In higher animals motion of entire cells as a result of ciliary movement is observed only in spermatozoa. The normal function of ciliary movement is to aid in propelling mucus in the respiratory tract, ova in the Fallopian tubes, spermatozoa in the vas deferens, etc. Ciliary movement is due to intracellular protoplasmic disturbances, at least it is the result of chemic influences. Over stimulation or disease may produce increased action and finally fatigue or paralysis of the cilia, or they may produce cessation of their action. The most extensive and important cell movement is noted in the highly specialized muscular cell. As the muscle cell maintains its relative position when contraction takes place, the movement is principally evident in the structures to which the muscle fibre is attached. The rate and extent of contraction vary in the different varieties of muscle. The spongioplasm is the active portion of the cell in contraction, the hyaloplasm being passive only in function. Nerve fibres terminate in end-organs, i. e., muscle plates, through which are transmitted impulses that produce muscular contraction. Muscular movement is an indispensable function, as circulation and respiration are absolutely dependent upon it. Digestion and urination would also be suspended if muscular action were curtailed. Immobility may be the result of muscular fatigue or dissociation of motor nerves and muscle fibres, or be due to neuroses. Muscular spasms are usually the result of violent stimulation of the motor nerves, although it may result from excessive stimulation of the muscle fibres themselves.

Metabolism.—Metabolism is a term used to designate the processes included in nutrition or digestion, absorption, assimilation, katabolism, and excretion. These processes are the results of cell action. Metabolism includes two general processes, i. e., constructive metabolism or anabolism and destructive metabolism or katabolism. Active cells are constantly consuming foods and eliminating waste material. The quantity, quality and previous preparation of the nutritive substances required, varies according to the specialization and degree of action of cells. The leucocyte is relatively simple, i. e., it is a primitive type of cell. A leucocyte is not very selective in its food requirements. It

produces ferments that digest food substances, as well as necrotic tissue as inflammatory exudate. The phagocytic action of leucocytes is largely dependent upon the fact that the substances phagocytized have been previously rendered inert. Connective tissue cells are closely related to leucocytes in their power of producing digestive ferments. Endothelial cells produce ferments which aided by the leucocytic ferment, dissolve and devour thrombi and emboli. On the other hand nerve cells are quite selective in their food requirements and they have practically no power of producing digestive ferments.

The foods required by cells are nitrogenous and non-nitrogenous. Nitrogenous nutrients are used in the construction and maintainance of the cell protoplasm. The non-nitrogenous foods are essentially carbohydrates and fats which are consumed when energy, in the form of either heat or motion, is liberated. When non-nitrogenous foods are consumed in excess, some of them may be stored as glycogen in the liver, or as fat in the various parts of the body, thus producing glycogenic or fatty infiltration. The consumption of nitrogenous food in excess may result in overwork of nitrogenous excretory organs as in induced albuminuria. Insufficient supply of carbonaceous food produces disturbed metabolism, because of the necessary conversion of nitrogenous food or nitrogenous cell constituents into carbonaceous substances, in order that the body energy may be maintained. Diminished supply of nitrogenous foods is temporarily compensated for by consumption of the protoplasm of the body cells. If the nitrogenous food supply is materially diminished for a long time or entirely withheld, the body cells atrophy, degenerate, and ultimately die.

The waste products are also divisible into two classes, nitrogenous and non-nitrogenous. The nitrogenous waste substances are urea, or some allied product. They represent katabolic products, i. e., the results of destructive changes in the cell protoplasm. The carbohydrates and fats are almost entirely converted into energy; carbon dioxide and water being the chief katabolic products.

Irritability.—Irritability is the property of certain cells which enables them to respond to stimuli. Stimuli may be chemic, thermic, electric or mechanic. The property of irritability is vested especially in nerve cells, although other cells are slightly irritable, e. g., muscle cells. The degree of sensitiveness varies greatly in different species of animals and to a less extent in different individuals of the same species. Thus the thoroughbred horse has a more sensitive skin than the draft horse. Irritability

is a very important property because it is the means through which the nature of environments is recognized. Many of the activities of the body are responses to impulses resulting from stimulation of irritable cells. Irritability is the property of cells which enables an animal to communicate with its environments as, sight hearing, smell, etc. Irritability may be intensified or diminished by pathological processes. Thus chemic variations, resulting from katabolism in tissues affected with inflammation, produce increased irritability or intensify stimulation of nerves, and is manifested by hyperaesthesia or by pain. Anemic and venous hyperemic tissues are usually less sensitive than normal tissues because of the accumulation of waste product that tend to inhibit impulses or diminish irritability. Correlation of the cell to the entire organ is of considerable moment, and is dependent upon irritability and response to stimuli.

CHAPTER II.

GENERAL CONSIDERATION OF DISEASE.

DEFINITION.

CLASSIFICATION as to,
Time affected.

Inherited.

Definition.

Predisposition.

Tumors.

Neuroses.

Malformations—not rare.

Infections—rarely if ever.

Acquired.

Definition.

Antenatal—(congenital)—Exanthema.

Postnal—Spavin.

Extent in affected animals.

Local—inflammation.

General—anthrax.

ETIOLOGY.

Predisposing.

Heredity—Epilepsy.

Inbreeding—General debility.

Age—Canine and colt distemper, blackleg.

Sex—Males urethral calculi; females, peritonitis.

Genus—Hogs, cholera; cattle, blackleg.

Breed—Clydesdale, laminitis; jersey tuberculosis.

Color—White animals, sunburn.

Location—Pica.

Climate—Contracted hoofs.

Season—Pneumonia, insolation.

Food and Water—Indigestion.

Occupation—City horses, foot disease; dairy cow, udder disease.

Effects of previous disease—Purpura hemorrhagica.

Exciting.

Mechanic—Fractures, dislocations, sprained tendons.

Physic.

Electric—Lightning stroke, electric wires.

Thermic; Burns, overheat, freezing.

Chemic.

Inorganic—Saturnism.

Organic—Sorghum poisoning.

Poisonous plants—Loco, hemlock, larkspur.

Poisons secreted by snakes, bees, etc.

Parasitic.

Bacteria—Glanders, tuberculosis.

Yeast—Epizootic lymphangitis.

Moulds—Pulmonary mycosis.

Protozoa—Tick fever.

Vermes—Trichinosis.

EXTENSION.

Natural channels—Digestive, urinary, etc.

Continuity—Along a muscle, etc.

Contiguity—From muscular to connective tissues, etc.

Blood—In plasma, leucocytes or red cells.

Lymph—In plasma or leucocytes.

Nerve fibres—Alongspaxone.

TERMINATION.

Health has been defined as that condition in which the normal structure and functions of all the component parts of an organized being are maintained.

Disease is a functional or structural deviation from the normal. It is that condition in which an organism cannot accustom itself to its environments. Health and disease are, however, only relative terms, because of the difficulty of determining a normal standard. The two conditions necessarily overlap.

Diseases may be classified in many ways, as local and general, infectious and non-infectious, inherited and acquired, etc.

INHERITED DISEASES are those transmitted from the parent in spermatozoa or ova and are present at the time of fertilization. Certain characteristics are transmitted from parent to offspring such as genus, breed and individual peculiarities. Thus horses have peculiarities so fixed and constant that they are transmitted to their offspring and differentiate them from other species of the genus *Equus*. Breeds are differentiated by certain peculiarities; thus Jersey cattle are brown to light fawn in color with a brown muzzle, horns turned in and up, they are small, lean, dish faced, etc., all of which are peculiarities that distinguish them from other breeds of cattle. There are individual peculiarities, some of which are the result of the fusion of parental characteristics; thus the offspring may be of solid color, the result of the fusion of different parental colors, (color blending), or they may be piebald, indicating failure of color blending (mosaic coloring). The extent of intensification of inherited generic, breed or individual peculiarities depends upon the prepotency of the parental stock. This prepotency depends upon the length of time that the type has existed under similar circumstances. The foregoing illustrates what is meant by the term "heredity", and demonstrates that the breeding of stock is a science.

Diseases are rarely inherited, first, because diseased spermatozoa and ova are probably incapable of fertilization, and second, there is always a tendency to abort when the embryo or foetus is diseased. A predisposition may be inherited, i. e., the progeny of diseased parents may be more susceptible to disease than the progeny of a healthy parentage. Infectious diseases are very rarely inherited. It has been demonstrated that spermatozoa are not phagocytic in action and probably ova have no phagocytic tendencies; the latter, however, has not been proven. The quantity of semen and the number of spermatozoa per given volume varies in different animals and in the same animal under

different conditions. Loeb estimated that the average human seminal ejaculation contained about 226,000,000 spermatozoa. The average seminal ejaculation of a dog probably contains about the same number of spermatozoa as that of the human. Lewis found that one stallion ejaculated 65 cc. of semen during one service, each cmm. of which contained approximately 131,750 spermatozoa; another stallion ejaculated 90 cc. of semen during one service, each cmm. of which contained approximately 225,000 spermatozoa. The quantity and the number of spermatozoa per given volume of semen ejaculated during one service of the bull has not been determined, at least the information has not been found in the available literature. However, it is reasonable to suspect that the number of spermatozoa ejaculated during a single service by the bull is equal to the number ejaculated by a stallion during a single service. It is difficult to collect the entire discharge of semen of a boar, but Lewis obtained 100 cc. from a single service of a boar and by repeated examinations he has determined that the semen from boars contains more spermatozoa per given volume than that from stallions. There would, therefore, be less chance for fertilization with an infected spermatozoon in the horse, ox and hog than in man. Suppose there were 1,000 tubercle bacilli infecting 1,000 spermatozoa that were ejaculated by a bull in one service, then there would be one chance in about 12,000,000 of an infected spermatozoon fertilizing an ovum, assuming that one seminal ejaculation of the bull contains approximately the same number of spermatozoa as one seminal ejaculation of a stallion. The chance is so slight that it need not be considered. The offspring of animals affected with some infectious diseases are more susceptible to those diseases. For example, calves of tuberculous parentage are more susceptible to tuberculosis than calves of non-tuberculosis animals.

Neoplasms or tumors are occasionally inherited or at least there is an inherited predisposition to them. Dr. A. F. Meredith of Lincoln, Kansas, submitted a tumorous growth for examination that was obtained from the left eye of a mule. The dam of the mule, as well as four of her brothers and sisters had a similar defect of the same eye. Cadiot refers to a family of dogs in which there were carcinomata of the mammae for two successive generations.

Malformations, though usually of congenital origin, are probably more frequently inherited than is any other type of disease. Thus a cryptorchid stallion was used for breeding purposes in a certain locality in Illinois and about 20%

of his male colts were cryptorchids. About 5% of the male progeny of one of Missouri's most famous boars, Chief Tecumseh II, were cryptorchids. Liberty Chief and Chief I Know, two boars sired by Chief Tecumseh II, were noted boars and from 3 to 5% of their male get were cryptorchids. Chief Perfection II, also sired by Chief Tecumseh II, was the sire of Cherokee Perfection which in turn sired about 3% of cryptorchids. Thus this structural defect appeared in at least three generations. A female Belgian hare having one ear, produced a large number of young of which more than 50% had only one ear.

Epileptic domestic animals and those affected with other nervous disorders are usually destroyed or at least are not bred, hence the statistics of inherited nervous diseases in domestic animals are very meagre, but there is little doubt that such diseases, or at least a predisposition to them, is inherited. La Notte recorded hereditary epilepsy in the progeny of two epileptic bulls, the disease becoming evident in the females after they had given birth to their first calves, and in bulls soon after they were put into service.

Some other diseases are inherited, thus; periodic ophthalmia has, in many instances, occurred in, and affected practically an entire family of horses. There is a predisposition to spavins, splints and ringbones in certain strains of horses. This is due to inheritance of structural or conformation defects.

ACQUIRED DISEASES.

The life of mammals is conventionally divided into two periods, the ante-natal or intrauterine, and the post-natal or extrauterine. Acquired diseases are those contracted after fertilization and hence may be ante-natal, (congenital) or post-natal.

Ante-natal or Congenital diseases are those contracted between the time of fertilization and birth. Some infectious diseases are congenital, for instance, marked lesions of tuberculosis were found by the writer in 1900 in a three day old calf, and two authentic reports of similar cases have been received since that date. (These cases were not considered as inherited for the reason heretofore given, and in all three cases lesions of tuberculosis were found in the uterus and adjacent tissues of the cows.) Infectious diseases are seldom transmitted from the mother to the foetus because of the relation and anatomical structure of the placental membranes. The female is usually either sterile or aborts if the uterus or the accessory parts are diseased, while the male is not likely to be productive if the genital organs are diseased. Exanthematous diseases are frequently congenital.

Teratomata and other malformations are diseased conditions and are usually of congenital origin.

Post-natal diseases are those contracted at any time during the life of the animal after birth, as laminitis, actinomycosis, and spavin.

In classifying diseases according to extent, two groups are usually described, viz:—, local and general.

1. A LOCAL disease is one that affects a part or organ; as urethral calculi, pulmonary anthracosis, etc. Local diseases proper remain localized although the term is used in a broader sense to designate a circumscribed, local, morbid process that may later become generalized. Thus; tubercular infection of a group of lymphatic glands is frequently spoken of as localized tuberculosis.

2. A GENERAL disease, strictly speaking, is one invoking the entire animal body, as anemia, but in a more restricted sense it is used to designate the involvement of several parts or organs.

Etiology.—Disease has been defined as an inharmonious relation between an individual and its environments. This definition is indicative of the various factors concerned in the production of morbid processes. The causes of disease may be conveniently subdivided into two groups, viz.: predisposing causes and exciting causes.

PREDISPOSING CAUSES.—Predisposing causes are those conditions or environments which render animals more susceptible to disease.

It has long been recognized that many diseases of domestic animals are due to induced variations of species that result from selection by breeders. New breeds of the various animals are produced so rapidly, that the individuals of the new breeds are more susceptible to disease.

Retrogressive changes in anatomical structures predispose to disease. The tarsal joint of the horse is gradually changing from an active to a passive structure; this change results in a tendency to ossification and ankylosis or spavin formation. Progressive changes in various structures are responsible for some diseased conditions, viz., navicular disease in the horse, or dairy breeds having large udders, are more susceptible to mammary diseases. Several breeds of horses are characterized by small heads and especially diminished facial bones, a conformation that predisposes to dental diseases.

Inbreeding has been a cause of decreasing the resistance of animals to disease.

Age. The age of animals is an important predisposing factor

in the causation of disease. The very young animal is structurally more delicate than the matured animal. Tissues are more or less permeable to the various bacteria, and until the young acquire an immunity, i. e., establish a resistance, they are more or less influenced by bacterial activity in their tissues. There are some diseases, however, that affect **only** young animals, as, canine and colt distemper, while other diseases occur primarily or only in adults as carcinomata and bursattae.

Sex is of consequence in the occurrence of disease. Parturition predisposes females to disease. Males are especially susceptible to urethral calculi.

Genus may be a characteristic factor in the predisposition to disease. Glanders is a disease of the genus equus, caseous-lymphadenitis of the genus ovis, canine distemper of the genus canis, rinderpest of the genus bovis.

Breed.—There are certain peculiarities of different breeds of animals that are inducive to disease, thus the original Clydesdale horse is not resistant to laminitis; the thoroughbred having a nervous temperament is more susceptible to heart disturbances; the jersey cow with a diminished breathing capacity is more liable to pulmonary tuberculosis.

White or light colored animals are more susceptible to dermatitis and are more affected by flies than those of darker color. In certain locations there are no white hogs because the hogs in those locations feed upon the roots of *Lacuanthis tinctoria*, which causes a pink discoloration, (hyperemia), of their bones and causes sloughing of the feet in all except black hogs.

Individuals of a resistant strain are sometimes especially susceptible to certain diseases.

Location.—The soil of a locality may be deficient in some necessary ingredient or contain some noxious constituent. Some localities may be continually damp and muddy, others dry and dusty, and still others abound in objectionable gases and odors. Any of the above conditions naturally diminish the resistance of animals; thus pica exists in localities in which the soil is probably deficient in some ingredient, scratches and thrush are common where mud abounds; broken and cracked feet in dry dusty regions, and nasal catarrh where irritating odors are common.

Climate definitely influences the hairy covering of animals. In Angora, not only goats but also collie dogs and cats have fine fleecy hair. Mules kept in mines constantly for a long time become covered with velvety hair like that of a mole.

Season.—Some diseases are more common in certain seasons.

Thus pneumonia is more prevalent during the seasons of sudden change as early spring and late fall.

Occupation.—The city express horse is particularly liable to diseases of the feet, the thoroughbred to rupture of the heart or blood-vessels, the dairy cow to udder diseases, the house dog to indigestion, etc.

Food and Water.—Excessive, insufficient or unwholesome food and water, also irregularity of feeding or watering are frequent causes of depressed condition of animals. In Holstein an enzootic anemia destroys hundreds of suckling pigs annually. The pigs are apparently normal until about two weeks of age. The cause is probably improper food and a predisposition resulting from excessive stimulation of the reproductive function of the sow. Variegated color of parrots is produced by feeding green parrots fat from siluroid fishes. Colic is essentially a dietary disease.

The effects of previous disease frequently leaves an animal in a depleted condition, thus petechial fever is frequently a sequel of pneumonia or "stable fever" (catarrhal fever).

Overwork, lack of exercise, variable temperatures, and other minor causes all have their influence in depressing the animal body.

Imitation.—Some animals, colts especially, have a tendency to imitate what other horses do, thus colts allowed to run with cribbing horses occasionally become cribbers.

EXCITING CAUSES of disease are those acts or agencies which directly and specifically produce disease as falling, sunlight, chemic substances and infection.

Mechanic, physic. chemic and parasitic agencies are the principal exciting causes of disease.

Mechanic.—Diseases are produced mechanically by breaking the continuity of involved tissues, by compression, or by changing the relations of anatomical elements. The condition resulting from a break in the continuity of a surface soft tissue is termed a wound, of sub-surface soft tissue, a rupture and of osseous tissue, a fracture. Compression may cause bruising or crushing depending upon the mechanical object inducing the injury, and the amount of pressure exerted. Luxations or dislocations are the result of changed relations of bones, tendons and ligaments. Volvuli and intussusceptions are the result of changed relations of the intestine. Hernia is a condition in which there is a changed relation, caused by a break in the continuity of one tissue which permits an adjacent tissue or structure to protrude or sacculate through it.

Dogs are more frequently injured by biting than other animals although they may inflict lacerated wounds in other animals especially hogs. Horses more frequently than other animals become injured by pawing, rearing, kicking, falling and colliding with foreign objects. The majority of barbwire wounds are the result of pawing over or through a wire fence. Rearing frequently results in straining the calcaneo-cuboid ligament thus producing a curb. Slipping may cause the straining of tendons, thus producing curbs and spavins as well as tendonitis. Falling may produce strained tendons and is the usual cause of dislocations, rupture, hernia, volvulus and fractures. Runaway horses and mules frequently collide with fences, trees, buildings, and various vehicles, as buggies, wagons, street cars, etc., and thus produce a variety of injuries.

Ill-fitting shoes are responsible for contracted feet, strained tendons and ligaments, speedy cuts and bruises by interfering. Illfitting collars produce galled shoulders, sore neck, cerebral venous congestion and sweeney. Illfitting harness produces sweeney, sore neck, sore back, galled sides, rump and tail, an illfitting bridle causes irritation of the mouth, injuries to the eyes, the ears and the throat-latch region, and poll evil. Excepting the sore mouth, illfitting halters produce the same results as illfitting bridles. Illfitting saddles produce sore backs, sitfasts, injury in the region of girth and bruises resulting in fistulous withers.

Attendants may inflict injuries of various types. Several cows in a dairy recently observed, were all lame in the right hind leg. Upon closer inspection the right tarsal joint was found enlarged and sensitive. One man had been milking all the affected cows and finally admitted that he had either kicked or struck each lame cow upon the tarsal joint.

Bandages are frequently so tightly wound upon a part that they obstruct circulation thus producing venous congestion, which predisposes to infection. Some cases have been observed in which splints improperly applied to support a part have resulted in venous congestion, oedema and necrosis. Careless individuals will place rubber bands upon dogs' tails, ears, and feet to see the animals remove them. The dog will sometimes fail to remove the rubber band, which, by pressure, may divide the skin and soft tissues, and finally cause the portion distal to the band to become necrotic and slough.

Shooting occasionally causes mechanical injury to animals in pastures, especially during the hunting season. This is more frequently the source of injury during a war, and a knowledge

of the various types of bullets and wounds inflicted by same is of considerable importance to army veterinarians.

Powdered glass, which is sometimes maliciously incorporated in food for the purpose of destruction of life, may excite gastric and intestinal inflammation. Sand is sometimes consumed in sufficient quantities, by animals, grazing upon sandy soil, to mechanically interfere with digestive functions, and mechanically injure the gastric and intestinal membrane. Nails, wire, staples, etc., are frequently ingested with food by animals, especially cattle, which objects may abraid and cause injury by producing abrasions of the mucous membrane or even by puncturing the wall of the digestive tract, thus establishing such inflammatory disturbances as peritonitis, pleurisy, pericarditis, etc.

Various mechanical contrivances such as operating tables, throwing harness and hobbles, used in subduing fractious animals or confining animals for operative procedure may produce injury.

1. Physic.—Temperature variations, not only predispose to disease, but may also become an exciting cause. Excessively high temperature is likely to produce overheat, (insolation, heat prostration). Overheat or heat prostration is frequently observed in fat hogs having little or no shelter in the summer time, or in hogs being hauled in wagons or cars, or being driven in herds to market. It is also frequently observed in horses worked on pavements in cities during the summer months.

Local application of excessive heat produces burns. The lesions produced in local burns, vary according to the degree of temperature, the length of time applied and the tissue resistance. Three grades of lesions, of local burns, determined by the degree of temperature, may be described. First, short exposure to a temperature of from 50° to 60° C. produces an hyperemia or a burn of the first degree; second, exposure to a temperature of 60° to 80° C. for a short time produces inflammation, characterized by a serous exudate that accumulates in the malpighian layers of the epidermis forming vesicles or blisters; third, an exposure to a temperature above 80° C. for a brief period, produces necrosis, the dead tissue becoming dry and hard. Burns involving one-fourth to one-third of the cutaneous surface frequently terminate fatally as a result of excessive heat, hemolysis of the red corpuscles, increased heat dissipation and other disturbed cutaneous functions.

Excessively low temperature may diminish the body temperature, of warm blooded animals, to the extent that the functioning is modified or inhibited sufficiently to result in death.

Animals are naturally protected from the effects of low temperatures, in dry weather, by their coat of hair, fur, wool or leathers. When their protective coat becomes wet it no longer prevents heat dissipation consequently animals having no shelter, as ranch horses, cattle, and sheep, frequently die in great numbers during the early cold spring rains.

The local lesions caused by low temperature are practically the same as those resulting from exposure to high temperature. Thus exposure to a mild, low temperature produces hyperemia; exposure to freezing temperature produces inflammation accompanied by a serous exudation but the exudate rarely accumulates and forms a vesicle as in burning. Exposure to extreme low temperature produces necrosis, the frozen tissue becoming dry and hard.

Animals are most frequently exposed to temperatures sufficiently high to produce insolation in the daytime, in the tropical or temperate zones, although overheat is sometimes observed during the night. Exposure to temperatures that produce local burning usually occurs in conflagrations of buildings. Scores of animals die, in the spring, on ranges or large pastures, in the temperate zone, as a result of diminished body temperature induced by exposure to cold rains. These animals are usually depleted because of insufficient or non-nutritious food. Their coat of hair or wool becomes saturated with water and thus the body temperature regulation is disturbed. Lesions produced by low temperatures are evident only in regions and seasons, where there is a low atmospheric temperature. Local freezing usually occurs in extremities as the ears, tail and feet.

2. Photic.—Exposure to sunlight frequently produces dermatitis, especially in those animals having a thin, light colored skin. White hogs are quite seriously affected by sunburning, in some localities. This peculiarity prohibits the raising of white hogs, in certain districts in Africa and Central America. R. Paine, F. R. C. V. S., of the Department of Agriculture of Cape Colony, in the *Journal of Comparative Pathology and Therapeutics*, Part 1, Vol. XXI, reported some cases of dermatitis in cattle, that were undoubtedly the result of exposure to sunlight. D. M. Campbell observed about 40 Duroc Jersey pigs affected with dermatitis induced by sunlight.

Direct or reflected sunlight is also injurious to the eyes of domestic animals. The injurious effects are noticed more especially in animals driven upon macadam thoroughfares or over light colored soil. Electric and gas lights have also been found to be injurious to the eyes of various animals especially

when the lights are allowed to shine directly into their eyes. Epilepsy has been produced in horses by sudden exposure to intense light.

The immediate cause of the effects of exposure to sunlight upon the skin is not known but is thought to be the result of the action of the actinic or chemic rays. The effects of exposure to light upon the eyes is excessive stimulation which produces exhaustion thus predisposing to, if not directly exciting disease.

3. Electric.—Animals are susceptible to the action of electricity. Horses are especially susceptible to its influences, a direct current of 500 volts, 100 amperes, is sufficient to kill a horse, and an alternating current of 160 volts is destructive to medium sized dogs.

Contact with electricity may be the result of lightning, and charged electric wires, or rails. Horses and cattle frequently are struck by lightning while in pastures, and animals used in cities are occasionally accidentally brought in contact with electric currents. Depending upon the amount of electrical current, the results may be a slight singeing of hair, burning, or laceration of tissues in general. Carcasses of animals destroyed by electrical currents have also been observed in which no lesions could be found. On examination of carcasses of animals dead of lightning stroke, there is usually more or less singeing of the hair, hyperemia and hemorrhages along the course of the current.

Chemic.—Chemic substances capable of producing disease are very common and may have their origin from the mineral, vegetable or animal kingdom, and are inorganic or organic. It is probable that practically all chemic substances may, under certain conditions, be injurious to the tissues of the various animals. Some chemicals are always injurious, others may become injurious by chemic change induced by the tissue juices. Those chemicals capable of producing deleterious effects in the animal tissues are poisons. (Poisons are substances which when taken internally or applied externally alter health or destroy life without acting mechanically or reproducing themselves.)

According to their modes of action, poisons have been classified as follows: 1. Corrosive poisons, (caustics and irritants.)

The action of this group varies from the production of a simple hyperemia to necrosis. The most common agents are mercury, arsenic, sodium and potassium hydroxide and the mineral acids.

2. Parenchymatous poisons. This group produces tissue

BOTANICAL NAME.

Common Name.	ORDER OR FAMILY	GENUS	SPECIE
Ergot	Hypocracaea	Claviceps	purpura
Stink Horn	Phallaceae	Uathrus	columnnatus
Bunch Flower	Melanthaceae	Chrosperma	muscaetoxicum
White Hellebore	Malanthaceae	Vevatrum	viride
Calif. Hellebore	Malanthaceae	Vevatrum	californicum
Pokeroot	Phytolaccaceae	Phytolacca	americana
Corn cockle	Caryophyllacea	Agrostemma	githago
Monkshood	Ranunculaceae	Aconitum	napellus
Wild Monkshood	Ranunculaceae	Aconitum	columbianum
Wild Monkshood	Ranunculaceae	Aconitum	uncinatum
Larkspur (dwarf)	Ranunculaceae	Delphinium	tricornis
Larkspur (purple)	Ranunculaceae	Delphinium	mensiesii
Larkspur (Wyoming)	Ranunculaceae	Delphinium	geyeri
Larkspur (tall)	Ranunculaceae	Delphinium	glaucum
Mayapple	Berberidaceae	Podophyllum	peltatum
Wild blackberry	Prunaceae	Prunus	serotina
Woolly loco	Leguminosae	Astragalus	mollissimus
Stemless loco	Leguminosae	Aragallias (Oxytropis)	lamberti
Rattlebox	Leguminosae	Crotalaric	sagittalis
Wild or blue pea	Leguminosae	Lupinus	leucophyllus
Wild or blue pea	Leguminosae	Lupinus	argentus
Alsike clover	Leguminosae	—	—
Red Buckeye	Aesculaceae	Aesculus	pavia
Horse chestnut	Aesculaceae	Aesculus	hippocastanum
Ohio Buckeye	Aesculaceae	Aesculus	glabra
Calif. Buckeye	Aesculaceae	Aesculus	california
Water Hemlock	Umbelliferae	Cicuta	maculata
Oregon Water Hemlock	Umbelliferae	Cicuta	vagans
Poison Hemlock	Umbelliferae	Conium	maculata
Broad leaved laurel	Ericaceae	Kalmia	latifolia
Narrow leaved laurel	Ericaceae	Kalmia	angustifolia
Great laurel	Ericaceae	Rhododendron	maximum
Black nightshade	Solanaceae	Solanum	nigrum
Spreading nightshade	Solanaceae	Solanum	nigrum
Horse Nettle	Solanaceae	Solanum	triflorum
Jimson weed	Solanaceae	Datura	carolinense
Tobacco	Solanaceae	Nicotiana	stramonium
Potato	Solanaceae	Solanum	tobacum
Cocklebur	Compositae	Xanthium	tuberosum
Cocklebur	Compositae	Xanthium	canadense
Sneezeweed	Compositae	Helenium	glabratum
Death Canas	Melanthaceae	Zygadenus	venenosus
Sorghum	Gramineae	Andropogon (Hack)	Sorghum
Kaffir corn	Gramineae	Andropogon	Sorghum
Castor bean	Euphorbiaceae	Ricinus	communis

INSERT I.

PART OF PLANT POISONOUS	POISONOUS PRINCIPLE	ANIMALS AFFECTED	LOCATION OR DISTRIBUTION
entire	Ergotine	all	Universal
entire	—	Hogs especially	Southern States
bulbs	—	cattle especially	Eastern U. S.
leaves	Veratrine	all	Eastern and Northern U. S.
leaves and seed	Veratrine	all chickens (seed)	California
root	Phytolaccine	sheep	Eastern 2/3 of U. S.
entire seeds especially	—	all chickens especially	Eastern 2/3 of U. S.
roots and leaves	Aconitine	all	Universal garden plant
roots and leaves	Aconitine	all	N. W. America.
roots and leaves	Aconitine	all	North Central U. S., Ga., Pa.
seeds and leaves	—	cattle and sheep	Ohio, Ind., Pa., Ky., N. C., Ga., Ark.
seeds and leaves	—	cattle and sheep	N. W. U. S. and S. W. Can.
seeds and leaves	—	cattle and sheep	Wyoming and N. Colo.
seeds and leaves	—	cattle and sheep	N. W. U. S.
leaves	Podophyllin (Berberine)	cattle	Que., Fla., Tex.
leaves	Hydrocyanic acid	cattle	Middle Atlantic States, Dak., Kans., Tex.
leaves and stem	Barium Chloride	Cattle, Horses and sheep	Plains U. S., Mex. and Can.
leaves and stem	Barium Chloride	Cattle	Plains U. S. Mex. and Can.
leaves and seeds	Unnamed alkaloid	Cattle and Horses	N. Car., Fla., S. Dak., Ark., Mex. Western U. S. especially Mo. river valley.
pods and seeds	Lupinin	sheep	Uplands and foothills.
pods and seeds	Lupinin	sheep	Central U. S. uplands and foothills.
—	—	horses	Central U. S. uplands and foothills.
leaves and fruit	Aesculin	all	Gulf and middle states, Va. to Fla.
leaves and fruit	Aesculin	all	N. Eng., N. Y., N. J.
leaves and fruit	Aesculin	all	Ohio, Pa., Ala., Mich., Okla., Neb.
leaves and fruit	Aesculin	all	California.
roots	Conine	all sheep and cattle	Eastern and Gulf States, N. Mex.
roots	Conine	all sheep and cattle	N. W. U. S.
roots	Conine	all	N. E. U. S. and California.
leaves	Andromedotoxin	cattle and sheep	Allegheny district, Fla., La.
leaves	Andromedotoxin	cattle and sheep	N. E. U. S. Ga., Mich., Hud. Bay, New Found.
eaves	Andromedotoxin	cattle and sheep	Allegheny Mts., Nova Scotia, Ont.
eaves, roots and fruit	Atropine	all	Universal
eaves and fruit	Atropine	all	Ont. N. W. Ter., Kans., Ariz.
eaves and fruit	Atropine	all	Central U. S. also Eastern U. S.
eaves and fruit	Atropine	all	Universal
eaves and fruit	Nicotine	all	Universal
uber	Solanin	horses and sheep	Universal
otyledons	—	sheep	Universal
—	—	pigs, cattle and sheep	Universal
eed	—	pigs	Georgia, N. Eng., Fla., Neb., Mex.
ntire plant	—	horses, cattle and sheep	Universal
ulbs and leaves	—	sheep and cattle	Western U. S.
eaves	Hydrocyanic acid	cattle	Plains especially.
eaves	Hydrocyanic acid	cattle	Plains especially.
eed	Ricin	all	Universal

degeneration, especially parenchymatous and fatty degenerations. The most common parenchymatous poisons are the toxins, endo-toxins, ptomaines, leucomains, phosphorous and silver.

3. Hemic poisons. These act principally upon the red blood corpuscles and may inhibit combination of hemoglobin and oxygen, and cause disintegration of the cells and even produce thrombosis. The principal agents that combine with hemoglobin and thereby produce disintegration of the red cells, are carbon monoxide, sulphuretted hydrogen, hydrocyanic acid, the chlorates, and mercury.

4. Nerve and Cardiac Poisons. These may produce paralysis by over-stimulation of nerve centers, or they may produce variation in the rate and force of the heart beat. Narcotics, such as atropine and solanin are types of neurotoxic poisons. Potassium salts depress the rate and increase the force of the heart action.

A poisonous drug may act in a variety of ways depending upon the form of the drug, size of dose and method of administration.

The following are the more common inorganic poisons:—arsenic, mercury, sodium, potassium, lead, copper, chlorine, and the various oxides, salts, acids and bases formed from them.

Many organic compounds are responsible for poisoning in animals as phenol, iodoform, picric acid, hydrocyanic acid. In fact most of the medicinal organic compounds are poisonous in large doses.

There are many plants that are responsible for extensive losses of live stock in all parts of the United States, Canada and Mexico, and are most extensive in range districts. Colorado and Montana have had losses aggregating \$200,000.00 annually, in live stock, from plant poisoning. The following table gives the common and botanical names of plants that most frequently produce poisoning in animals. (See insert No. 1.)

These plants are not all poisonous during their entire development. The cocklebur is most poisonous in the earlier stage of development, that is, at the time the cotyledons come through the soil and for two or three days after the plant is up. Lupines are harmful principally while the seeds are maturing. Larkspurs are harmful only until the flowers appear. Dry seasons are usually most favorable to the formation of poisonous principles in plants. Ergot develops most extensively during the wet seasons. Second growth or stunted kaffir corn and

sorghum plants are more likely to be injurious than first growth or well developed plants.

Poisonous plants usually have some noxious properties as odor, taste, or appearance that protects them from consumption by animals. Poisoning usually occurs in animals that are hungry or are not accustomed to the location, or at least are not familiar with the plants that abound there. Animals in districts where poisonous plants are found are usually familiar with the disagreeable properties of them and let them alone or




Fig. 16.—Red Buckeye (*Aesculus Pavia*).

the animals may become accustomed to the injurious principles of the plant, that is, develop a tolerance similar to immunity to infective diseases.

In their vital activities microphytes (bacteria, yeast and moulds) and microzoa (protozoa) produce clemic substances that are extremely poisonous to animals. Thus saphrophytic bacteria produce ptomains in putrefying flesh. Fermented, musty or mouldy hay contains injurious substances that produce indigestion in the horse and ox. The specific products of micropara-

sites will be discussed under the topic of vital or infective causes of disease.

Bees, wasps, scorpions, ants and other animal organisms liberate poisonous chemic substances (zootoxins) which, when introduced into the animal body cause marked disturbances.

Poisonous snakes secrete and liberate injurious chemic sub-




Fig. 17.—Loco (*Astragalus Mollissimus*).

stances. The poisonous principle, zootoxin or venom is produced by glandular tissue, and is liberated through canals or grooves in their fangs. The exact chemic composition of venom has not been determined but is not the same in the different venomous snakes. Noguchi has classified the principle action of venom as follows:—

1. Instantaneous production of thrombi. *Crotalus* (rattlesnake).
2. Neurotoxic action. (Cobra.)
3. Produce capillary ruptures and hemorrhage. *Crotalus* (rattlesnake).
4. Produce hemolysis. *Crotalus* (rattlesnake).
5. Produce general cytolysis. *Crotalus* (rattlesnake).
and viper berus (adder).

The following is the toxicity estimate of venom per kilogram body weight:—

- Cobra venom .00009 gram lethal dose for horse intravenously.
- Cobra venom .0005 gram lethal dose for dog subcutaneously.
- Rattlesnake .005 gram lethal dose for rabbit subcutaneously.
- Viper .0001 gram lethal dose for rabbit intravenously.

Retrograde metamorphosis in the tissues of the animal body frequently results in the production of leucomains which when absorbed are extremely poisonous and cause marked disturbances. Over action of muscular tissue may cause the production of leucomains, thus horses that are overworked, although their food and water are first-class and their digestion is good, are occasionally affected with a severe diarrhoea caused by the action of leucomains.

Parasitic or Infectious. During the last quarter of a century pathology has received an impulse by the knowledge of microparasites acquired during this time. Although parasitism has been known since the dawn of the 19th century the importance of microparasites has been recognized only since bacteriology became a science.

Parasitism is an evolutionary condition. It is the result of a long continued struggle, and the survival of the fittest, during which there is a necessary adaptation to constantly changing environmental conditions. Parasitic causes of disease include representatives of both the plant and animal kingdom. Parasitic plants (Phytoparasites) are practically all microscopic in size and are termed microphytes. Pathogenic plants are all fungi and the following scheme gives their position in the plant kingdom:

VEGETABLE PARASITES.

KINGDOM	BRANCH	CLASS	ORDER	FAMILY	GENUS	SPECIES
1. Plant	Thallophyta	Hyphomycetes	Mucidinae	Oospora (Asporion schweibinii)	Porriginæ
2. Plant	Thallophyta	Hyphomycetes	Pleocaulaceae	Aspergillaceae	Aspergillus	Fumigatus
3. Plant	Thallophyta	Hyphomycetes	Pleocaulaceae	Aspergillaceae	Aspergillus	Niger
4. Plant	Thallophyta	Ascomycetes	Protoascinae	Baccharomycetaceae	Baccharomyces	Farcininosus
5. Plant	Thallophyta	Schizomycetes	Actinomyces	Bovis
6. Plant	Thallophyta	Schizomycetes	Bacterium	Tuberculosis, etc

Hyphomycetes (Moulds).

Hyphomycetes or moulds are non-chlorophyllic plants. Structurally they are composed of mycelial threads from which upright reproductive organs may be formed. They are usually multicellular and reproduce by spores. They require preformed foods and thrive best in the absence of light.

Oospora porrigines (Achorion Schoenleini) is the organism that causes favus. These organisms have mycelia with hyphae, the latter may be branched and terminate in bulbous ends. The mycelium is later converted into oval spore-like bodies. Favus is occasionally observed in dogs and cats, more rarely in horses and fowls. The disease is characterized by dry scales which are brown, yellow or even white upon the surface and vary from white to sulphur yellow in their deeper layers. The areas involved are usually not more than $\frac{1}{2}$ or $\frac{3}{4}$ inch in diameter, and are usually devoid of hair. The lesion may occur on the head, especially on the forehead, cheeks or ears, and on the abdomen, or outer surface of the hind legs.

Sporotrichium Audouini (Trichophyton Tonsurans) is the fungus that causes ring-worm (tinea tonsurans). This fungus is

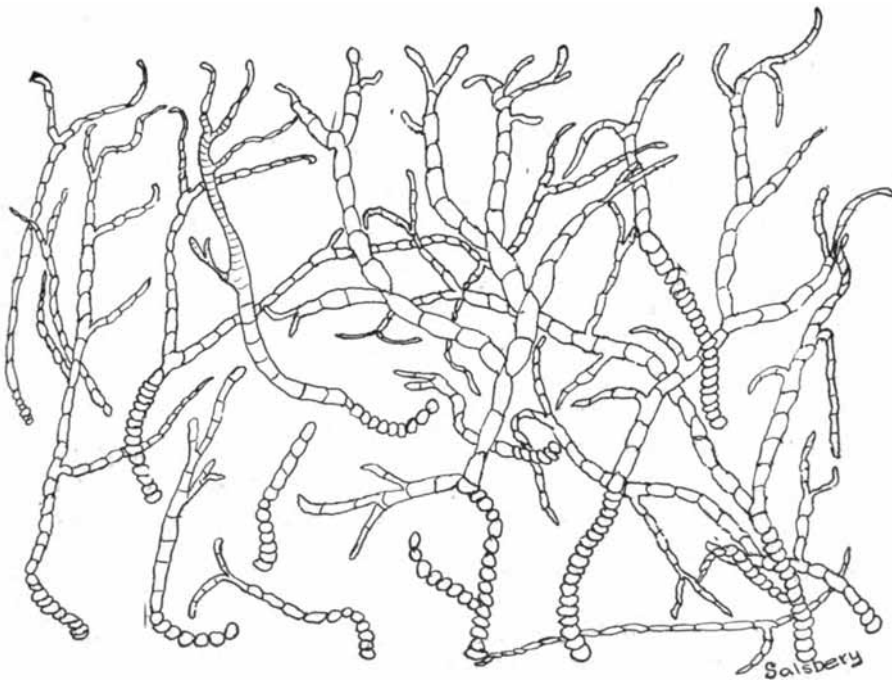


Fig. 18.—*Trichophyton Tonsurans*, showing mycelium and spore like bodies.

found in the lesion and is probably strictly parasitic. Structurally it is composed of a simple or branched mycelium which may become broken up as a thread of ovoid spores. The spores may also appear in groups in the hair follicles. The disease becomes evident because of the presence of small circular hairless patches which are covered by grayish crusts or scales. As the disease progresses the central portion of the lesion becomes normal and the peripheral tissue becomes involved. This condition has been observed in the horse and ox; other domestic animals rarely become affected.

Aspergillus Fumigatus is responsible for an occasional outbreak of pulmonary mycosis (Pneumo-mycosis Aspergillois) in birds. This fungus is of common occurrence in nature. Structurally the fungus consists of a segmented mycelium

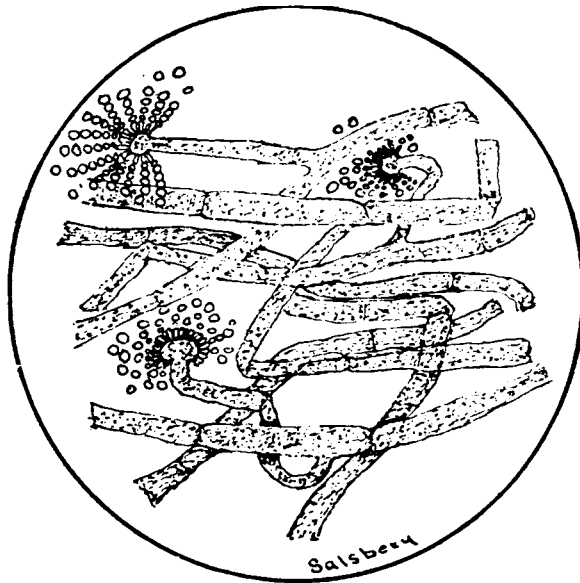


Fig. 19.—*Aspergillus Fumigatus*.

which may branch dichotomously and from which upright stems termed hyphae may originate. These hyphae may be segmented and terminate in club-like heads. A tuft of hair-like projections (sterigmata) develops from the hypha head and on the distal end of each hair there is a spore bearing organ (conidium). The entire hypha head with its spore bearing organs is included in a capsule the rupture of which is necessary for the distribution of the spores. The spores of *Aspergillus* are present in large numbers in hay, straw, barn-yard

manure, etc., and they maintain their vitality in the dormant state for a considerable length of time.

The source of infection is contaminated food, water or air.

The principal lesions are located in the trachea, bronchi, lung and air cells of bones. The disease is characterized by a fibrinopurulent inflammation of the mucous membranes of the trachea and bronchi and abscess formation in the lung.

Aspergillus Niger is probably responsible for the cause of some cases of ear canker in dogs.

Saccharomyces. (Yeast)..

Saccharomyces are the budding fungi. The classification of this group, the yeast plants, is as yet incomplete, their general biologic characteristics not being well known. A few varieties,

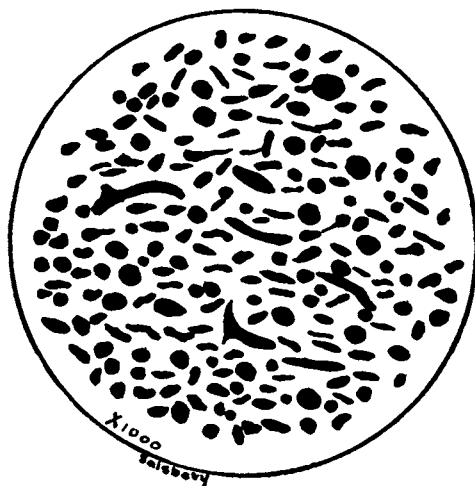


Fig. 20.—Yeast (*Saccharomyces Farciminosus*).

however, have been studied, one of which, *Saccharomyces Cerevisiae*, is of considerable economic importance to the brewers.

Yeasts are ovoid or spherical single celled non-chlorophyllic plants that reproduce by budding. Structurally the yeast cell has a cell body composed of protoplasm and a double cell membrane the latter composed of condensed protoplasm. The cell body may contain vacuoles, granules or foreign substances. Reproduction, which is by budding or gemmation, occurs at one or both ends of the yeast cell and even in some cases from the side of the cell. Budding begins by the appearance of small tubercles or buds which develop until a considerable size is attained. The daughter cell may remain associated with the

mother cell or it may become detached and then pass through a similar cycle. Under certain conditions the yeast plant may develop into filamentous threads and in other instances may produce spores.

Saccharomyces was, for a considerable time, associated as an etiologic factor in the production of carcinoma. It is probable that the "carcinoma bodies" (dense refractile oval bodies) are yeast cells but it is quite evident that they have no etiologic significance in carcinomata.

Dermatitis in the human is, in some instances, of a saccharomycetic origin and no doubt some of the resistant cases of dermatitis in domestic animals have a similar cause.

The principal pathogenic saccharomyces that concerns the veterinarian is the *Saccharomyces farciminosus*, which has been described by Rivolta as the *Cryptococcus farciminosus*. This yeast is the cause of epizootic lymphangitis, a disease which affects equines and primarily involves the cutaneous lymphoid tissue. The disease is prevalent or has prevailed in many localities in the United States, and in the Phillipines, as well as, in India, Japan, China, South Africa, England and Ireland. The principal lesions are located in the lymphoid tissue which becomes tumefied and inflamed and in which the lymph sinuses are found to be engorged with coagulated lymph and pus. The lymphoid tissue later undergoes central liquefying necrosis and this is followed by the formation of pustules or ulcers. After the discharge of the pus the ulcer gradually heals and the related tissue becomes indurated. In a few cases lesions have been observed in the liver and spleen.

Two other pathogenic fungi that have not been satisfactorily classified are the *Actinomyces Bovis* and the *Botryomyces Ascoformans*. These are the causative agent of Actinomycosis and Botryomycosis respectively. These micro-organisms as well as the diseases they produce will be discussed later.

Schizomycetes. (Bacteria).

As will be noted by the foregoing scheme, bacteria are classed among the lowest groups of plants. Each bacterium is a single cell and contains no chlorophyll.

The science of bacteriology is of recent development, because early investigators were compelled to use comparatively crude microscopes and because they were not familiar with the conditions required for bacterial growth. The development of bacteriology was coincident with the discussion pro and con of the theory of "spontaneous generation." This theory was disproved

by Pasteur about 1865, whose classical experiments also aided in establishing bacteriology as a science. (It is possible that bio-



Fig. 21.—Showing different forms of **Cocci**.
 1. Micrococcus. 4. Tetrads.
 2. Streptococcus. 5. Sarcina.
 3. Diplococcus.

chemists may produce life, (animate objects), by synthesis of inanimate substances which will only represent the achievements of ultratechnical scientists and will not signify that spontaneous generation occurs in nature). Thirty or forty years ago the study of bacteria was looked upon as a fad by the majority of the people. However, the practical application of bacteriologic knowledge in medicine, sanitation, the various arts and agriculture, has caused bacteriology to assume its present important position as one of the principal biologic sciences.



Fig. 22.—Various forms of **Bacilli**.

Bacteria are found everywhere that animals or higher plants have grown. They are practically omnipresent.



Fig. 23.—Various forms of **Spirilla**.

Bacteria are single celled plants, each individual possessing a cell body and a cell membrane. The cell body is principally composed of protoplasm, which may be homogeneous or granular. In some instances non-protoplasmic particles may be present. Chromatin, the essential nuclear material, is regularly distributed throughout the entire cell body and no doubt functions the same as a nucleus. Granules that are intensely stained with methylene blue occur in the body of some bacteria, but their significance is not known. The cell bodies of some bacteria contain starch granules while those of others contain sulphur

granules. The cell membrane is of a protoplasmic nature and is probably formed by condensation of the protoplasmic cell body, whereas cellulose constitutes the cell membrane of the cells of higher plants. Some species possess organs of locomotion called flagella, which are delicate protoplasmic projec-

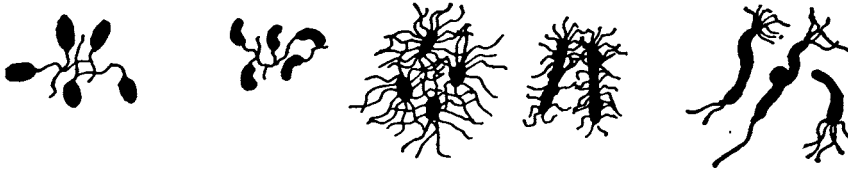

Fig. 24.—Flagellate bacteria of various forms

tions of the cell body or cell membrane. Some bacteria, perhaps all, possess a capsule which appears as a gelatinous substance and is probably derived from the cell membrane. The cell body is the essential structure and presides over metabolism, reproduction and practically all other functions. Circulatory, nervous and excretory organs are obviously not required in such simple forms of life. The cell membrane protects the cell body.




Fig. 25.—Bacteria, showing capsule.

Bacteria are very small, one eight millionth part of a cubic inch has been estimated as the least mass capable of being detected with the naked human eye. This space may contain about 2,000,000 bacteria. The dimensions of bacteria are expressed in the term micron which is the unit of microscopical measurement. (A micron is $1/25,000$ of an inch and is designated by the Greek letter "Mu".) The Bacterium tuberculosis averages about 2.5 microns in length and about .5 microns in width, i. e., 1,000 tuberculosis organisms placed end to end would make one inch in length or it would take 50,000 of these bacteria placed side by side to make a linear inch. Some spher-

ical bacteria are less than one micron in diameter, e. g., the pyogenic staphylococci average .8 of a micron in diameter. Different individuals of the same species may vary considerably in size, thus the *Bacterium anthracis* may vary from four to ten microns in length. Some diseases are probably the result of infection with micro-organisms that are so small they cannot be detected by the use of present day microscopes and they also pass through the best known germ-proof filters. These infectious agents are designated as invisible or ultra-microscopic and may be present in a "filterable virus."

Morphologically bacteria are very simple. Three principal types of bacteria are recognized according to their form, viz: the rod shaped (*Bacteria*), spherical (*Cocci*), and the spirals, (*Spirilla*). Another type, characterized by branching forms, (*Chlamydo-bacteria*), has a few representatives but their classification as bacteria has been questioned. The representatives of each of the three principal groups, *Bacteria*, *Cocci* and *Spirilla*, are constant in their morphology so long as the environments remain the same, i. e., the progeny of bacilli are bacilli, etc. Again, each individual is constant in its form, increase in size being the only change that occurs. Frequently, however, unfavorable conditions may cause pleomorphism among individual organisms.

Perhaps the best accepted morphologic classification of bacteria is as follows:—

1. Coccaceae, spherical shaped bacteria.
2. Bacteriaceae, rod or cylindrical shaped bacteria.
3. Spirillaceae, spiral shaped bacteria.
4. Chlamydo-bacteriaceae, branching or irregular forms of bacteria.

According to their biologic characteristics, bacteria may be classified as follows:—

- Aerobic or anaerobic.
- Chromogenic or non-chromogenic.
- Zymogenic or non-zymogenic.
- Saprogenic or non-saprogenic.
- Photogenic or non-photogenic.
- Thermogenic or non-thermogenic.
- Saprophytic or non-saprophytic.
- Parasitic or non-parasitic.
- Pathogenic or non-pathogenic.
- Pyogenic or non-pyogenic, etc.

Bacteria, like other living things, grow and reproduce under favorable conditions. They grow until they attain a certain size

then they divide, i. e., a cell divides into two equal halves, each half representing an individual bacterium which in turn grows and ultimately divides into two equal halves, etc., thus bacteria grow and multiply. The rate of growth and division is comparatively rapid. The *Bacillus subtilis*, under favorable conditions may pass through the life cycles incident to attaining its growth and dividing, thus doubling in number, every 30 minutes. Barber has found that *Bacillus coli communis*, under optimum conditions may divide by fission, in seventeen minutes. Beginning with one bacterium, it has been estimated that if division occurred once per hour and continued for three days, the progeny would weigh 7,417 tons. Some other cells, notably the undifferentiated cell in the animal embryo, may divide as rapidly as bacteria, but they do not become developed, and so far as known, there are no other cells that complete the entire cycle of growth and reproduction in so short a time. This method of reproduction is called fission. Fission occurs in the three principal forms of bacteria. Among the *Bacteriaceae* and *Spirillaceae*, the division takes place in the transverse diameter, while the *Coccaceae* may divide in one, two or three planes.

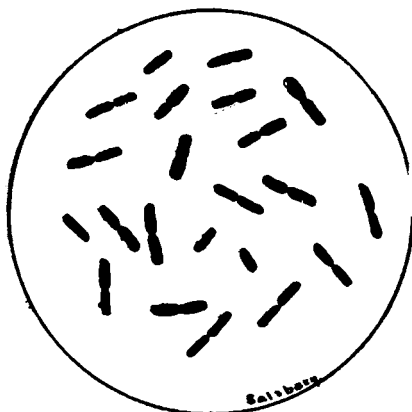


Fig. 26.—Bacteria, showing fission.

Bacteria grow and divide by fission as long as favorable conditions are supplied. When the environments are unfavorable the organisms cease growing and do not increase in number. Some species produce spores when conditions become unfavorable for further growth and fission. Bacterial spores, generally characterized by being small, highly refractive oval shaped bodies, are more condensed than the original cell body protoplasm. Spore formation is first indicated by the appearance

of small granules in the protoplasm of the parent cell. These granules collect and ultimately coalesce thus forming the spore. The spore may form in the center of the bacterium or near one end. After the spore is formed the remainder of the bacterial body becomes disintegrated. Spores are much more resistant to external injurious influences than are bacteria. The resistance of spores is due to the fact that they contain less water than bacteria, moreover they enjoy the protection of a thick covering or cell wall. Spores are inactive, i. e., they remain dormant until placed in favorable media and under favorable conditions when they germinate and develop as the vegetative form. One bacterium produces only one spore which in turn produces only one bacterium and hence spore formation is not a means of multiplication, but is rather a natural means of preservation or continuation of the species. Those species of bacteria in which no spores are formed usually have a greater resistance to injurious influences than do the vegetative forms of the species which are capable of producing spores.




FIG. 27.—Showing spore formation.

Bacterial food requirements are quite variable. Some types of bacteria require preformed organic compounds and others appear to have the power of synthesizing the simplest compounds and available elements into new compounds upon which they subsist. Until recently it was supposed that synthesis was confined to chlorophyllaceous plants but some species of bacteria are now known to possess the power of building complex compounds from simple materials, e. g., the nitrifying bacteria. Parasitic bacteria and most saprophytic bacteria as a rule require preformed organic compounds for their food. Some

soil bacteria and many water bacteria appear to live and thrive on simple inorganic substances. In fact most bacteria are capable of adapting themselves to an inorganic food medium. Food substances must be in a dilute form in order that bacteria may subsist upon them. This is probably because of the osmotic differences of bacteria and their surroundings. Some chemic substances, usually considered as destructive to bacteria, when sufficiently dilute are food for some organisms, thus the *Bacillus Pantotropus* produces formalin and then uses it for food. It is said that *Bacillus Pantotropus* may live and thrive in a 1 to 15,000 solution of formalin. Bacteria as a rule require food media of neutral or slightly alkaline reaction, (as shown by litmus paper) though some grow readily in acid media. While foods are required in small quantities only for each bacterium, yet because of their rapid mutiplication and the resulting enormous numbers, the quantity of food substances consumed by them becomes of considerable importance.

Most foods of bacteria like those of animals or higher plants, must undergo modification preparatory to assimilation. As previously stated, bacteria do not possess a digestive tube neither do they have the power of enveloping particles of food as do some protozoa. Bacterial digestion is an extracellular process, i. e., the bacterium digests food substances that are outside of its own body. This process is the same as the digestion in higher animals, the digestive tube in the latter being outside of the body tissues. Bacterial digestion is the result of activity of ferments produced by the body protoplasm and in this respect is comparable with equine digestion which is the result of activity of ferments produced by protoplasm of the salivary, gastric, pancreatic cells, etc. Some bacterial digestive ferments are very similar if not identical to the digestive ferments of higher animals.

Digested foods or food substances in solution pass into the bacterial body by osmosis.

Bacterial respiration is a simple process. The exchange of gas is probably accomplished by means of the transfusion of fluids containing the respiratory gas. Bacteria may vary in their oxygen requirement. Aerobic bacteria are those that require oxygen as a respiratory gas. Some bacteria will not develop in the absence of free ogygen, obligatory aerobes. Although it was originally supposed that all forms of life required free oxygen this is now known to be an erroneous idea. Thus, the anaerobic bacteria require the absence of free oxygen; and some organisms,—obligatory anaerobes—require the absolute absence

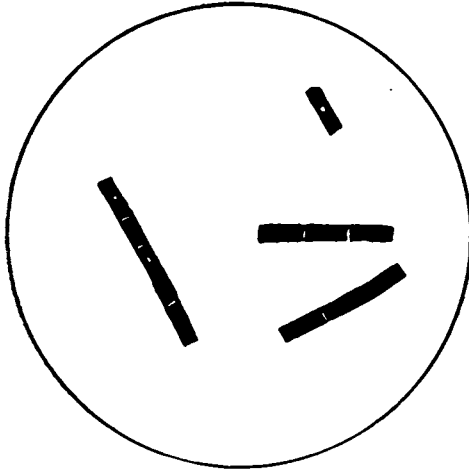
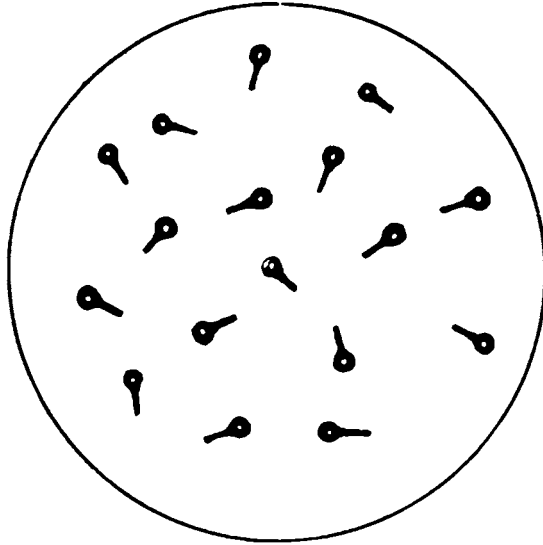


Fig. 28.—*Bacterium Anthracis*.

of uncombined oxygen. Other bacteria, facultative aerobes or anaerobes, are not so selective in their oxygen requirements, e. g., some are capable of immediate adaptation to a medium containing free oxygen. It is probable that anaerobic bacteria require oxygen as a respiratory gas but the oxygen is obtained from oxygen compounds that are decomposed by these bacteria, the oxygen probably being consumed while in the nascent state.

Moisture, temperature and light are other physical conditions that affect bacterial development. A very few bacteria will remain active in substances containing less than twenty per cent of water. The optimum condition relative to moisture, requires the presence of about 80% of water. This fact is observed in the preparation of dried food stuffs and is the essential reason why dessicants favor wound healing or retard infection. The temperature range of the various bacteria is wide. Some bacteria live and thrive at a temperature near the boiling point, others at a freezing temperature. Pathogenic bacteria, in general, require the temperature of their host. The chicken has a very high normal temperature (107° to 108° F.), and this may explain its immunity to practically all the diseases that affect other domestic animals. All bacteria require the absence of light for their best development. By adaptation some have become capable of growing and thriving in daylight.

The effects of bacterial growth and the products evolved during bacterial growth vary according to the microorganism in question and its environment. Heat and light are two forms of energy produced by bacterial activity. The heating observed

FIG. 29.—*Bacillus Tetani*.

in manure piles, alfalfa, hay and various grains in the stack is thought to be the result of bacterial action. In the above substances, the contained moisture favors the growth of bacteria and the growth of zymogenic bacteria is always dependent upon chemic changes in which complex compounds are reduced to simpler ones. Such chemical changes are accompanied by the evolution of heat. In all fermentation, in which the substances acted upon are converted into simple compounds, heat is liberated. Light or phosphorescence may be produced by bacteria. The phosphorescence of decayed wood, ocean water, flesh, etc., may accompany the growth of light producing bacteria. Light is a form of energy and bacterial light or phosphorescence is the result of the conversion of some other form of energy usually kinetic energy, into ether vibrations or light. The production of heat and light are of little importance in comparison with other bacterial products and activities.

Pigments of various kinds are produced by several different species of bacteria. These pigments may be an excretion or a secretion or they may possibly represent synthetic extracellular products or enzymotic by-products. The importance of bacterial pigments is largely confined to the discolorization of food substances. Thus the *Micrococcus roseus*, *Bacillus prodigiosus*, and *Bacillus erythrogenes*, produce a red pigment in milk. The red pigment in the milk is sometimes mistaken for bloody milk.

Other bacteria produce a variety of pigmentation in food substances. These pigments are variable in composition and solubility. Generally speaking the bacterial pigments are not injurious when consumed. Practically all pigment producing bacteria are aerobic.

The principal action of most bacteria is the result of the activity of ferments or enzymes produced by the bacterial protoplasm. Some of these bacterial ferments may produce their specific activity while inside the bacterial body, others bring about specific changes after being secreted and eliminated from the bacterial body. The end products resulting from the activity of bacterial enzymes or ferments are variable and depend upon the specific enzyme or ferment also on the composition of the substances acted upon. Acids or alkalis represent the end products of many of the bacterial decompositions. Carbohydrates are usually converted ultimately into an acid, carbon dioxide and water. Protein substances may be converted into carbon dioxide, water and ammonia by the activity of *Bacillus pyocyaneus*.

Putrefaction is a bacterial decomposition of nitrogenous substances and occurs in the absence of air. The end products of putrefaction are extremely variable; hydrogen, carbon dioxide, nitrogen, hydrogen sulphid, and ammonia, are some of the common gases that escape from a putrefying carcass; amido compounds, pepton, skatol and indol represent aromatic compounds; ptomains probably represent one of the most important putrefactive products. Ptomains are basic chemic substances produced by decomposition of nitrogenous compounds. They are usually formed outside the body, although they may be formed by putrefaction of the contents of the intestine. Ptomain poisoning is usually the result of consumption of foods contaminated with ptomains although it may result from the absorption of ptomains formed within the intestine. Sufficient ptomains may also be absorbed from necrotic tissue to produce injurious effects.

The chemic substances produced by pathogenic bacteria are probably of more importance than any other bacterial compounds. Although they have been extensively studied the composition of most of these compounds is still unknown. Three groups of pathogenic bacterial products deserve mention, they are (1) bacterial toxins, (2) endotoxins and (3) bacterial proteids.

1. Bacterial toxins are soluble, synthetical, poisonous, chemic substances elaborated by the bacterial protoplasm and

liberated into the surrounding media. The chemic composition of bacterial toxins is unknown. They are very similar in many respects to enzymes. They are specific, i. e., a given organism always produces a definite toxin. According to Ehrlich bacterial toxins are composed of two combining groups, one the haptophore which combines with the receptors of the animal cells and form a medium through which the other group, toxophore, acts. They are the principal product in some infection, e. g. tetanus. (Infection is the invasion into a living body of pathogenic micro-parasites, and the sum total of the disturbance produced by their presence in the body). During infection the body attempts to neutralize bacterial toxins by the production of a substance termed an antitoxin.

2. Endotoxins are poisonous chemic products formed and retained within the bacterial body. They become liberated only when the bacteria are destroyed and disintegrated. Although the chemistry of endotoxins is not known, they are probably constant in composition and produce specific symptoms in infected animals. The animal body does not produce antibodies that neutralize endotoxins, but opsonins, bactericidal substances and agglutinins are produced in the tissues of animals immunized to endotoxins. Endotoxins are the principal injurious substances produced by pyogenic Cocci, *Bacterium Tuberculosis*, the organisms causing glanders, pneumonia, and other specific infections.

3. Bacterial proteids are insoluble nitrogenous constituents of the bacteria cell protoplasm. They are not well understood. (See insert No. 2.)

ANIMAL PARASITES.

The animal parasites, capable of producing disease in animals, are quite numerous and represent the following branches of the animal kingdom:—protozoa, helminthes, and arthropoda.




Fig. 30.—*Piroplasma Bigeminum* in the red blood corpuscles.

INSERT II.

The following are the more important bacteria, the animals susceptible to their action and the disease each produces:

<i>Bacillus aerogenes capsulatus</i>	Gasæus emphysema	All animals
<i>Bacillus alvei</i>	Foul brood	Bees
<i>Bacillus anthracis</i> symtomatici	Black leg	Cattle
<i>Bacillus coli communis</i>	Cellulitis, nopharitis, enteritis	All animals
<i>Bacillus enteritidis</i>	Enteritis	Bovines
<i>Bacillus necrophorus</i>	Necrotic, stomatitis, foot rot	Calves, sheep Hogs, dog
<i>Bacillus oedema maligni</i>	Malignant œdema	All animals
<i>Bacillus pyocyaneus</i>	Suppuratation	All animals
<i>Bacillus tetani</i>	Tetanus	All animals
<i>Bacterium anthracis</i>	Anthrax	Mammals
<i>Bacterium astheniæ</i>	Asthenia	Fowls
<i>Bacterium dysenteriæ</i>	Dysentery	Calves
<i>Bacterium mellei</i>	Clanders	Equines
<i>Bacterium of Preisz</i>	Caseous lymph adenitis	Equines
<i>Bacterium septicaemia hemorrhagicae</i>	Pasteurellosis	Birds
<i>Bacterium septicaemia hemorrhagicae</i>	Pasteurellosis	Guinea pigs
<i>Bacterium septicaemia hemorrhagicae</i>	Pasteurellosis	Rabbits
<i>Bacterium septicaemia hemorrhagicae</i>	Pasteurellosis (Wildœuche)	Wild animals
<i>Bacterium septicaemia hemorrhagicae</i>	Pasteurellosis (Pneumoenteritis)	Sheep
<i>Bacterium septicaemia hemorrhagicae</i>	Pasteurellosis (Infectious pneumonia)	Goats
<i>Bacterium septicaemia hemorrhagicae</i>	Pasteurellosis (Pleuro-pneumonia)	Calves
<i>Bacterium septicaemia hemorrhagicae</i>	Pasteurellosis (White Scours)	Calves
<i>Bacterium septicaemia hemorrhagicae</i>	Pasteurellosis (Barbone)	Buffalo
<i>Bacterium septicaemia hemorrhagicae</i>	Pasteurellosis (Infectious pneumonia)	Horses
<i>Bacterium septicaemia hemorrhagicae</i>	Pasteurellosis (Distemper)	Dogs
<i>Bacterium septicaemia hemorrhagicae</i> (bovisæpticus)	Pasteurellosis (Hemorrhagic septicaemia)	Cattle
<i>Bacterium erysipelatis suis</i>	Erysipelas	Hogs
<i>Bacterium tuberculosis</i>	Tuberculosis	All animals
<i>Cladothrix canis</i>	Suppuratation	Dogs
<i>Micrococcus caprimus</i>	Takosis	Goats
<i>Spirochaetae anserina</i>	Suppuratation	Geese
<i>Staphylococcus pyogenes albus</i>	Suppuratation	All animals
<i>Staphylococcus pyogenes aureus</i>	Suppuratation	All animals
<i>Staphylococcus pyogenes citreus</i>	Suppuratation	All animals
<i>Streptococcus pyogenes</i> (many varieties)	Suppuratation	All animals

The following bacteria may be the cause of the following diseases.

<i>Bacillus abortus vaccarum</i>	Infectious abortion	Cattle
<i>Bacterium broncholithidis vituli</i>	Caseous pneumonia	Cattle
<i>Bacterium sanguinarum</i>	Infectious lukemia	Fowls
<i>Bacterium swine plague</i>	Swine plague	Hogs
<i>Micrococcus abortivus equi</i>	Infection abortion	Horses
<i>Micrococcus mastitidis ovis</i>	Mastitis	Ovines
<i>Micrococcus tetragenous</i>	Umbilical suppuratation	Calves
<i>Streptococcus agalactiae</i>	Mastitis	Cattle
<i>Streptococcus equi</i>	(Schultz) Strangles	Equines
<i>Streptococcus vaginalis vaccarum</i>	Infectious vaginitis	Cattle

Protozoa.

Protozoa are microscopic single celled animals. They are very simple in structure, being composed of a mass of protoplasm with or without a cell membrane. The cell membrane, when present, consists of concentrated protoplasm. The protozoa having a cell membrane are constant in shape, as the *Trypanosoma Evansi*, and those not possessing a cell membrane vary in shape from a sphere to an irregular flat mass and are capable of changing their shape whenever occasion demands. Protozoa are larger than bacteria.

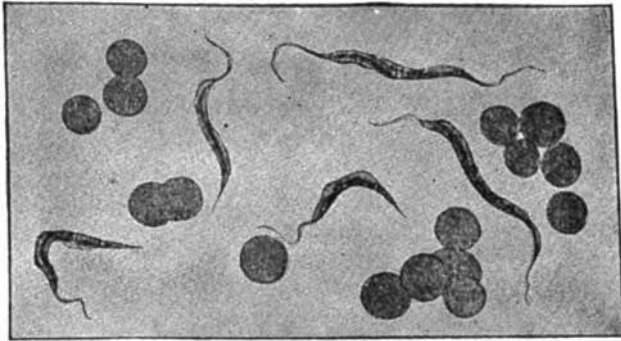


FIG. 21.—*Trypanosoma Evansi* in a bloodsmear from a horse affected with surra.

Protozoa require food similar to the foods of higher animals. Particles of food are inclosed or incorporated by them preparatory to digestion. Digestion is accomplished by means of ferments elaborated and secreted by the protozoa. The digested foods pass by osmosis into the protozoa, the undigested portion being extruded by rearrangement of the cell protoplasm. Respiration takes place by exchange of gases through the surface protoplasm of the protozoa. **They** reproduce by fission, budding, conjugation or sporulation.

Protozoa are universally distributed. They all require considerable moisture. In fact most of them live either in fresh or salt water. A few only are parasitic.

The specific action of pathogenic protozoa in the production of disease is not understood. Some may have a mechanical effect only but the evidence concerning others indicates that most of them produce an injurious chemic substance.

Helminthes.

This branch of the animal kingdom contains many species that are parasitic. Structural, animal parasites are much simpler

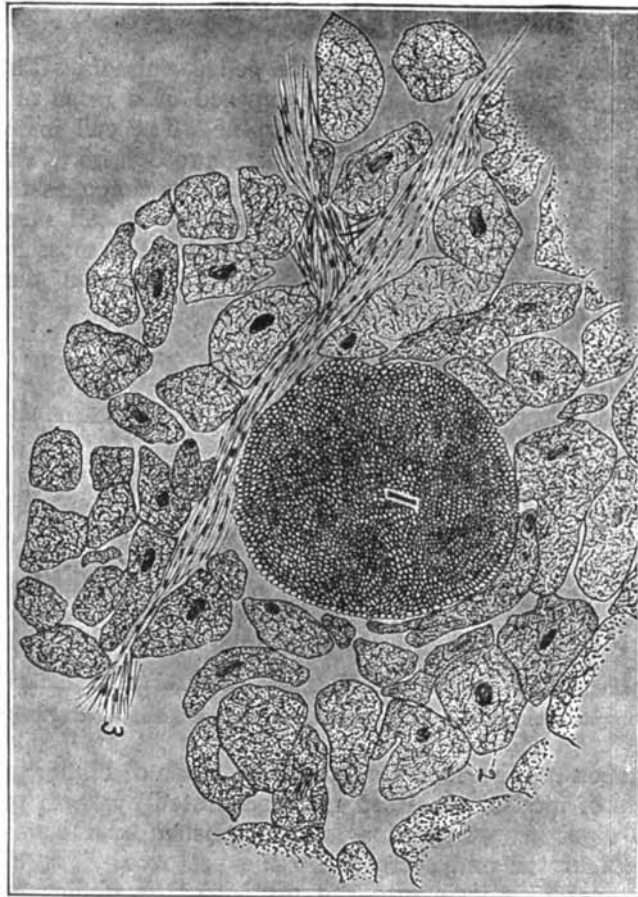


FIG. 32.—*Sarcocystis Miescheri*. Drawing made with Camera lucida.
 1. Cross section sarcocyst, muscle cell enclosing sarcocyst ruptured.
 2. Cross section of heart muscle cell.
 3. Fibrous connective tissue.

than the closely related nonparasitic animals. The simplicity of parasites is a result of adaptation to environments in which essential structures of the nonparasitic type, useless to the parasitic type, atrophy because of disuse. The parasitic helminthes are of the simplest structure, their nervous, digestive and respiratory systems being very rudimentary.

Their food is obtained from their host. Some animal parasites, as the tapeworm (*Taenia*) absorb digested food stuff from the intestine of their host, others subsist upon the host's blood, (*Uncinaria*), and still others consume tissue juices and lymph, (*Trichina spiralis*). The reproduction of helminthes is accom-

BRANCH	ORDER	CLASS
PROTOZOA. Unicellular animal organisms, asexual, reproduce by fission, sporulation, or budding.	SPOROZOA. Reproduce by sporulation, no flagella, no cilia.	COCCIDIA.
		SARCOSPORIDIA.
		FLAGELLATA.
		HYPOTRICHA.
ANNULATA. Specialized worms composed of ring like segments, simple head and eyes, usually eversible dentated pharynx, straight alimentary canal, well developed nervous system.	HIRUNDINEA. Slightly flattened on dorsal and ventral surface, sucker at each end.	GNATHOBDELLA.

INSERT III.

ILLY	GENUS SPECIES	HOST	PART INFESTED
ROSPERMIDAE.	<i>Coccidium oviforme</i>	Rabbits, G. pigs and man	Liver and intestine.
	<i>Coccidium cuniculi</i>	Rabbit.	Lieberkuhn's glands and intestine.
	<i>Coccidium avium</i>	Fowls.	Liver and intestine
COSPORIDAE.	<i>Sarcocystis Miescheri</i>	Pig.	Muscles.
	<i>Sarcocystis tenella</i>	Horse, ox, sheep, and pig.	Muscles.
	<i>Balbiania gigantea</i>	Ox, sheep and dog.	Connective tissue.
COMONIDAE.	<i>Lamblia intestinalis</i>	Sheep and dog.	Intestine.
	<i>Monocercomonas hepatica</i>	Pigeons.	Liver.
PANOSOMATIDAE.	<i>Trypanosoma equiperdum.</i>	Horse.	Blood.
	<i>Trypanosoma Evansi.</i>	Horse.	Blood.
	<i>Trypanosoma equinum.</i>	Horse.	Blood.
	<i>Trypanosoma Brucei.</i>	Horse.	Blood.
THOBDELLIDEA.	<i>Hirudo medicinalis.</i>	Man and horse.	Skin.
	<i>Hirudo troctina.</i>	Man and horse.	Skin.
	<i>Hirudo decora.</i>	Man and horse.	Skin.
	<i>Hirudo Tagala.</i>	Man and animals.	
	<i>Haemopsis sanguisuga.</i>	Horse.	Anterior respiratory tract and intestine.

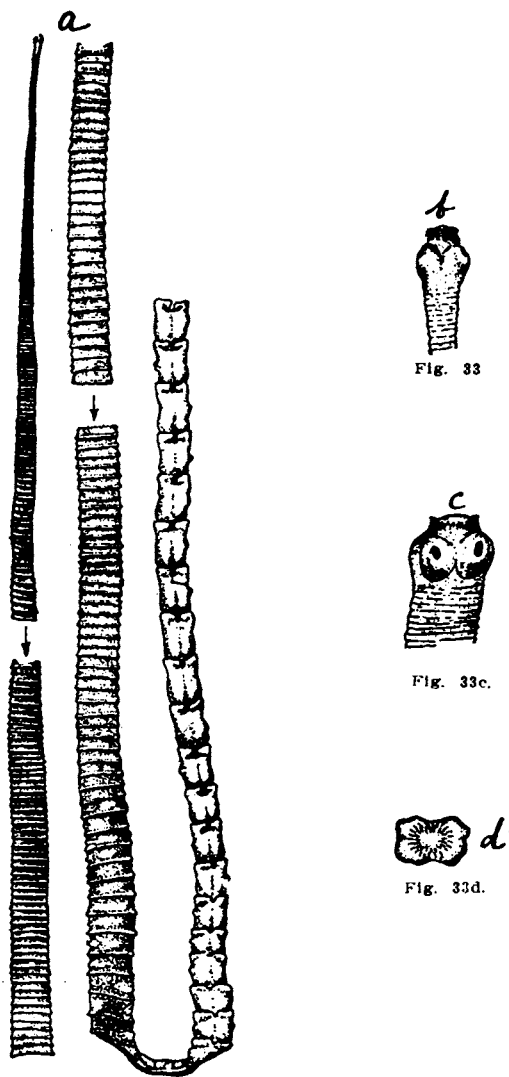


Fig. 33.—*Taenia Marginata*. After Niles.

a. Shows segments.

b. c. Head lateral view.

d. Head anterior view.

plished by means of ova, or by the production of living larvae. The life history or cycle of helminthes is very interesting. In some cases the organism is parasitic in different animals during the different stages of its life cycle; for instance the *Taenia* cras-

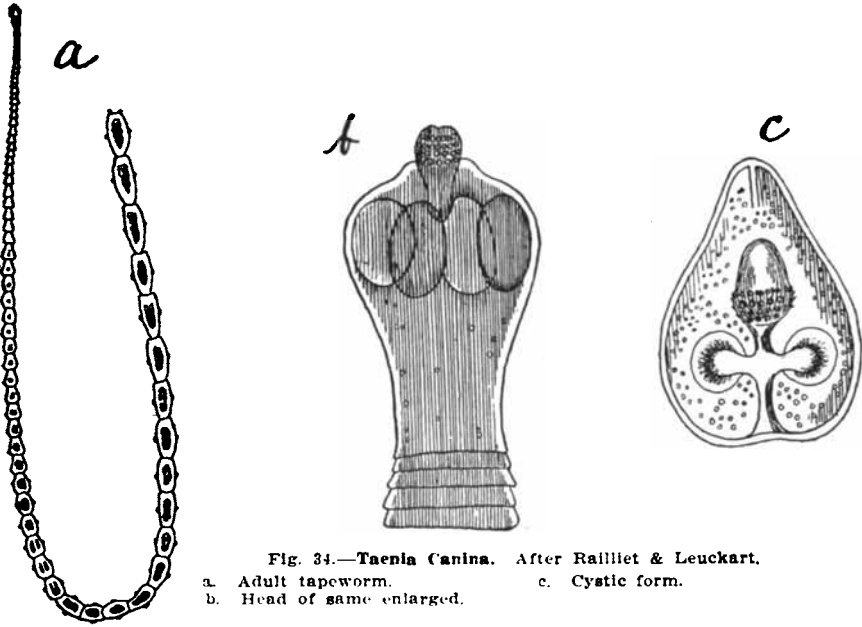


Fig. 34.—*Taenia Canina*. After Railliet & Leuckart.
 a. Adult tapeworm. c. Cystic form.
 b. Head of same enlarged.

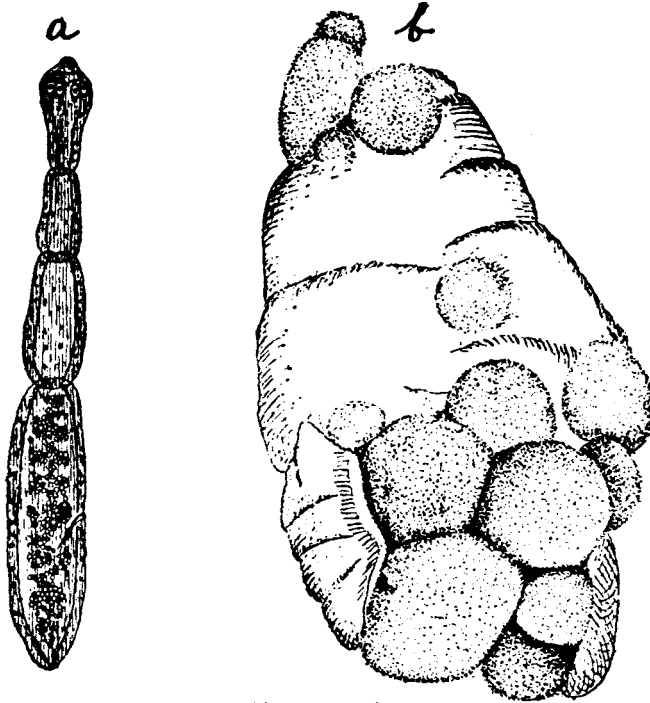


Fig. 35.—*Taenia Echinococcus*. Niles & Neuman.
 a. Adult tapeworm. After Neuman. b. Part of hog's liver showing cystic form.

BRANCH CLASS

ORDER

FAMILY

GEN

INSERT IV.

HELMINTHES

Invertebrate, body soft and contractile, no articulated appendages, no organs of special sense, excretory organs arranged in pairs.

PLATYHELMINTHES. Flat worms, nearly all hermaphrodites.

CESTODA. Ribbon shaped, segments have no fixation apparatus have no digestion apparatus on head. Adult lives in intestines.

TAENIIDAE. Head always has four suckers between which is found a depression or a proboscis. Segments usually have their genital openings on margin.

Tan
Tan
Tan
Tan
Tan
Tan

Tan
(Cys)
Tan

Tan

Tan

TREMATODA. Flat worms, nonsegmented, have digestive canal, no anus, have one or two suckers on ventral surface.

BOTHRIOCEPHALIDAE. Found mostly in fishes.

Both

Dist
Dist

DISTOMIDAE. All have two suckers, an anterior and ventral.

Dist
Ant
Par

ACANTHOCEPHALA. Slender worms, complete digestive canal, are found in all tissues of domestic animals except bone.

ECHINORYNCHIDAE. Found in digestive canal of vertebrates.

Echin

ASCARIDAE. Large firm body, resemble earth worms, mouth is surrounded by three lips. Usually found in small intestine.

Asc
Asc
Asc
Asc
Asc
Asc

OXYURIDAE. Cylindroid body, mouth pointed, mouth stomach large.

Oxy
Oxy

Stom
Stom
Stom
Stom

NEMATHELMINTHES. Round worms, nonsegmented, sexes separate.

NEMATODA. Slender worms, complete digestive canal, are found in all tissues of domestic animals except bone.

STRONGYLIDAE. Body cylindroid, mouth either nude, armed or papillated, oesophagus large.

Stom
Stom
Stom
Stom
Stom
Stom
Stom
Stom
Stom
Stom
Stom
Stom
Stom
Stom
Stom
Stom

TRICHOTRACHELIDAE. Body slender in anterior portion, enlarged posteriorly for containing intestine, mouth nude, anus terminal, all live in intestine.

Tri
Tri
Tri

FILARIDAE. Long thread like body, mouth or triangular, oesophagus small.

Fil
Fil
Fil
Fil
Fil
Fil
Fil
Fil
Fil
Fil
Fil

GNATHOSTOMIDAE. Head distinct, oviparous.

Gnath

SPECIES	HOST	PART INFESTED
<i>marginata</i>	Man	Intestine
(Cyst: <i>Cysticercus cellulosae</i> , of pig.)		Intestine
<i>solium</i>	Man	Intestine
(Cyst: <i>Cysticercus bovis</i> , of ox.)		Intestine
<i>perfoliata</i>	Horse	Intestine
<i>mamilliana</i>	Horse	Intestine
<i>plicata</i>	Horse	Intestine
<i>denticulata</i>	Ox	Duodenum and gall duct
<i>expansa</i>	Ox and sheep	
<i>umbriata</i>	Sheep	Intestine
<i>marginata</i>	Dog	Small intestine
(<i>Cysticercus tenuicollis</i> of ruminants.)		
<i>coenurus</i>	Dog, wolf and fox	Small intestine
(Cyst: <i>Coenurus cerebralis</i> in spinal cord and brain of sheep.)		
<i>echinococcus</i>	Dog and wolf	Small intestine
(Cyst: <i>Echinococcus polymorphus</i> , of herbivora and omnivora.)		
<i>cucumerina</i>	Dog	
(Cyst: (1) <i>Cryptocystis trichodactis</i> of <i>Trichodectes latus</i> .)		
(Cyst: (2) <i>Cryptocystis puleoides</i> of <i>Pulex serraticeps</i> .)		
<i>cephalus latus</i>	Man, dog, cat	Intestine
<i>hepaticum</i>	Herbivora and omnivora	Gall ducts
<i>lancoelatum</i>	Sheep, ox, goat, pig, ass, dog	Gall ducts
<i>Americanum</i>	Sheep and ox	Liver
<i>stoma cervi</i>	Ruminants	Rumen
<i>stoma Westermanni</i>	Man, dog, pig and cat	Lungs
<i>rhynchus gigas</i>	Pig	Small intestine
<i>megalocephalus</i>	Sollipeds	Small intestine
<i>bovis</i>	Ox	Intestine
<i>ovis</i>	Sheep	Intestine
<i>scutella</i>	Pig	Intestine
<i>marginata</i>	Dog	Intestine
<i>mystax</i>	Cat	Intestine
<i>curvula</i>	Horse	Posterior bowel
<i>mastigodes</i>	Horse	Posterior bowel
<i>Arnfeldi</i>	Sollipeds	Bronchi and lungs
<i>micrurus</i>	Bovines	Bronchi and lungs
<i>pulmonaris</i>	Calf	Bronchi
<i>filaria</i>	Sheep, goat, camel, deer	Bronchi and lungs
<i>rufescens</i>	Sheep, goat and deer	Bronchi
<i>paradoxus</i>	Pig	Bronchi
<i>Osteraei</i>	Ox	Abomasum
<i>contortus</i>	Sheep, goat	Abomasum and duodenum
<i>filicollis</i>	Sheep and goat	Small intestine and abomasum
<i>gigas</i>	Horse, ox, dog and man	Kidneys and urinary organs
<i>vasorum</i>	Dog	Heart
<i>stoma equinum</i>	Horse, ox, dog and man	Intestine
<i>tetracanthum</i>	Sollipeds	Large intestine
<i>hypostomum</i>	Sheep and goat	Large intestine
<i>trachealis</i>	Birds and chickens	Trachea
<i>dentatus</i>	Pig	Region of kidney and liver
<i>trigonocephala</i>	Dog and fox	Small intestine
<i>cernua</i>	Sheep and goat	Small intestine
<i>radiatus</i>	Bovines	Small intestine
<i>cephalus affinis</i>	Ox, sheep and goat	Caecum
<i>cephalus crenatus</i>	Pig	Large intestine
<i>cephalus depressiusculus</i>	Dog	Caecum
<i>spiralis</i>	Pig	Muscles
<i>papillosa</i>	Horse	Peritoneal and plural cavities
<i>servina</i>	Ox and deer	Peritoneum
<i>immittis</i>	Dog	Right heart and pulmonary arteries
<i>megastoma</i>	Horse	Right stomach
<i>microstoma</i>	Horse	Stomach
<i>reticulata</i>	Horse	Flexor tendons and cervical ligaments
<i>scutata</i>	Ox, sheep and goat	Oesophageal wall
<i>sanguinolenta</i>	Dog	Tumors of stomach, gullet and aorta
<i>stoma cheiracanthus</i>	Pig, dog and cat	Gastric mucosa

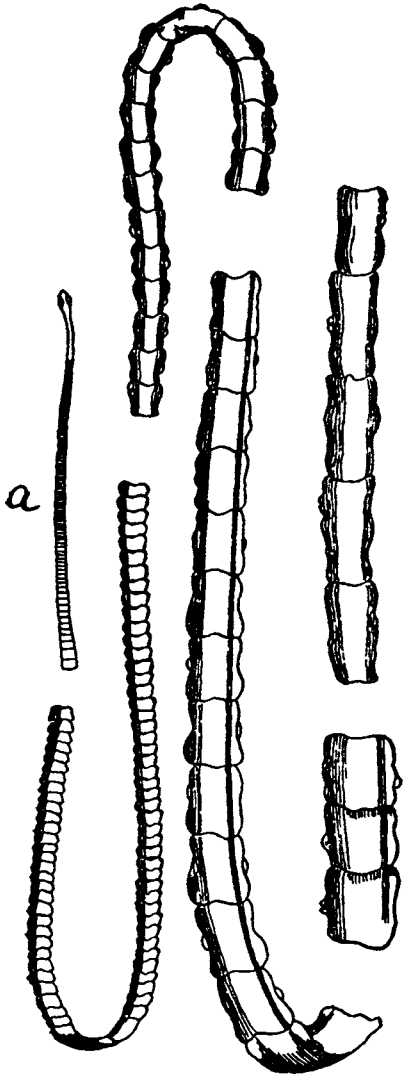


Fig. 36.—*Taenia Solium*.
a. b. Adult worm.
c. Head of same enlarged.

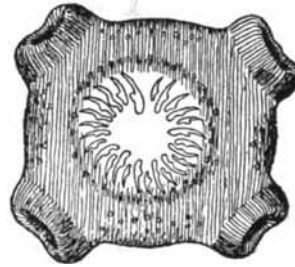


Fig. 36c.



Fig. 37a.

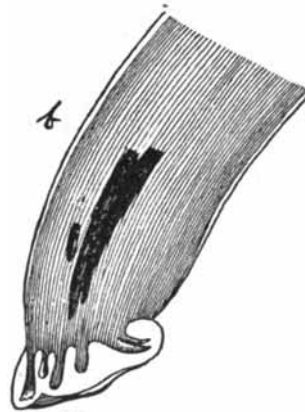
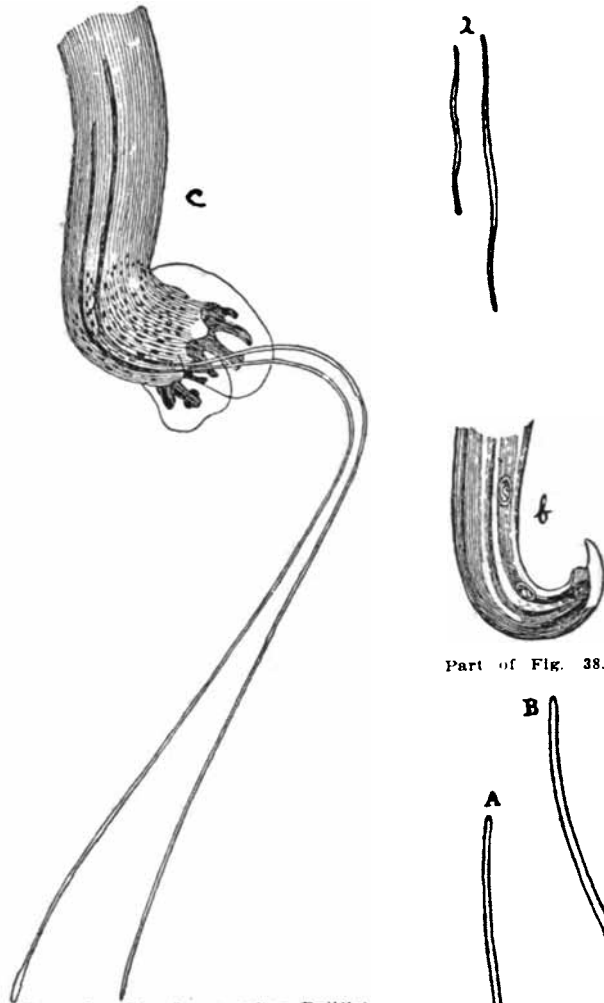


Fig. 37b.

Fig 37.—*Strongylus Mierurus*, after Railliet.
a. Male and female.
b. Caudal extremity of male.



Part of Fig. 38.

Fig. 38.—*Strongylus Paradoxus*, after Railliet.
 a. Adult male and female.
 b. Caudal extremity of female.
 c. Caudal extremity of male.

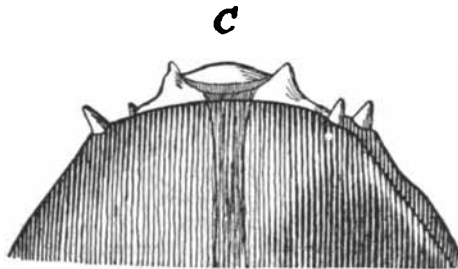


Fig. 39c.

a. Adult male.

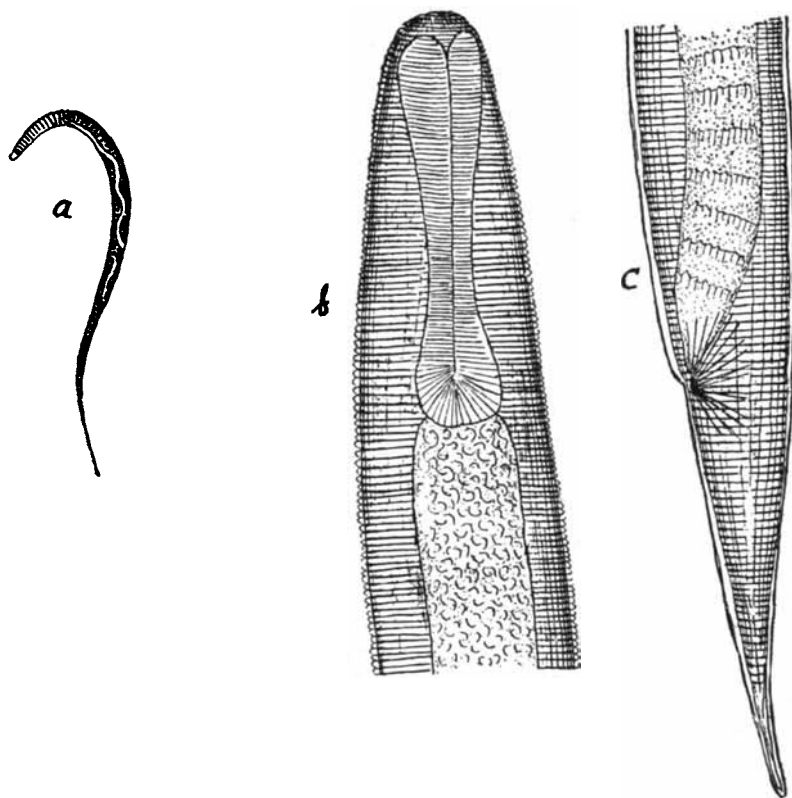
b. Adult female.

c. Cephalic extremity enlarged.

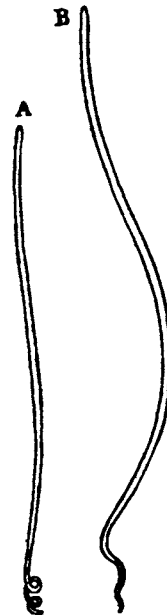

Fig. 39a. and b.

Fig. 39. *Filaria Papillosa*, after Neuman.

Fig. 40.—*Oxyuris Curvula*, after Nilés.

- a. Adult worm. c. Caudal.
b. Cephalic extremity.

sicollis inhabits the liver of the rat during its cystic stage and the intestine of the cat during the adult stage.

Helminthes produce injury to their host by consuming food, by sucking blood and by liberating injurious chemic substances.

Arthropoda.

This branch includes many parasitic representatives, as flies and mosquitoes (diptera), fleas (siphonaptera) lice (hemiptera), itch mites and ticks (acarina). The entire order, siphonaptera and hemiptera, most of the order acarina, and many representatives of the order diptera are parasitic. Of the parasitic arthropoda some are temporary and some are permanent parasites, and with one or two exceptions they are all external parasites.

The structural peculiarities that differentiate arthropoda from




Fig. 41.—*Syngamus Trachealis*,
after Railliet.
a. Adult worm natural size.
b. Male attached to female
enlarged.
c. Female enlarged.

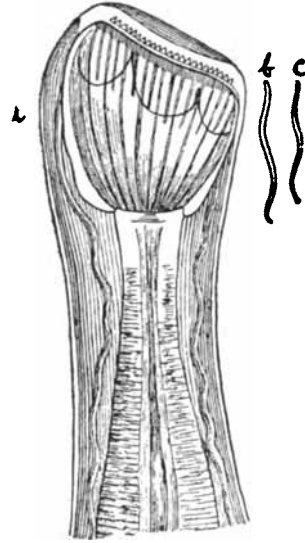


Fig. 42.—*Selerostoma Hypostomum*,
after Railliet.
a. Cephalic extremity enlarged.
b. Adult female.
c. Adult male.

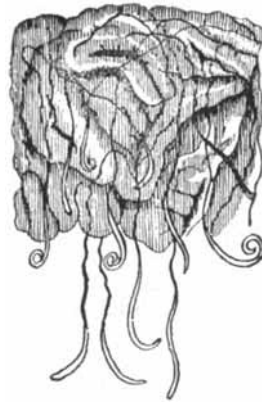

Fig. 43.—*Trichocephalus Depressuscutus*
of a Dog, after Railliet.

the other branches of the animal kingdom are their jointed appendages, segmented body, and bilateral symmetry.

The parasitic arthropoda obtain their food from their hosts. Some of them consume epidermal scales and hair, e. g., the

BRANCH	CLASS	ORDER	FAMILY	GE		
INSECT V. ARTHEPODA Invertebrates with jointed appendages arranged in pairs.	INSECTA (HEXAPODA). Air breathers, when adult have three pairs of legs, and distinct head, thorax and abdomen.	DIPTERA Have two wings, two halteres, sucking mouth parts, and complete metamorphosis. Includes flies and mosquitoes.	MUSCIDAE Have soft proboscis adapted for suction, stylus of antennae plumose to the end.	Mu Mu Sal Sto He Ca		
			TABANIDAE Broad and slightly flattened body, large head, muscular wings, larva carnivorous, are oviparous.	Ta Ta		
			STOMOXIDAE Closely resembles the muscidae.	Gl		
			SIMULIIDAE Thick body, bulging thorax, legs strong.	Sin		
			HIPPOBOSCIDAE Flat body, head notched into thorax, legs strong, pupiparous.	Me Hi		
			OESTRIADAE Body usually hairy, large wings, proboscis very small, oviparous.	Ca Ga Hy Oet		
			CULICIDAE Have long slender abdomen, wings fringed with hairs, antennae plumose in males, oviparous.	Cul Cul An Ste		
			HEMIPTERA Wings often absent, when present one pair thick and one pair thin. Sucking mouth parts, incomplete metamorphosis, and include the blood sucking lice.	PEDICULIDAE Blood suckers, proboscis formed of upper and lower lips and armed with small spines, contains protrusible tube or sucker, oviparous.	He He He He He	
			MALLOPHAGA Wingless lice with sucking mouth parts, and incomplete metamorphosis.	RISCINIDAE Not blood suckers, have long masticatory apparatus with which they eat epidermic productions, oviparous.	Tri Tri Tri Tri	
			SIPHONAPTERA Wingless fleas with sucking mouth parts, and complete metamorphosis.	PULCIDAE Very agile, brown oval bodies, compressed latterly, biting mouth parts in larval stage.	Pul Pul Pu	
		ACARINA Usually short thick, non-articulated bodies, possess camerostruma, larva usually hexapodal, sexes separate.	ARACHNIDA Air breathers with cephalothorax and abdomen, have when adult four pairs of legs. Those here included are oviparous.	IXODIDAE Large globular blood-suckers, oviparous, have undivided hypostome.	Bo Bo Am De Orr Ixo Ar	
				GAMASIDAE Rostrum arranged for pricking or sucking, have no eyes.	De	
				TROMBIDIIDAE Soft, hairy, bright colored, rostrum a conical sucker.	Tro Lef	
				SARCOPTIDAE Smallest of the acarina, body soft, white or reddish, eyes absent, oviparous or ovoviviparous.	Sar Sar Sar Sar Pao Pao Syn Syn Syn Syn	
				DEMODECIDAE Very small, vermiform, hairless, cephalothorax and abdomen distinct, legs short, oviparous.	De De De	
				LINGUATULIDA Internal parasite, elongated, vermiform, annulated	LINGUATULIDAE Body segmented, compressed dorso-ventrally, crenelated.	Liu

US SPECIES	HOST	PART INFESTED
<i>a domestica</i>	Not generally parasitic	
<i>a vomitoria</i>	Animals	Wounds
<i>aphaga carnaria</i>	Animals	Wounds
<i>oxys calcitrans</i>	Animals	Skin
<i>stobia serrata</i>	Animals	Skin
<i>scomyia macellaria</i>	Animals	Wounds
<i>nus atratus</i>	Animals	Skin
<i>nus lineola</i>	Animals	Skin
<i>ina morsitans</i>	Animals	Skin
<i>Hum pecuarum</i>	Animals	Skin
<i>phagus ovinus</i>	Sheep	Skin
<i>oboea equina</i>	Horse	Skin around perinaeum
<i>ophlius equi</i>	Horse	M. M. of stomach
<i>ophlius hemorrhoidalis</i>	Horse	M. M. of stomach and intestine
<i>derma lineata</i>	Ox	Dorsal cutis and subcutis
<i>us ovis</i>	Horse	Sinuses of head
<i>equinus</i>	Sheep	Skin
<i>piplens</i>	Animals	Skin
<i>holes punctipennis</i>	Animals	Skin
<i>mia fasciata</i>	Animals	Skin
<i>topinus macrocephalus</i>	Horse	Skin
<i>topinus eurystermnus</i>	Ox	Skin
<i>topinus vituli</i>	Ox	Skin
<i>topinus piliferus</i>	Dog	Skin
<i>topinus irritans</i>	Pig	Skin
<i>topinus stenopsis</i>	Goat	Skin
<i>odectes pilosus</i>	Horse	Skin
<i>odectes scalaris</i>	Ox	Skin
<i>odectes spaerocephalus</i>	Sheep	Skin
<i>odectes latus</i>	Dog	Skin
<i>irritans</i>	Man	Skin
<i>serraticeps</i>		Skin
<i>avium</i>	Fowls	Skin
<i>ilus annulatus</i>	Ox	Skin
<i>ilus Australis</i>	Ox	Skin
<i>omma Americanum</i>	Ox	Skin
<i>centor electus</i>	Sporting dogs	Skin
<i>odoros Megnini</i>	Horse, ox, sheep and dog	Skin
<i>ricinus</i>	Sporting dogs	Skin
<i>miniatas</i>	Fowls	Skin
<i>nyasus gallinae</i>	Fowls	Skin
<i>idium holosericeum</i>	Animals	Skin
<i>irritans</i>	Man and animals	Skin
<i>tes scabel-var. equi</i>	Horse	Skin
<i>tes scabel var. ovis</i>	Sheep	Skin
<i>tes scabel var. suis</i>	Pig	Skin
<i>tes scabel var. canis</i>	Dog	Skin
<i>tes mutans</i>	Fowls	Skin
<i>tes communis var. equi</i>	Horse	Skin
<i>tes communis var. bovis</i>	Ox	Skin
<i>tes communis var. ovis</i>	Sheep	Skin
<i>tes scabel var. equi</i>	Horse	Skin
<i>tes scabel var. bovis</i>	Ox	Skin
<i>tes scabel var. ovis</i>	Sheep	Skin
<i>tes auricularum var. canis</i>	Dog	Skin
<i>tes auricularis var. felis</i>	Cat	Skin
<i>ex folliculorum var. equi</i>	Horse	Skin
<i>ex folliculorum var. bovis</i>	Ox	Skin
<i>ex folliculorum var. canis</i>	Dog	Skin
<i>tula taenoides</i>	Dog	Nasal cavities

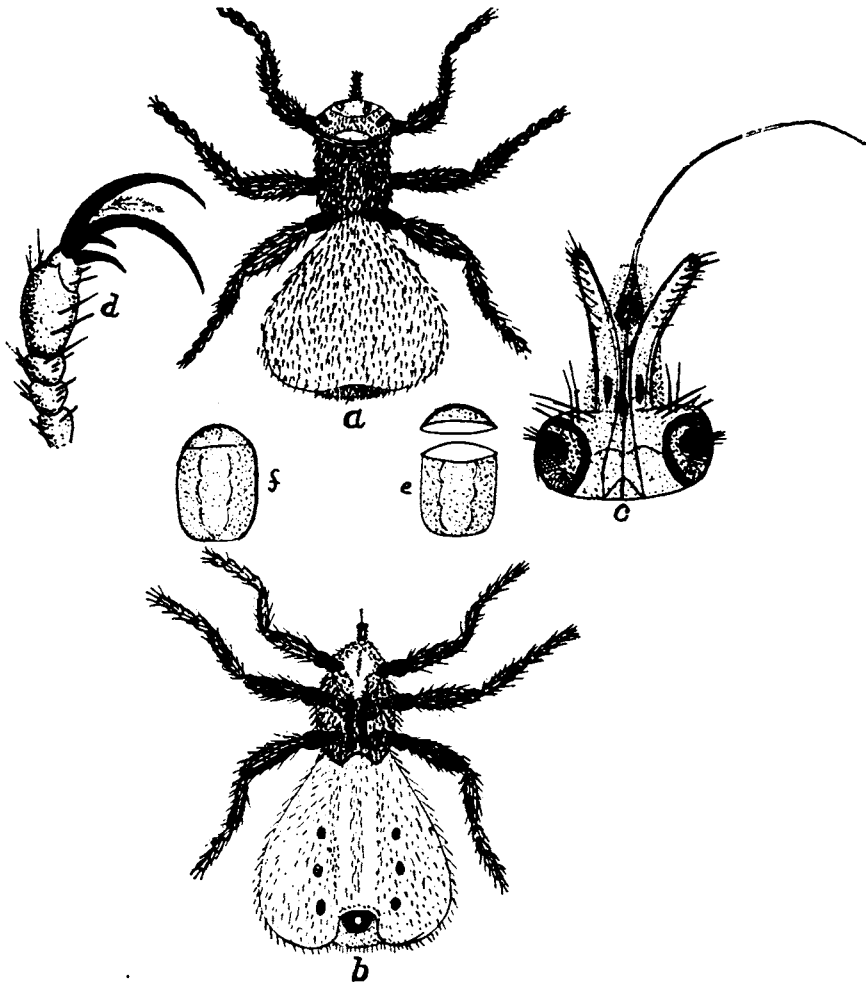


Fig 44.— *Melophagus Ovinus*, after Niles.
 a. Dorsal view of adult. d. Terminal segment of leg.
 b. Ventral view of adult. e. Shell of pupa.
 c. Mouth parts enlarged. f. Pupa.

horse louse (*Trichodectes Pilosus*) and feathers, e. g., the chicken louse (*Menopon Pallidum*) others abstract blood, e. g., the hog louse (*Hematopinus Suis*), Itch mite (*Sarcoptes scabei* variety *canis*), and still others may consume tissue cells other than blood cells as epithelium. Reproduction of arthropoda is about the same as it is in helminthes.

Disease resulting from infestation of arthropoda is due primarily to irritation induced mechanically or by chemic products of the parasites, secondarily to loss of blood.




Fig. 45—Part I.

Gastrophilus Equi, after Niles.

- a. Adult female.
- b. Adult female.
- c. Young larvae.
- d. Full grown larvae.
- e. Eggs cemented to hair.
- f. Egg shell showing lifting of operculum.
- g. Adult male.
- h. Terminal segments of male.
- i. Terminal segments of female.

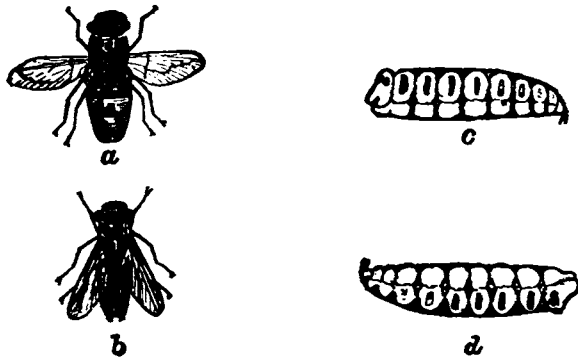


Fig. 46.—Part II. *Oestrus Ovis*.

- a. Adult female.
- b. Adult male, after Riley.
- c. Dorsal view of larva.
- d. Ventral view of larva, after Riley and Niles.

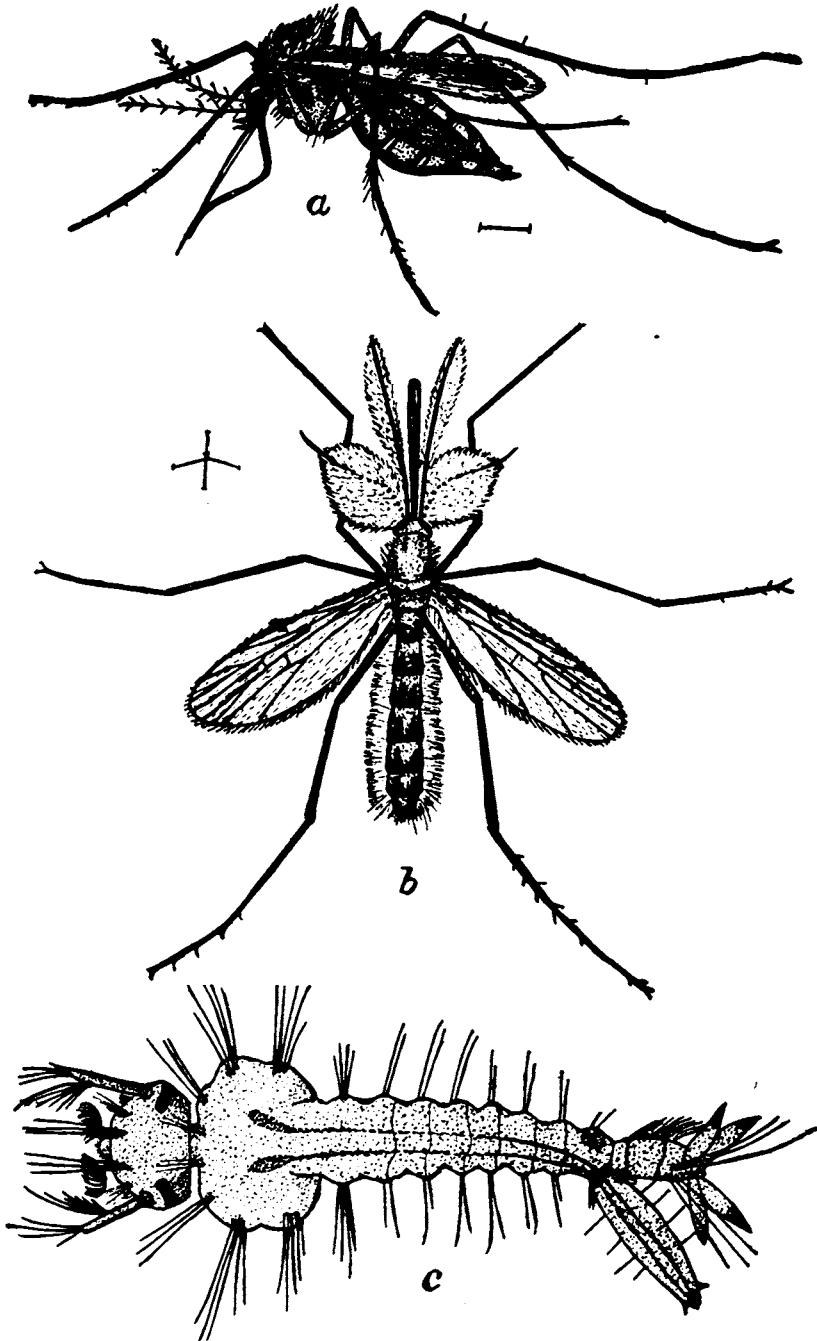


Fig 47.—Culex Pungens, after Howard.
a. Female. b. Male. c. Larva.

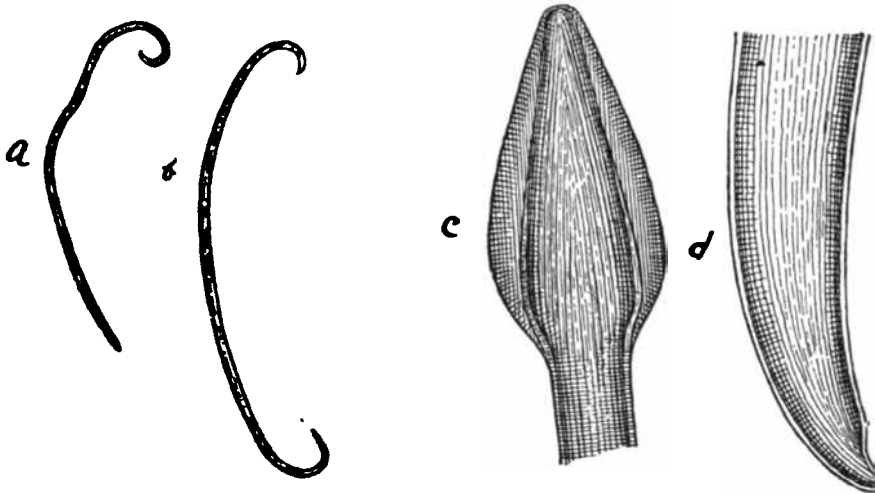


Fig. 48.—*Ascaris mystax*, after Niles.
 a. Adult male. a. Cephalic extremity.
 b. Adult female. d. Caudal.

Extension of Disease.—By extension of disease is meant the invasion and affection of adjacent structures and even remote tissues of the body. Some diseases are necessarily local, i. e., the cause is not capable of being transferred to adjacent or remote structures, e. g., ocular filariosis. Other diseases are in their earlier stages local, but later the cause may be transferred to some other part and produce secondary diseased foci or

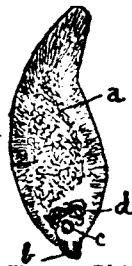


Fig. 49.—*Distoma hepaticum*.
 a. Intestines.
 b. Oral sucker.
 c. Ventral sucker.
 d. Uterus.

metastases, e. g., tuberculosis. The extension of disease may be produced as follows:

First, by the cause of the disease passing along the natural channels and establishing secondary diseased foci, thus, Bray reports that calves become affected with necrotic gastritis and

enteritis when allowed to swallow the necrotic tissue during an attack of necrotic stomatitis.

Second, by the spread of the cause into adjacent tissues, e. g.: Extension in like tissue, as in muscular tissue, is continuity as psorospermiosis, while extension from one tissue to another of a different type, as from muscular to connective tissues, is contiguity as in actinomycosis.

Third, by the lymph and lymphatic nodes, e. g. tuberculosis.

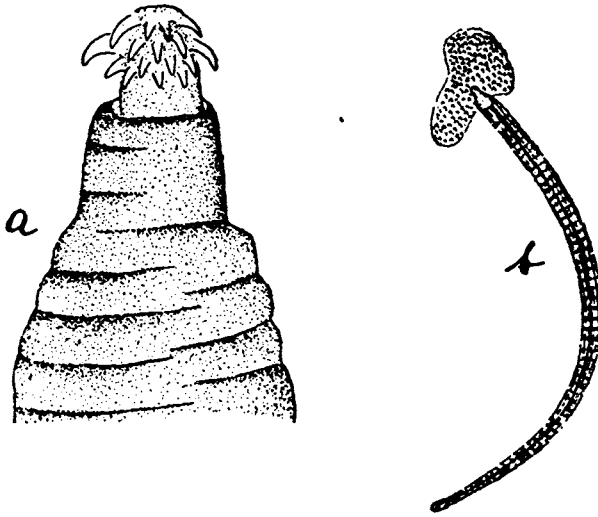


Fig. 50.—*Echinorynchus Gigas*, after Niles.

- a. Cephalic extremity showing hooks.
b. Worm with portion of mucous membrane of intestine attached.

Fourth, by the blood stream in which case the metastases will be in the lungs, liver or kidney,—e. g. anthrax.

Fifth, by passing along the nerve fibers as in rabies.

Termination of Disease.—Termination is the ending or outcome of the condition or existing disease. Disease terminates as follows:—

Recovery.—Disease terminates in recovery when the body tissues are effectually repaired and all structures have assumed their normal function. Diseases resulting from irritating or non-nutritious foods are corrected by expulsion or neutralization of the causative agent either by vomiting, purgation or chemical union and by repair of the injured tissues, after which normal functioning continues. Tissue afflicted with mechanical

injuries as wounds, recover when the destroyed portions have been replaced and the normal function has been resumed. Dislocations terminate in recovery when the dislocations have been reduced and the parts assume their normal function. A horse recovers from pneumonia when the inflammatory exudate has been removed from the alveolar spaces and all injured

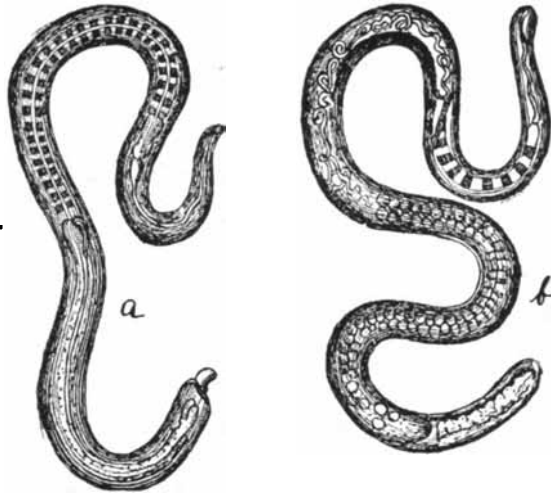


Fig. 51.—*Trichina Spiralis*, after Colln.

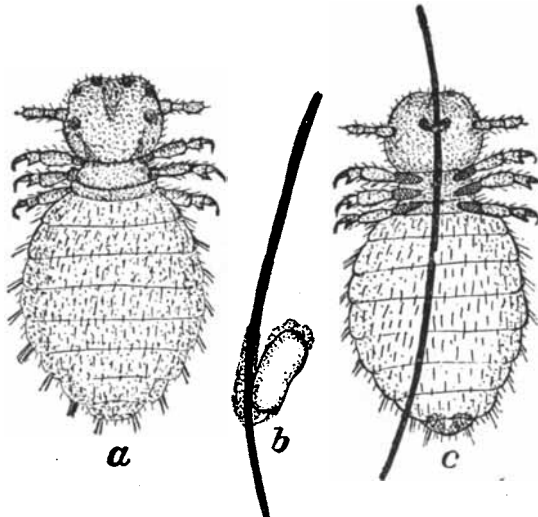


Fig. 52.—*Trichodectes Latus*, after Niles.

a. Dorsal view. b. Egg cemented to hair. c. Ventral view.

tissues have been repaired and the normal functioning has been re-established. In general, recovery is the result of the activities of the protective and reparative processes of the various tissues of the animal body.

Partial recovery.—If the normal functioning is not assumed after a disease has run its course, recovery is said to be incomplete or partial. Partial recovery is observed in old animals or in those that have been depleted because of complications or previous disease. Some diseases are essentially destructive and their influence in the tissue results in incomplete repair, as in tuberculosis, glanders, dourine, bovine contagious pleuro-pneumonia, etc. Injuries and acute inflammation of the parieties of hollow organs frequently terminate in the formation of cicatricial tissue thus contracting the lumen of these organs. This is common in injuries of the oesophagus, intestine, trachea, and urethra. Adhesions succeeding pericarditis, pleuritis, and peritonitis are examples of partial recovery.

Death.—Disease may terminate in the cessation of all functions, i. e. death. The more important specific modes of death are as follows:

1. Syncope, or heart failure, a result of paralysis of cardiac nerves or muscles, rupture of heart walls or complete obstruction to emerging vessels of the heart. Nerve paralysis may be the result of poisonous products derived from infectious agencies, or chemic poisons derived from katabolism, or hemorrhagic extravasates.

2. Apnoea, or respiratory failure. This may be the result of paralysis of respiratory nerves or muscles, spasms of respiratory muscles, rupture of diaphragm, or occlusion of the respiratory tubes.

3. Apoplexy, or hemorrhage into the brain tissue. This is probably the specific cause of death in apoplectiform anthrax.

4. Hemorrhage, especially rapid loss of large quantities of blood. Any of the above may act independently in producing death, but are probably more frequently complicated one with another.

CHAPTER III.

IMMUNITY.

DEFINITION.

IMPORTANCE.

VARIETIES.

Inherited, (Natural).

Definition.

Examples.

Cause.

Cell Action, (Metchnikoff & Sternberg).

Chemic Substance, (Ehrlich & Buchner).

ACQUIRED, (Artificial).

Definition.

Examples.

Varieties.

Active.

Definition.

Varieties, (Toxic), (Bacterial).

Etiology.

Recovery from attack of disease.

Inoculation with virus.

Inoculation with vaccine.

Inoculation with bacterin.

Inoculation with toxin.

Inoculation simultaneously with virus and antibody.

Passive.

Definition.

Etiology.

Inoculation with antibody.

THEORIES.

Exhaustion.

Retention.

Phagocytosis.

Humoral.

Ehrlich's Lateral Chain Theory.

Immunity literally means proof against disease, i. e., it is the name of the condition that enables an animal to resist the action of pathogenic micro-organisms, or to be unaffected by their products. Immunity is only a relative term, the condition is not absolute and permanent neither is it constant and continuous. Whenever an animal is unable to adjust itself to its environments it becomes susceptible to the effects of the causative agents of diseases, i. e., its immunity, at least acquired immunity, is suspended.

The term immunity is ordinarily used in reference to infective diseases, i. e. those diseases resulting from the invasion of microparasites; although it may be used in designating the resistance to the action of zootoxin, such as snake venom, and possibly also of the poisonous substances ejected by centipedes

and scorpions, as well as the phytotoxins, such as ricin, abrin, croton, and robin.

Immunity, more than any other problem, directly concerns the medical profession and indirectly the international commer-

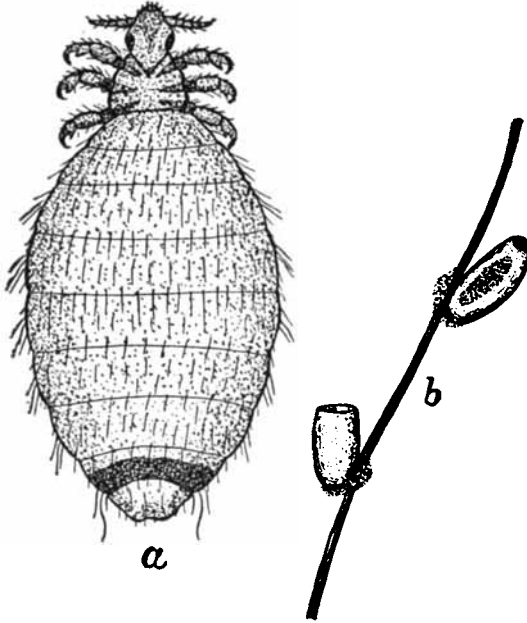


Fig. 53.—*Hematopinus phalanges ovis*, after Niles.
 a. Adult. b. Egg cemented to hair.

cial welfare. It was a laboratory fad of the pathologists until they demonstrated to the practitioners that it was feasible to produce immunity in man and animals. Veterinarians have now

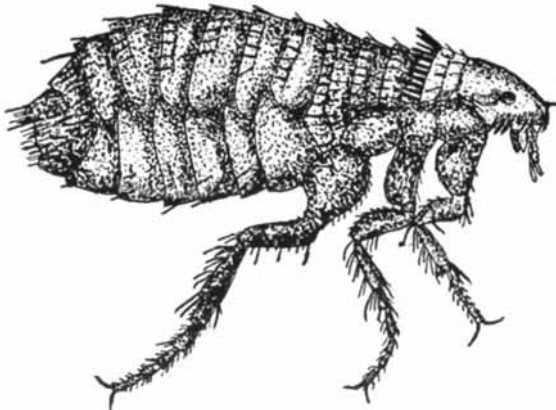


Fig. 54.—*Pulex Serraticeps*, after Tuzzer

almost universally accepted the proposition and have at their command the means by which they can immunize animals against the ravages of some of the fatal infective diseases to which they are susceptible. The increased confidence of the people is in turn enabling scientists to investigate new phases of the subject. Although immunization has been known and made use of more or less for centuries as vaccination against




Fig. 55.—*Margaropus Annulatus*, female.



Fig. 56.—*Margaropus Annulatus*, male.



Fig. 57.—*Margaropus Annulatus*, female laying eggs.



Fig. 58.—*Margaropus Annulatus*, Larva.

smallpox by the Chinese before the Christian era, yet the essential physiologic, chemic or pathologic basis for immunity is still unknown.

Immunity may be natural (inherited) or artificial (acquired).

Natural immunity is an inherited property possessed by organisms (animals). The horse has a natural immunity to hog cholera, the ox to glanders and the hog to tick fever. The concise and exact cause of natural immunity is unknown. It is probably the result of cellular activity in the immune animal, an activity the nature of which is not understood. Some investigators, Metchnikoff in particular, attribute natural immunity to phagocytosis (cellular hypothesis), others maintain that insus-

ceptibility to disease is a result of the antagonistic action of the body fluids (humoral hypothesis). Ehrlich's lateral chain theory assumes that the cells of immune animals are not capable of combining with the toxins of bacteria, i. e., they have no receptor molecules and hence those animals are not receptive, they are immune. Whether we accept the cellular hypothesis, the humoral hypothesis, or Ehrlich's lateral chain theory, the fact remains that natural immunity is a characteristic or property of parental origin that is transmitted to the offspring and is present at the time of birth.

Natural immunity may be the result of an acquired tolerance due to natural selection and heredity. There is a marked variation in susceptibility and resistance in individuals of a given species. A continuous or repeated exposure of susceptible animals to a given pathogenic microparasite will result either in



Fig. 59.—*Ixodes ricinus*, female, after (B. A. I.)

destruction of those animals or the production of an immunity, i. e., those individuals least resistant will survive and their resistance will become more and more fixed and will finally be transmitted to the offspring and hence be a natural immunity. Thus all native Cubans are practically immune to yellow fever because at the time yellow fever was first introduced into Cuba the least resistant individuals died of the malady, the most resistant individuals survived and lived in the presence of the disease almost continually after yellow fever was introduced into Cuba (It was not eliminated until after the Spanish-American war). Consequently the Cubans for several generations developed in the midst of yellow fever and only the resistant individuals survived. This resistance finally became so firm

that it was transmitted to their offspring and was then a natural immunity.

The resistance possessed by dogs to most diseases is explained in a similar way to the Cubans' resistance to yellow fever. Thus the dog has descended from the jackal and the wolf, two types of animals that have lived largely upon the carcasses of animals dead of various diseases. As the animals fed on carcasses they fought, thus inoculating each other, so in the beginning the least resistant individuals died, the more resis-

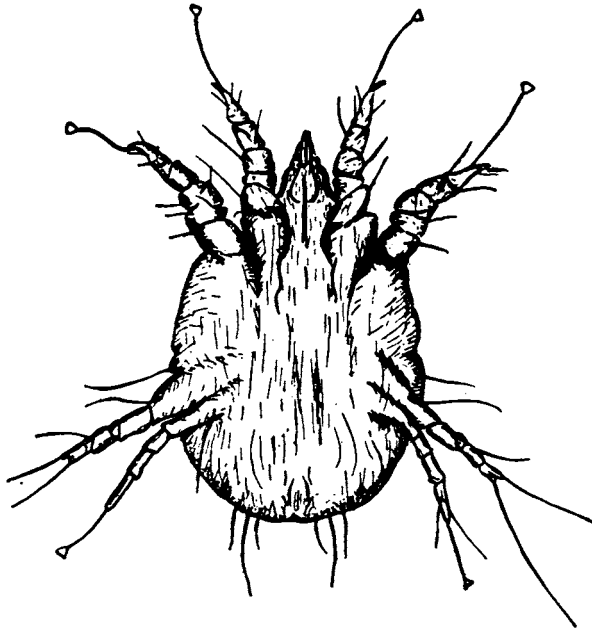


Fig. 60.—The scab mite of sheep, *Psoroptes Communis Ovis*, magnified 150 diameters.

tant animals survived. Thus the constant fighting and inoculating has established in them a firm resistance that is transmitted to their progeny as a natural immunity. This immunity has become so fixed that it does not vary even in the domestic dog. The above is a plausible explanation of race or species immunity. The exact origin of individual immunity is considered by some to be an acquired tolerance, i. e., an acquired immunity, and by others, as simply an individual resistance not developed by having the disease to which the given individual is immune.

Acquired immunity is an artificially produced condition by virtue of which the animal is capable of resisting disease, and

is produced in an animal either in utero or after birth, and may be active, or passive, bacterial or toxic.

Active acquired immunity is, no doubt, the result of cellular action and may be produced as follows:—

1. By an animal becoming infected and recovering from an attack of the disease, e. g. blackleg.

2. By inoculation of a susceptible animal with a small quantity of the virulent causative microparasites, thus producing the disease in a mild form. This is practiced in immunizing cattle against tick fever.

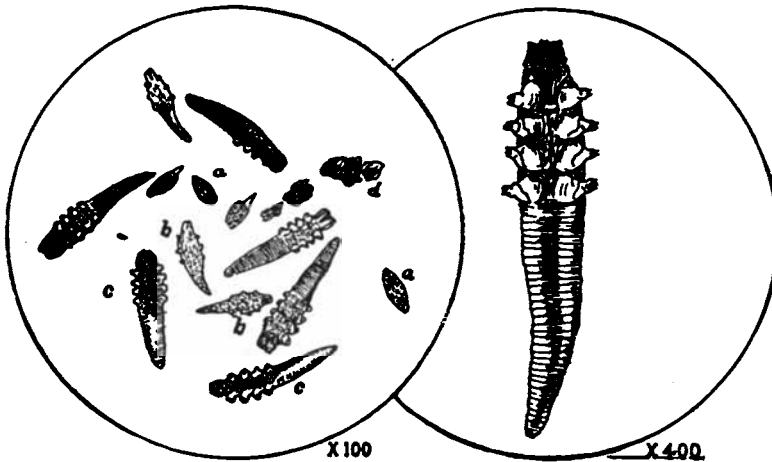


Fig. 61.—*Demodex Folliculorum*, variety *Canis*.
Field showing various stages of development.
a. Ova.
b. Pupa.
c. Adult.
d. A piece of Scab.

Fig. 61a.—*Demodex Folliculorum*, variety *Canis*.
Adult Male, magnified 400 times showing wide head, with rostrum, short legs (3 articles each) 2 claws and elongated body.

3. By inoculating a susceptible animal with an attenuated virus, (vaccine.) Horses, mules, cattle, and sheep are immunized to anthrax by a vaccine.

4. By repeated inoculations of a susceptible animal with small quantities of a toxin of a specific pathogenic microparasite, tetanus toxin or other active poison as snake venom. This method is used only in the production of antitoxins or in immunizing animals against zootoxins and phytotoxins.

5. By simultaneous inoculation with a virus and an antitoxin (antibodies, bactericidal substances, etc.) In the Philippine Islands this method is employed in immunizing cattle against rinderpest, and it is also being successfully used in the immunization of hogs, against cholera.

Toxic immunity is the resistance to poisonous substances as toxins of bacterial origin, zootoxins and phytotoxins. It is common to hear sheep herders speak of dogs that are immune to the venom of rattlesnakes. The dogs are bitten frequently while doing duty on the range and although the reaction from the first inoculation is intense and may even kill, each succeeding inoculation produces less reaction until finally the dogs may be bitten or the venom inoculated with impunity. Immunity to intoxication diseases such as tetanus are of this type. The absence of action of various therapeutic agents that have been given repeatedly may be explained on the principles similar to those involved in the production of immunity in dogs to snake venom. Toxic immunity is the result of the presence in the body fluids of an antibody (Antitoxin.)

Bacterial immunity is the resistance an infected animal manifests to the bacterial invader. It is the result of bacteriolytic substances in the body fluids. Pfeiffer demonstrated that bacteria are destroyed when introduced into an immune animal. He introduced the spirilla of Asiatic cholera into the peritoneal cavity of guinea pigs and noted that the bacteria were soon rendered immobile, became swollen and granular and were finally disintegrated. This phenomena has been designated Pfeiffer's reaction.

Passive acquired immunity consists essentially of the presence in the tissues or body fluids of substances inimical to micro-parasitic activity, or substances capable of union with micro-parasitic products, (toxins) thus rendering them inert. This type of immunity is of short duration. It is usually produced by the inoculation of susceptible animals with antitoxin. Injured animals inoculated with tetanus antitoxin at the time of injury are thus immunized to tetanus for a brief period.

Acquired immunity, like natural immunity, is variable and inconstant. The production of active acquired immunity entails more risk than the production of passive acquired immunity. The causative agents or their toxic products are used in obtaining an active immunity and thus disease may be produced and the animal life sacrificed while the anti-toxin is used in the production of a passive immunity, without danger of the production of disease although transient disturbances may result

from hemolysins, contained in the blood in which there is anti-toxin.

Theories of acquired immunity.—Many theories have been

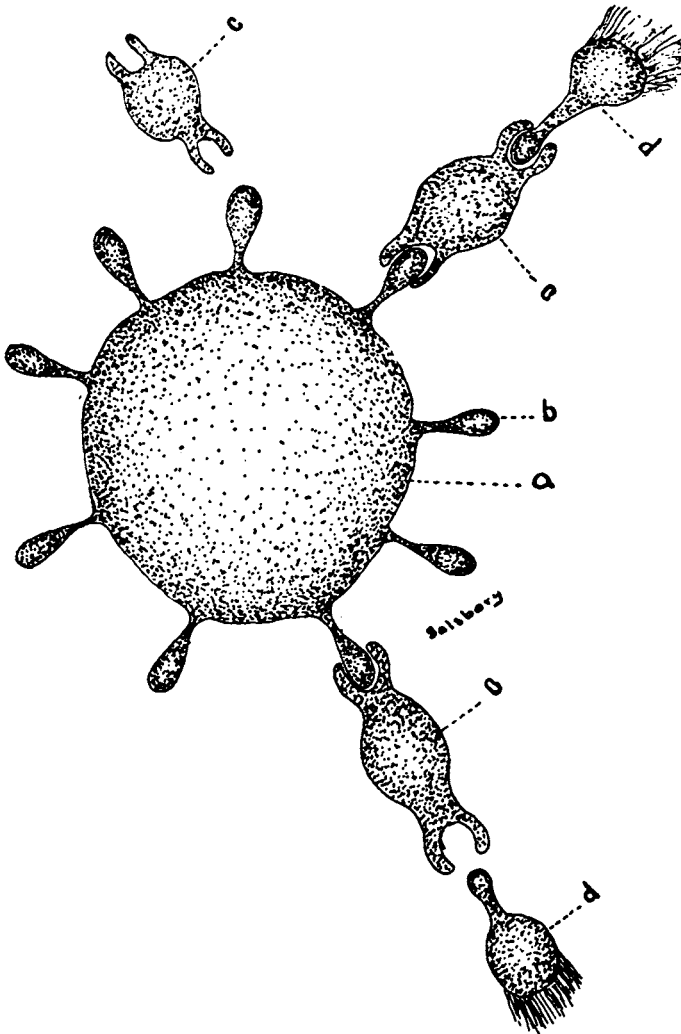


Fig. 62.—Bacterial Immunity.

- | | |
|-------------------|----------------|
| Legend— | c. Amboceptor. |
| a. Cell body. | o. Compliment |
| b. Cell receptor. | |

advanced in explanation of acquired immunity. The chief of which are as follows:—

1. *The Exhaustion Theory*.—This theory was championed by Pasteur, who proposed it about 1880. It is based upon the supposition that there are certain substances in the animal body that are food for micro-parasites and that these substances are not regenerated. Hence when they have been consumed the micro-parasites cease to develop and the animal becomes immune. This theory is not tenable because immunity can be produced by bacterial products and by dead bacteria neither of




Fig. 63.—*Hematoba serrata*, after Riley and Howard.
a. Egg. b. Larva. c. Pupa. d. Adult fly.

which consume substances from the tissues of an animal immunized.

2. *The Retention Theory*.—In the study of bacteriology it has been found that bacteria, like most other organisms, can not develop in the presence of a large quantity of their own excrements. This theory presupposes that bacterial products remain in a body after it has been infected and that these products prevent the future development of like bacteria. This theory does not explain the production of an immunity with toxins and is not supported by any scientists at the present time. The theory was proposed by Chauveau.

3. *The Phagocytosis Theory*.—This theory was proposed independently by Sternberg and Metchnikoff about 1881. The theory was the outgrowth of the experimental study of the action of leucocytes upon bacteria and yeast, in which it was

found that certain leucocytes are active in the destruction of various bacteria, yeast and tissue debris. These investigators designated those leucocytes active in the destruction of bacteria, phagocytes. Phagocytosis is a state or condition characterized by the development of phagocytes and the display of their special function. The supporters of this theory hold that the cells, which are active in the production of leucocytes transmit the property of phagocytosis to their progeny and thus immunity is perpetuated after it has been acquired. That phagocytes do incorporate bacteria and other foreign substances is not denied but it has not been demonstrated whether phagocytosis is the cause or the result of immunity.

This theory does not explain immunity from such diseases as tick fever. The microzoon of tick fever inhabits and usually destroys the red corpuscles. The leucocytes are probably not affected by them. In fact, the presence of the *Piroplasma bigeminum* in leucocytes has not been noted. More recently Wright and Douglas have demonstrated that certain substances in the blood serum are necessary to prepare bacteria for phagocytic action. These substances have been designated opsonins." Opsonins are chemic substances in blood serum that render bacteria subject to the action of phagocytes. Opsonins resemble the amboceptors of Ehrlich in action, but they are not identical with them. The action of opsonins is evidenced in pneumonia, pyogenic infections, tuberculosis and probably in other diseased conditions. The opsonic index indicates the relative power of resistance due to phagocytic action in an animal body.

4. *Humoral theory.*—After the phagocytic theory had been found insufficient, immunity was explained from a chemic view point. The supporters of this theory, among whom Buchner was active, demonstrated the bactericidal action of blood serum and lymph obtained from immune animals. Their demonstrations established the fact that immunity is due to a chemic substance, possibly an enzyme. But the origin and specific action of the chemicals in the production of immunity was not determined. The bacteriolytic substance of the body fluid called complement, was found to be destroyed by a temperature of 55°C.

5. *Ehrlich's Lateral Chain Theory.*—Ehrlich maintains that every living cell contains an active central body and an indefinite number of marginal chemic groups or lateral chains designated receptors. These receptors combine with and extend the nutriment to the central portion of the cell. The receptors are

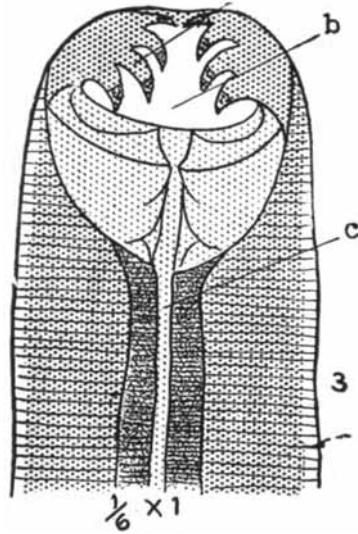


Fig. 64.—*Uncinaria Canina*. Cephalic extremity of female, magnified 350 diameters.
 a. Hooklets. b. Mouth cavity. c. Oesophagus.



Fig. 64a.

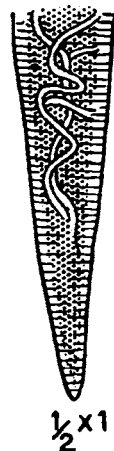


Fig. 64b.

Fig. 64a. Section of body of female, magnified 100 diameters, showing the ova to have formed in worm not to exceed five weeks old.
 a. Ovum. b. Intestine.

Fig. 64b. Caudal extremity of the female, magnified 100 diameters.

also capable of combination with other substances as bacterial toxins.

Toxic immunity is explained by Ehrlich as follows: Toxins are composed of two essential chemic groups which are desig-

nated haptophores and toxophores. The haptophore of the toxin has an affinity for the cell receptors. The union of the toxin haptophore and the cell receptor forms a medium through which the toxin toxophore passes to the central part of the cell where it exerts its action.

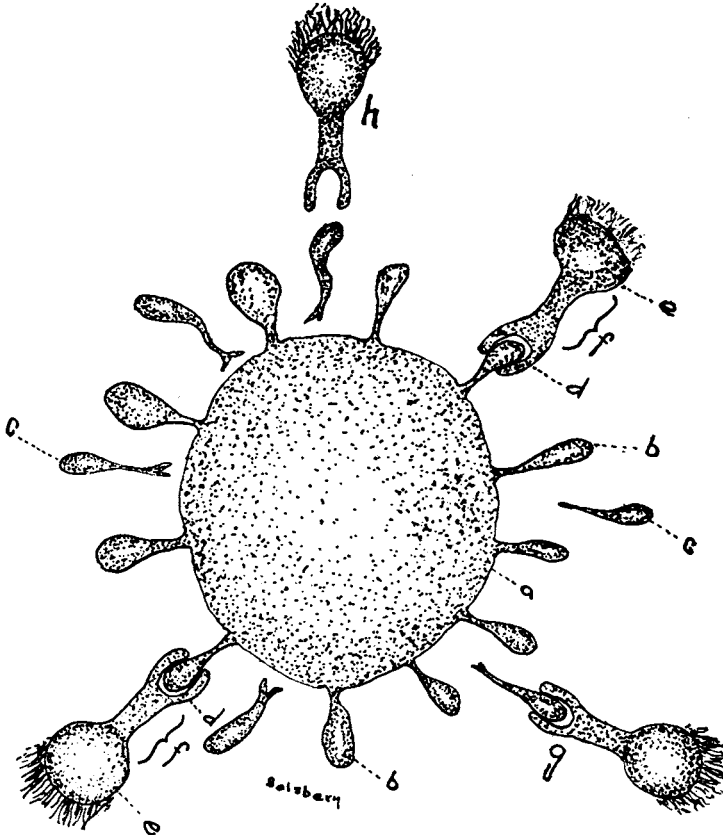


Fig. 65.—Toxic Immunity. A cell showing active central body and marginal chemic receptors, and toxin molecules surrounding it.

Legend—

- a. Cell body.
- b. Cell receptors.
- c. Free cell receptors.
- d. Haptophore of toxin molecule.
- e. Toxophore of toxin molecule.
- f. Toxin molecule.
- g. Toxin molecule combining with free cell-receptor.
- h. Toxin molecule floating free and about to combine with a free cell-receptor.

The toxin haptophores are not injurious except as they enable the destructive toxin toxophore to reach the central cell mass. Toxin toxophores in the absence of toxin haptophores are inac-

tive. The result of the union with, or action of, the toxin toxophore upon a cell may produce immediate destruction of the cell or it may stimulate the cell to produce more receptors. The presence of toxin in the body fluids stimulates the body cells to produce receptors in excess. The increased receptors may remain in connection with the central body or they may become detached and float in the body fluids. Free receptors in blood serum is the essential active principle of antitoxin. Toxic immunity may be better understood by giving an example.

Example.—Tetanus is an intoxication disease due to the production of toxins by localized bacterial activity of the tetanus bacillus. Immunity to tetanus is dependent upon the neutralization of the tetanus toxin. The tetanus toxin is composed of haptophores and toxophores. The body cells possess receptors capable of union with the tetanus toxin haptophores. The union of cell receptors and tetanus toxin haptophores enables the tetanus toxin toxophore to act upon the central mass of the body cell, thus stimulating them to form more receptors. The excess receptors become detached and float free in the body fluids and combine with the tetanus toxin haptophore, thus preventing the latter from combining with the attached cell receptors. The tetanus toxophores are not capable of combining with the central mass of the body cells except through the medium of tetanus toxin haptophores and if the tetanus toxin haptophores are locked up with the detached cell receptors, the tetanus toxophores remain inactive and the animal is not inconvenienced by their presence and is immune.

Toxic immunity is therefore dependent upon first, sufficient free receptors to lock up the haptophores thus inhibiting the action of the toxophore or second, upon the absence of haptophores.

Bacterial immunity.—From the phenomena observed in Pfeiffer's reaction Ehrlich has proposed an hypothesis in explanation of bacterial immunity. As previously stated, normal blood serum contains bacteriolytic substances (see humoral theory). Complements are destroyed by a temperature of 55°C. The blood serum of immune animals possess another substance, in addition to complement, not destroyed, by heating to 55°C. These are called amboceptors. According to Ehrlich, amboceptors, like toxins, are composed of two different combining groups, also designated haptophores and toxophores. The complemental substance of normal serum is not capable of action upon bacteria. The amboceptor haptophore has an affinity for the complement of normal serum. The amboceptor toxophore has an affinity only for bac-

teria, but is not injurious to them. The amboceptor toxophore combined with or acting upon bacteria produces a condition favorable for the action of the combined amboceptor haptophore and complement, i. e., this enables the complement to cause disintegration of bacteria. The amboceptor thus renders conditions favorable, i. e., makes it possible for the bacteriolytic substance, the complement, to exert destructive action upon bacteria, the amboceptor acting as middle man.

CHAPTER IV.

MALFORMATIONS.

DEFINITION.

ETIOLOGY.

Intrinsic (heredity.)

Extrinsic.

Pressure.

Amniotic Adhesion.

Excessive Motion.

Malnutrition.

CLASSES.

Single.

Result of Arrested Development.

Result of Excessive Development.

Result of Transposed Visceral Organs.

Result of Persistent Foetal Structures.

Result of Mixed Sexual Organs.

Double or Multiple.

Symmetrical Duplicities.

Complete (twins).

Incomplete (double monster).

Asymmetrical Duplicities.

Multiple.

During the embryonic stage of intra-uterine life the specialized tissues and organs are formed. The foetal period is the time during which the structures formed in the embryonic stage grow and develop. At birth the young of a given species are of a definite shape, contour and type; the form or type which is most common is accepted as normal; and deviations from the normal are designated malformations, anomalies or developmental errors. Many new strains and breeds of stock have been the result of developmental errors becoming a fixed peculiarity. Thus the polled cattle, the Boston bull-dog, the Mexican (hairless) dog, and the five toed chicken had their origin.

Etiology.—Malformations may be brought about by pre-existing influences in the maternal cells, (internal or intrinsic causes), or from external influences (external or extrinsic causes).

Internal or Intrinsic Causes.—Internal causes are inherited peculiarities, i e., heredity and atavismal influences. These are probably not the usual causes of malformation in domestic animals for malformed individuals are rarely used for breeding purposes.

External or Extrinsic Causes of malformations are pressure, amniotic adhesions, excessive motion, insufficient or abnormal nutri-

tion, infectious diseases, etc. External causes exert their influence during the embryonic or formative period and they must act in a mild degree or death of the embryo and abortion follows.

Typical malformations are approximately of the same form and are usually produced by similar causes. Atypical malformations are variable in form and may be produced by a variety of causes.

A complete description of all malformations is beyond the scope of general pathology. A general classification with a description and origin of the most striking malformations is all that will be attempted in this chapter.

Malformations may be divided into two classes; 1st, Single malformations, and 2nd, Double or multiple malformations.

Single malformations are those affecting a single individual. Single malformations may be grouped into five classes as follows: Malformations resulting from; (a) arrested growth or development; (b) excessive growth or development; (c) transposition of visceral organs; (d) persistent foetal structures; (e) mixture of sexual organs.

ARRESTED DEVELOPMENT.—Malformations caused by arrested development may involve an entire individual or any part of an individual. Arrested development of the entire individual results in the formation of an irregular, fleshy mass, called a mole, in place of the normal foetus. Moles may be carried in the uterus for the entire period of gestation. In some instances a mole and a normal foetus may be delivered at the same time. Moles have been observed in mares, more rarely in cows.

Malformations resulting from arrested development of a part may be manifested by the entire absence of the part (aplasia), by underdevelopment of the part, (hypoplasia), or by a lack of union or fusion of tissue (schistosis and atresia). The following malformations are the result of local aplasia.

Acephalus. A name applied to a headless monstrosity. Acephalus is probably the result of amniotic adhesions.

Atrichia. A defect in which there is no hair. This results from some disturbance of cutaneous development.

Amyelus. A malformation in which the spinal cord is absent. Defects of the primitive streak or failure of production of the neural canal interferes with or prohibits the formation of the spinal cord and is the cause of amyelus.

Acardia. A heartless monstrosity.

Agastria. A malformation in which the affected individual

has no stomach. This may be due to lack of sacculatation of the embryonic gut.

Acaudia. A malformed individual in which the defect consists in the absence of the tail. An acaudia fox terrier bitch was recently observed, her mother whelped one or two tailless puppies at each whelping. This bitch recently whelped an acaudiac puppy.

Aprosopus. An individual having no face.

Agnathus. A term used to designate an individual in which the inferior maxilla is absent. This is common in lambs.

Amelus. The name of a limbless or legless individual. Amelus is the result of arrested development of leg buds and is usually caused by unequal intrauterine pressure or amniotic adhesions.

Monopygusamelus. A monstrosity in which one posterior leg is wanting. This is due to arrested development of leg buds, probably due to amniotic adhesions.

Dipygusamelus. The name of a malformed animal in which both posterior legs are absent. Result of arrested development of leg buds.

Monothoracisamelus and *dithoracisamelus* are monstrosities in which one and both front legs are absent respectively.

Apus. A name applied to a malformation in which the feet are absent. This may be the result of intrauterine amputation or amniotic adhesions.

Monopygusapus is an individual in which one hind foot is wanting and a *dipygusapus*, an individual in which both hind feet are absent.

Monothoracisapus, and *dithoracisapus*, are names implying the absence of one or both front feet.

The following malformations are the result of under development or undergrowth. (Hypoplasia).

Microcephalus, a term used to designate an individual having a diminished sized head, also used to designate the small head itself. This is probably the result of diminished nutrition to the head and anterior part of the body during embryonic and foetal development.

Micro-cardia. A name applied to an individual having a small heart. This may be due to excessive pressure.

Microphthalmia. A term used to indicate a malformation in which the eye or eyes are smaller in size than the normal. This is probably the result of insufficient nutrition.

Micrognathy. The name of an individual having a diminutive inferior maxilla. These are caused by undue pressure or insufficient nutrition.

Micromelus. A malformation so named because of the diminished size of all legs. This is caused either by diminished nutrition or undue pressure.

The following are illustrations of arrested development manifested by absence of imperfect tissue union, thus producing fissures (schistoses), or resulting in fusion of parts that are normally separate (synactoses). Fissures of the body cavities are due to increased accumulation of fluids in internal organs, increased size of internal organs, prolapse of viscera before body walls have united, the presence of amniotic folds between cleft edges or lack of sufficient tissues to close the margins.

Cranioschisis. The name of a condition produced by failure of development and union of the cranial bones and resulting in a cleft. The meninges and in some instances the brain tissue may be exposed or there may be protusion of the meninges and also of the nerve tissue, thus producing meningocele or meningo-encephalocele.

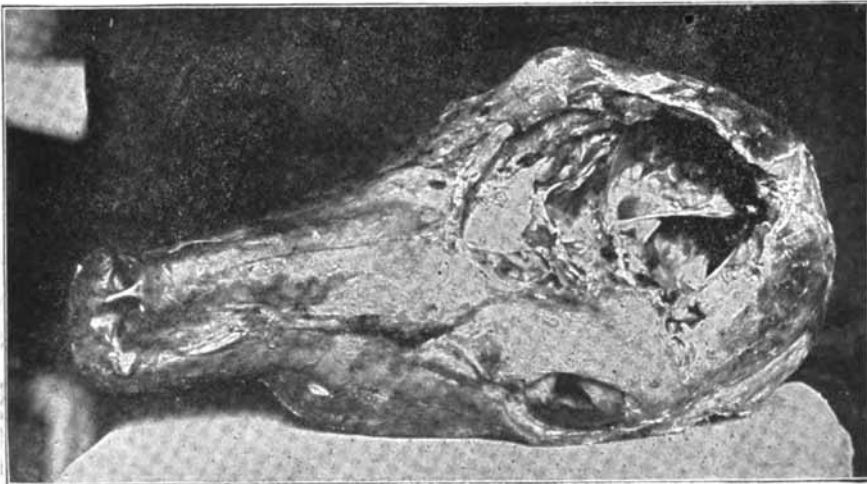


Fig. 66.—Cranioschisis—Calf.

Craniorrhachischisis. A malformed individual so called because of a fissure of the spine and cranium accompanied by exposure or protusion of the spinal cord and brain.

Rhachischisis. A condition in which there is a cleft of the spinal column. This malformation is usually the result of some defect in the margins of the neural groove. If the fissure extends the entire length of the spinal column the resulting condition is called holoschisis. If the fissure does not extend the

entire length of the spinal column, the condition is termed meroschisis (Gr. Meros=part, and schisis=splitting.) The spinal meninges may protrude through the spinal column fissure producing spina-bifida. A hernia of the spinal meninx that contains cerebrospinal fluid is termed spinal meningocele, and if the cord and meninges protrude, it is called a myelomeningocele.

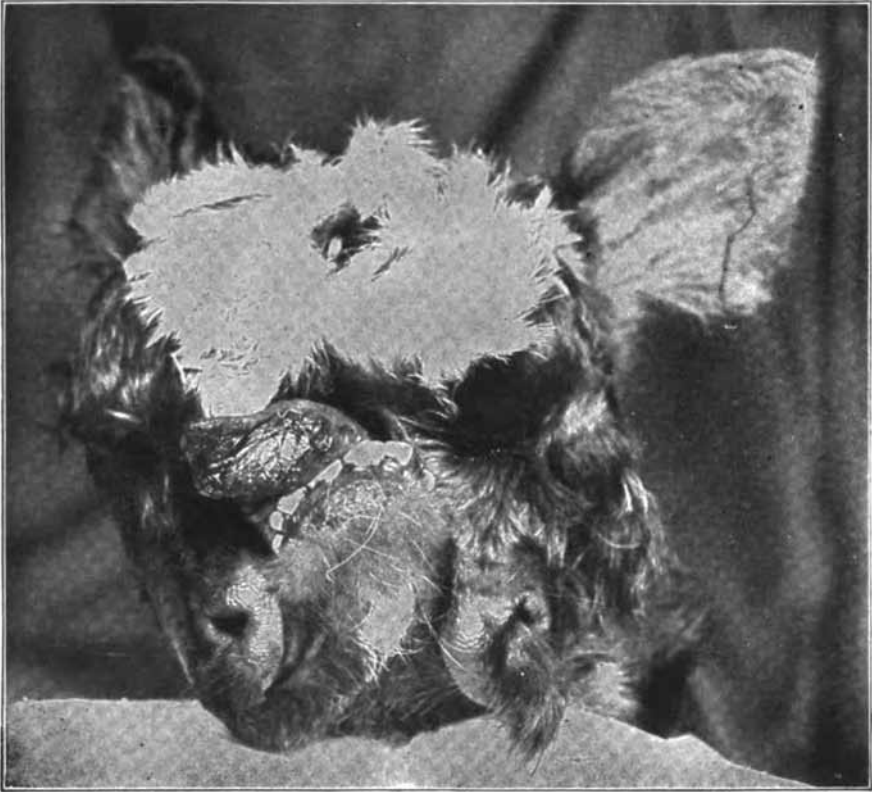

Fig. 67.—*Cheiloschisis.*

Cheiloschisis. is the condition resulting from arrested development of the soft tissues covering the maxilla. This is the condition popularly termed hair lip. It is an inconvenience because it interferes with sucking the teat, the source of nutrient of the new born mammal. The defect may also involve the maxilla producing cheiliognathoschisis.

Palatoschisis. A defect in which the palatine processes have imperfectly developed, thus leaving a fissure through which

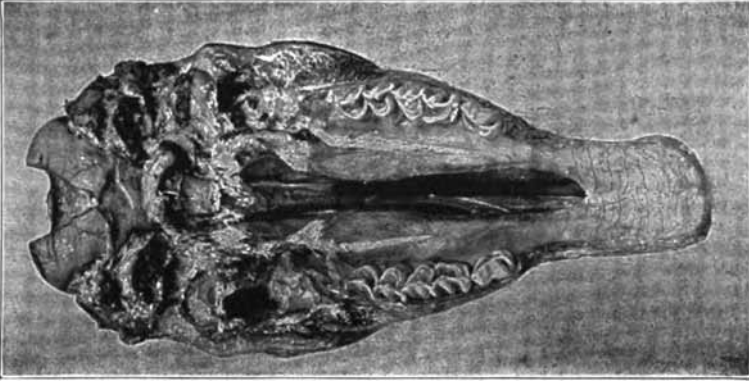


Fig. 68.—*Palatoschisis*.

there is free communication between the nasal and buccal cavities. This condition is commonly spoken of as cleft palate.

Thoracoschisis. A condition resulting from failure of union of the thoracic walls. The thoracic viscera, the lung, heart and




Fig. 69.—*Abdominoschisis*.

large vessels may protrude through the fissure thus producing ectopiacordis or ectopiacordispulmonaris.

Abdominoschisis, is the condition caused by failure of union of the abdominal parieties. The condition is frequently accompanied by protusion of the abdominal viscera through the fissure. The abdominal fissure may involve only a portion of the cavity or it may be complete. Ectopia gastrum is the condition resulting from protrusion of the stomach through an abdominal fissure; ectopia vesicae, protrusion of bladder, etc.

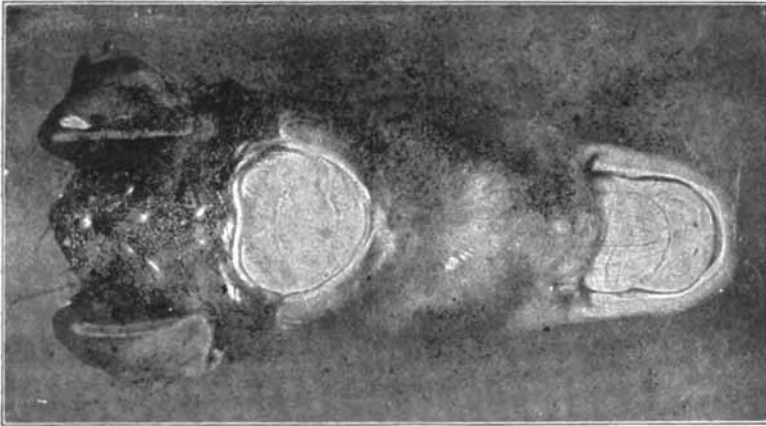


Fig. 70.—Synophthalmia or Cyclopia.

Synophthalmia, or *cyclopia* (Gr. Kuklops= mythical single eye monster), is a condition resulting from the fusion of the optical vesicles. Arrested development of the anterior cerebral vesicles allows the optical vesicles to contact and in some instances there is one large double eye centrally located or there may be two eyes occurring in a centrally located orbit. Cyclopia is usually associated with defects of the nose.

Synactosis, is a general term denoting a condition caused by the fusion of parts or organs that are normally separate.

Synmelus. A malformation caused by the fusion of two legs into one irregular member.

Syndactylus. An individual having the digits fused or grown together. An illustration of syndactylism is the soliped hog. The soliped hog usually has two separate digits of three phalanges each and the ossa pedes are encased in a single hoof.

Synmelusdipus. A malformation having fused legs and two feet.

Symmelusmonopus. An individual having fused legs and only one foot.

Symclusapus. A monster having fused legs and no feet.

Synorchism. A malformed animal in which the testicles are fused.

Arrested development may be evidenced by the nonappearance of the lumen in any of the natural hollow organs, (atresia). The mouth is formed by an ingrowth of the ectoderm and the buccal cavity extends inward until it meets the anterior elongation of the embryonic gut. Later the partition separating the buccal cavity and the cavity of the embryonic gut is absorbed

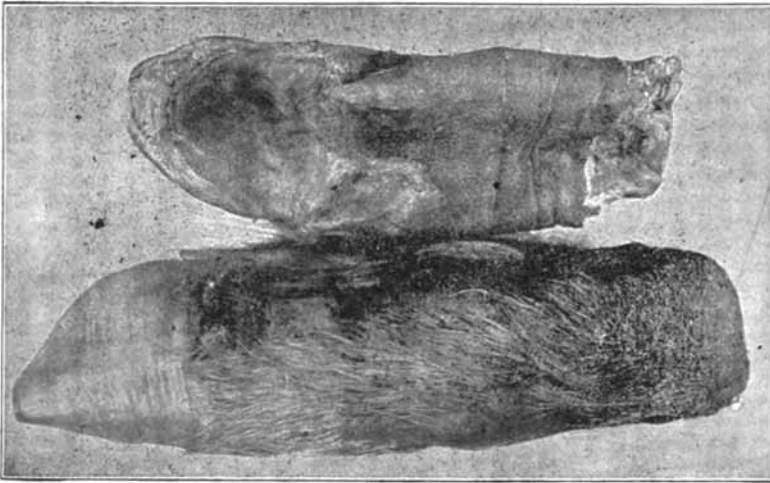


Fig. 71.—A condition of *Solipedia* in a hog.

and thus the cavities become continuous. Failure of the extension of the mouth cavity and its fusion with the embryonic gut constitutes the condition. *Atresia Oris.*

Atresia iridis. A defect in the eye due to the absence of an opening (pupil).

Atresia oculi, a malformation in which there is no opening between the eyelids.

Atresia anus is a condition in which there is an imperforate anus, that is, there has been failure of union and fusion of the anal ingrowth and the rectal outgrowth. *Atresia anus* is of rather frequent occurrence and usually the defect is easily relieved.

Atresia urethra. Imperforation of the urethra.

MALFORMATIONS RESULTING FROM EXCESSIVE DEVELOPMENT OR OVERGROWTH.—Excessive development is usually evidenced as a multiplicity of digits or phalanges though there may be multiplicity of any structure.

Polydactylism.—The name applied to a malformed individual in which there is an excessive number of digits. Individuals having supernumerary digits are frequently observed. The condition is probably more frequently observed in hogs than in other animals. Polydactylism, however, occurs occasionally in the ox and horse.

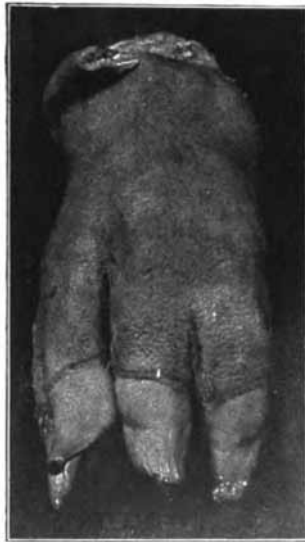

Fig. 72.—Polydactylism in a hog.

Polymelusthoracicus.—This is a malformation in which the affected animal has one or more extra front legs. An interesting case was observed in a cow in which there was an irregular bone attached to the right scapula, and extending across the median line. This bone articulated with an irregular supernumerary scapula and also with the spine of the left scapula. This irregular formed scapula articulated with another bone which was similar to a humerus on the distal end of which there was a rudimentary ulnar. The condition of supernumerary posterior legs is termed polymeluspygus.

Dicaudis.—An individual having two tails. This type of malformation is not very common. It is probably the result of



Fig. 73.—**Prognathism**, common name "undershot."

a division or cleavage of the caudal segments during embryonic formation.

Multiplicity of internal organs is occasionally observed. Thus several cases of partially double spleens have been reported. An interesting case of malformation was observed in a hog, the defect

consisting of a double penis. This individual may have been called a dipenis.

Malformations from excessive growth may be applied to the entire animal when it is excessively large (giants). Malformations resulting from overgrowth of a part are frequent; thus one foot, one leg, the head or any other part may be overgrown. Darwin, (in *Plants and Animals under Domestication*), mentions a cat that he observed which had incisor teeth one and one half inches in length.

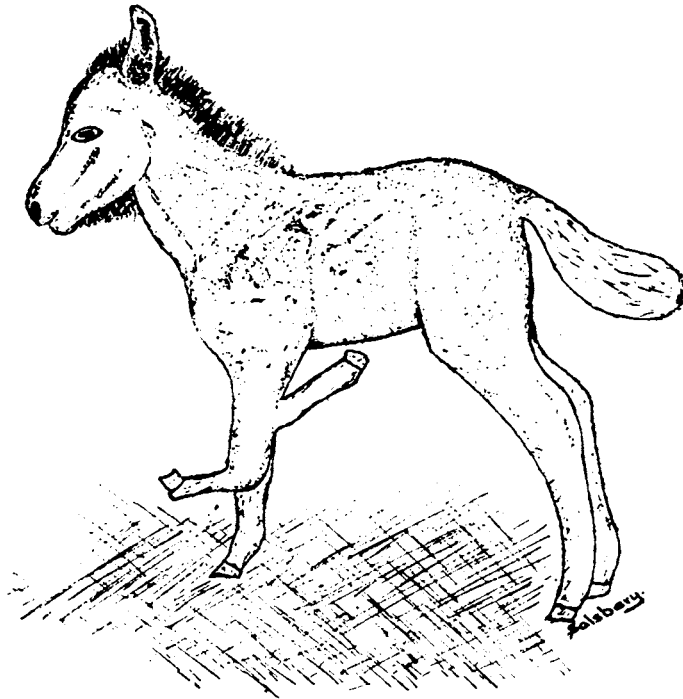


Fig. 74.—*Schistocelus melus anticus* or *dimelus anticus*—Male.
(Drawing made from a photograph.)

TRANSPOSITION OF VISCERAL ORGANS, (*situs viscerum inversus*). Very rarely animals are observed in which the visceral organs are re-arranged, i. e., those organs that normally occur on the left side of the body are found on the right side. A sheep in prime condition was observed which was normal in appearance except its head was turned slightly to the left and the atlas was ankylosed to the occipital, thus giving it but little vertical motion. The right shoulder was anterior to the left. The viscera were entirely reversed; the heart was hanging toward the

right: the four compartments of the stomach were transposed, the rumen being on the right side, and the spleen being in contact with the right side of the diaphragm; the liver was on the left side and the right kidney was posterior to the left which was swinging free as the right usually does.

Transposition of visceral organs probably results from an irregularity of the allantoic veins and their continuation. In normal development the right vein atrophies and the left vein becomes larger in early embryonic life and if for any reason the left vein atrophies and the right vein becomes longer then the visceral organs tend to develop in the reverse position.

PERSISTENT FOETAL STRUCTURES.—All the malformations are grouped into this class that retain embryonic or foetal structures abnormal to extra-uterine forms of life.

Cryptorchids—(Gr. *Kruptein*—to hide and *orchis*-testicle) are probably the most frequent malformations resulting from the persistence of a foetal structure. The testicles of domestic animals are formed within the abdominal cavity during embryonic life and later migrate, except in fowls, birds, etc., to their permanent position in the scrotum. Cryptorchids are animals in which the testicle was properly formed, but did not descend to the scrotum. Dr. DeWolf carefully inspected 4671 male hogs and found 28 single and 7 double cryptorchids.

Cloacal Persistence.—During embryonic life the rectum and urogenital tract terminate in one common cavity known as the cloaca. The cloaca persists throughout life in the aroidae, but not in mammalia. H. Brassy Edwards, M. R. C. V. S., reported a case in the veterinary Journal of an imperforate anus in a brindle bull bitch pup 10 days old. There was no trace of an anus and the prominence usually felt in the perineal region of imperforate anus was also absent. On operation the rectum and uterus were found to be fused, thus producing a cloaca. Dr. P. Phillipson of Holbrook, Nebr., reported a colt in which there was a cloacal formation. In this case the floating colon fused with the uterus and the vagina was a common opening of the digestive tract and the genito-urinary tract.

Cervical ectopia cordis.—This is the name of a malformation in which the heart is located in the cervical region. The heart is normally formed in the cervical region and if the anterior thoracic wall closes prematurely, the heart remains in that region.

MIXTURE OF SEXUAL ORGANS, HERMAPHRODITISM.—The sexual glands, ovaries and testicles, and the external genitals, of both

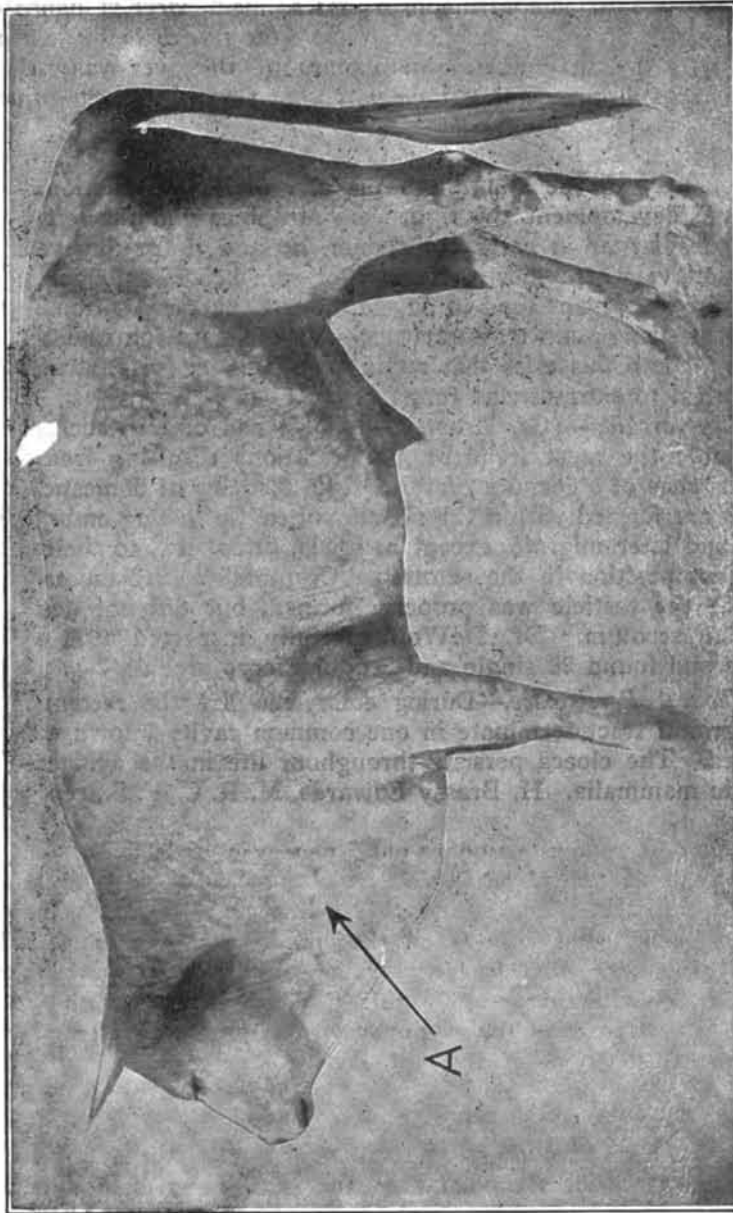


Fig. 75—Ectocardia.

sexes, are derived from four similar embryonic structures. The influence or factors determining sex are not known. During embryonic development the sexual determination is not distinct,

the individual possessing more or less complete sexual organs typical of both the male and the female. Animals in which there is a combination of sexual organs are termed hermaphrodites. According to the development of sexual organs, hermaphrodites are designated as true and pseudo or false hermaphrodites.

A true hermaphrodite possesses secreting sexual glands of both sexes, i. e., they have secreting ovarian and testicular tissues. The external genitals of the true hermaphrodite may be bisexual or unisexual. True hermaphrodites are rare, and fertility of such animals is doubtful. True hermaphroditism may be lateral, bilateral or unilateral.

Lateral hermaphroditism is the condition in which there is an ovary on one side and a testicle on the other. The following example illustrates this type. The animal was a two year old bovine and had an ovary suspended by the left broad ligament and a testicle suspended by the right broad ligament. The two glands had their normal appearance, typical of ovarian and testicular tissues. This type of hermaphroditism is rare.

Bilateral hermaphroditism is typified by the presence on both sides of an ovary and a testicle, or a single organ on each side containing ovarian and testicular tissues. This type of hermaphroditism, also is rare.

Unilateral hermaphroditism is characterized by the presence of a single organ, as an ovary or testicle on one side and an ovary and testicle on the other side or an organ containing ovarian and testicular tissue on one side. This type is not common.

Pseudo or false hermaphrodites are individuals having one distinct type of sexual glandular tissue and in which the external genitals partake of the nature of both sexes. This type of malformation is more common in the male and is usually the result of persistence of Müller's canal and the further development of the uterus and Fallopian tubes. In pseudohermaphroditism the testicles are usually retained in the abdominal cavity. There are usually Fallopian tubes, vagina and uterus, the completeness of which is variable. The appearance of the testicle is variable according to the development of the female external genitals. Pseudohermaphroditism is much less frequent in the female than in the male.

A rather well marked case of a pseudohermaphroditic horse was obtained and carefully observed for some time after which it was destroyed and the type and relation of the sexual organs were determined by dissection. In this animal the head and neck while not decisive of either sex in general rather favored

the male in conformation. There was quite a well marked vulva and the much elongated clitoris projected about four inches postero-inferiorly and closely resembled a penis. The uterus was quite rudimentary and the reproductive glands were located near the normal location of the internal inguinal ring and had very little resemblance to either testicle or ovary. Microscopic examination did not solve the difficulty for the glands were a conglomerate of small cysts. The mammary gland was fairly well developed.

Double or Multiple Malformations.—Under this caption those malformations will be considered that involve two or more individuals developing simultaneously. Marchand's classification of duplicate monsters is adhered to in the following discussion. The entire subject of duplicate monsters may be subdivided into 1st, symmetrical duplicity, 2nd, asymmetrical duplicity, and 3rd, multiplicity.

SYMMETRICAL DUPLICITY.—The individuals, in symmetrical duplicity are, in the beginning, similar and symmetrical. Each of the symmetrical duplicates is derived from separate, similar, equal anlagen of a single fertilized ovum or bisection of a single anlagen. This class of malformations may be divided into two groups:—viz., complete and incomplete duplicities.

Complete Duplicity.—Complete duplicates are in the beginning alike and complete and the individuals may remain separate thus forming twins, (free duplicities,) or they may be united, thus forming double monsters.

Twins, (free duplicates), develop in a single chorion though each individual usually has a separate amnion and allantois. Monochorionic duplicates may develop equally or unequally, depending upon the division of nourishment. The above discussion primarily applies to uniparous animals. However, by varying the number it is equally applicable to multipares. Twins also result from simultaneous fertilization of two ova.

Double monsters are mono-chorionic duplicities in which the bodies are united. The two bodies may be equal or unequal in size, depending upon the distribution of nourishment. Double monsters are the result of partial fission of a fertilized ovum, partial fusion of two separate anlagen of a single ovum, or partial fusion of two fertilized ova. The attachment of the two bodies of the double monsters may be posterior, middle or anterior.

Posterior union may be dorsal or ventral. In the former the union occurs at the pelvis, and the dorsal surfaces of the bodies are usually in apposition, such a monster is called a pygopagus.

Pygopagi have two umbilical cords which fuse to form a single cord; coccyx and sacrum are single, rectum and anus usually single; spinal cord double anteriorly, fused posteriorly forming a single filum terminale; urogenital system usually double. Ventral posterior union may be confined to the pelvic region, (ischiopagus), or it may extend anteriorly to and including the thoracic cavity, (thoracischiopagus). The two bodies in ventral posterior union are so united that their venter surfaces are in apposition. Ischiopagi, usually have a single umbilicus and cord; pelvic organs may be single or multiple; there is usually no anus. If one of the bodies is small or rudimentary, it is designated a parasite, (ischiopagusparasiticus). Thoracischiopagi, may have single or double thoracic viscera; the abdominal viscera are usually double.

Middle union in double monsters occurs on the venter surface from the umbilicus and extends anteriorly. There is usually a single umbilicus; the abdominal viscera is usually double; thoracic viscera single or double, depending upon the area of union; middle union may occur at the xiphoid cartilage, (xiphopagus), involve the entire sternum, (sternopagus), or the entire thoracic venter surface, (thoracopagus), xiphopagi may survive, the "Siamese Twins," were of this type. Thoracopagi are frequently unequal in size, the smaller one being designated as a parasite.

Anterior union may be dorsal or ventral or the union may be on the anterior surface of the head. Dorsal, anterior union rarely occurs, the attachment being on the frontal region. These malformations are designated Craniopagi. Ventral anterior union occurs occasionally. The union in this type is along the venter cervical region and extends onto the venter thoracic region. The sternum and oesophagus are single; larynx, trachea and stomach may be single or double; intestine double; there may be two faces or the faces may be fused. Fused-face monsters resulting from union of the venter anterior cervical or cephalic regions are called syncephali.

Incomplete Duplicity is the name applied to those malformations in which the greater part of the body is single, duplication occurring in only a part. The duplicity may involve any part. These malformations are not easily differentiated from malformations resulting from multiplicity of parts as polydactylism.

ASYMMETRICAL DUPLICITY are those malformations resulting from the development of two separate, dissimilar, unequal anlagen of a single ovum, the development of a fertilized polar



Fig. 76.—Dicephalic Calf.

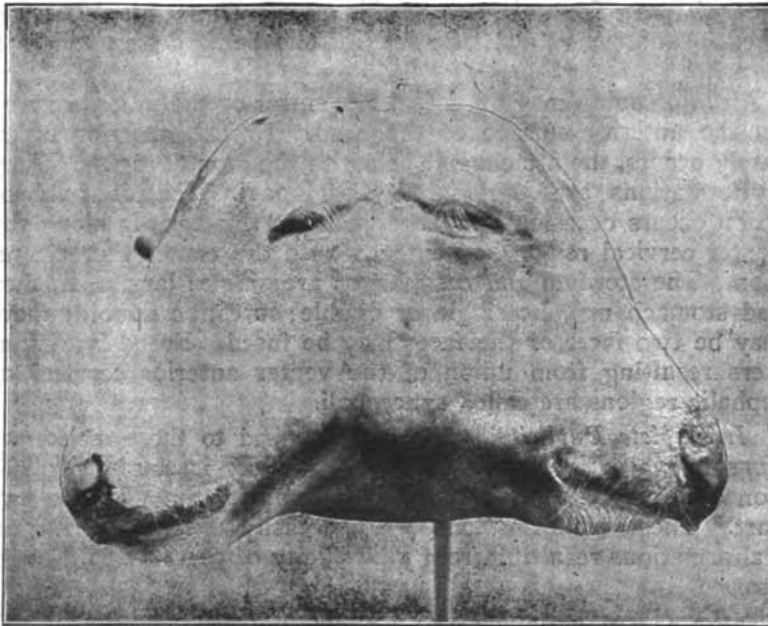


Fig. 77.—Dicephalic Calf.

body or the development of an isolated group of segmentation cells. In asymmetrical duplicity one body is rudimentary or under-developed, (the parasite), and the other body develops normally or nearly so, (the autosite). The parasite always remains attached to the autosite or is included by it. Parasitic duplicity may occur in any region. Thus the parasite may project from the orbit, mouth, shoulder or it may be included in the thoracic or abdominal cavities.

MULTIPLICITY is the name applied to designate the development of more than two separate individuals in a single chorion. Multiplicity is of rare occurrence. One single case has been authentically reported in the human in the form of a tricephalus.

CHAPTER V.

CIRCULATORY DISTURBANCES.

Normal blood circulation is dependent upon the rate, rhythm and force of the heart, the caliber of the blood vessels and the resistance offered by them and the quantity and the quality of the blood.

Variation of Heart Action.—A marked variation in the heart activity results in imperfect circulation. *Depressed or diminished* heart action is more common than increased heart action. Diminished functional activity is most frequently caused by inflammation of the endocardium, myocardium, epicardium or pericardium. Valvular stenosis and valvular insufficiency are the result of endocarditis. Myocarditis diminishes the activity of the heart and if the inflammation is long continued the muscle cells are destroyed and replaced by fibrous tissue thus permanently impairing the force of the heart. Inflammation of the epicardium and pericardium may be accompanied by voluminous exudation which distends the pericardial sac and produces sufficient pressure to hinder diastole, or the exudate may become coagulated and later organized attaching the sac to the surface of the heart and thus hindering cardiac systole. Cardiac activity may be diminished by the collection of fluid in the pleural cavity, malformed thoracic cavity, tumors, occlusion of coronary arteries, fatigue and thrombic formation upon the cardiac valves. Diminished cardiac activity results in a diminished quantity of blood being sent out from the heart and an accumulation of waste products in the tissues.

Increased functional activity of the heart is usually only temporary excepting in those animals affected with cardiac compensatory hypertrophy. The most common cause of increased cardiac activity is reflex stimulation. Increased activity due to reflex stimulation may terminate in exhaustion and syncope in a relatively short time. Increased functional activity, due to a cardiac compensatory hypertrophy resulting from increased resistance as in emphysema, chronic nephritis, etc., may result in permanent over action of the heart.

Anatomical changes in the cardiac-structure, as hypertrophy, fatty degeneration, fragmentation, fibrous formation, or necrosis

may be evident when the functional activity of the heart is varied.

Vascular Variations.—The amount of blood passing into or out of a given organ is determined by the caliber of the blood vessels, provided the heart action and general blood pressure remain normal. Variations in the caliber of normal blood vessels depend primarily upon the response of the vessel musculature to vaso-motor stimulation. Blood pressure is dependent upon the elasticity of the arteries and the force of the heart. In general, pathologic vascular variations are the result of, first, disturbed arterial elasticity; second, the maintenance of the normal caliber of the vessels and; third, the permeability of the vascular walls.

Arteriosclerosis is a condition in which the elasticity of the vessel walls is lessened or destroyed. In the production of arteriosclerosis there is vascular dilatation succeeded by subendothelial fibrous formation which continues until the lumen of the dilated vessel is reduced to its normal size. The hyperplastic fibrous tissue may later become calcified. Sclerotic arteries are thick, stiff and nonelastic. Sclerosis is most common in arteries although it occurs in veins.

The vascular caliber may be diminished by muscular contraction or by hypertrophied vessel walls. In animals affected with chronic nephritis there is contraction of the systemic arteries resulting in compensatory cardiac hypertrophy. Arterial constriction is also common in the peripheral vessels of animals affected with carbon dioxide poisoning. Local diminution of vascular caliber may be produced by parietal thrombi. The vascular caliber may be increased by paralysis of the vaso-motor nerves a condition which is sometimes observed in animals that have received injuries in the cervical region.

Increased permeability of vessel walls usually results from insufficient nutriment to the vascular structures and occurs most frequently in small vessels, i. e., capillaries and venules. Increased permeability usually accompanies venous hyperemia although it may exist independent of variations in the quantity of blood. Thus oedema is common in hydremic individuals.

Variations in Quantity and Quality of Blood.—The quantity of blood in a part is determined by the caliber of the supplying vessel and by the blood pressure. Acute general anemia results in a diminished blood pressure which, if not corrected in a short time, terminates fatally. Chronic general anemia is accompanied by a slightly diminished blood pressure and a retarded blood current.

The most important variations in the quality of blood that concerns the student of general pathology are due to the variations of the percentage of water contained. Hydremia is accompanied by disturbances of the renal function and by oedema. Anhydremia is productive of a slow weak pulse and the secondary changes resulting therefrom. Excess of carbon dioxide or urea in the blood stimulates the vaso-constrictor nerves thus causing arterial contraction.

Hemorrhagic diathesis or hemophilia is an inherited condition in which there is little or no tendency for coagulation of blood. The cause of this condition is the absence of some blood constituent essential to coagulation.

HEMORRHAGE.

DEFINITION.

ETIOLOGY.

- Ruptured vessel.*
- Rhexis or diabrosis.*
- Increased permeability.*
- Diapedesis.*
- Predisposition (hemophilia).*

VARIETIES.

Location.

Tissue.

- Petechia (flea bite) pin point.*
- Ecchymosis (over-flow) from pin point to size of dime.*
- Suggillation (swelling) bruise.*
- Effusion.*
- Hematoma (blood tumor).*
- Infarction.*
- Surface—Skin, mucous, membrane, serous membrane.*
- Epistaxis.*
- Hematemesis.*
- Hemoptysis.*
- Hematuria.*
- Hematidrosis.*
- Hematometra.*
- Hematocoele.*
- Metrorrhagia.*
- Hemathorax.*
- Hemocoelia, etc.*

Vessels.

- Cardium.*
- Arteries.*
- Veins.*
- Capillaries.*

APPEARANCE.

- Macroscopic.*
- Microscopic.*
- Tissue hemorrhage.*
- Clot.*

EFFECTS.

- Rate of outflow.*
- Location.*
- Secondary change of extravasate.*

Hemorrhage is the escape of blood from a vessel, (capillary, vein, artery or heart.)

Etiology.—Some animals are predisposed to hemorrhage (hemophilia). Hemorrhagic diathesis or hemophilia is an inherited condition in which there is little or no tendency for coagulation of blood. The cause of this condition is the absence of some blood constituent essential to coagulation or rupture of vessel wall, resulting from diseased vessels as ulceration, thus producing hemorrhage by *diaprosis*, or in

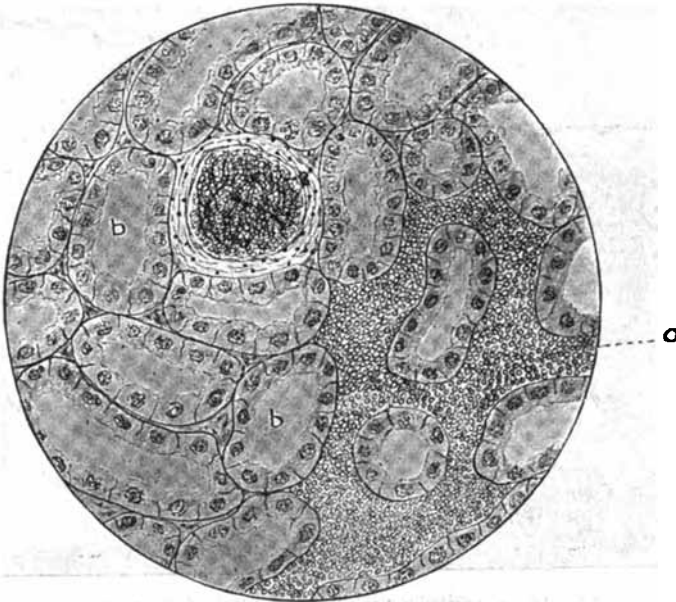


Fig. 78.—Petechial hemorrhage, Kidney hog cholera lesion.

- a. Hemorrhagic area. c. Glomerulus engorged with blood.
b. Normal kidney tubule.

creased pressure and traumatism, thus producing hemorrhage by *rhexis*. The permeability of the vessel walls may be sufficiently increased by pressure or disease so that hemorrhage takes place by *diapedesis*. The escaped blood, i. e., the extravasate, may flow upon the surface of the skin, serous or mucous membranes, or into the tissues.

TISSUE HEMORRHAGES may vary greatly in amount and are designated by the following terms, petechia, ecchymosis, sugillation, effusion, infarction and hematoma.

Petechiae are small sharply defined hemorrhagic points and are probably caused by bacterial products in the blood.

Ecchymoses are hemorrhagic spots larger than petechiae and less sharply defined caused by ruptured capillaries or precapillaries.

Suggillations and effusions are large indefinable hemorrhagic areas, caused by bruising which ruptures the small vessels.

Hemorrhagic infarction is a hemorrhage into an anemic area. This is not a hemorrhage as ordinarily understood for the blood is

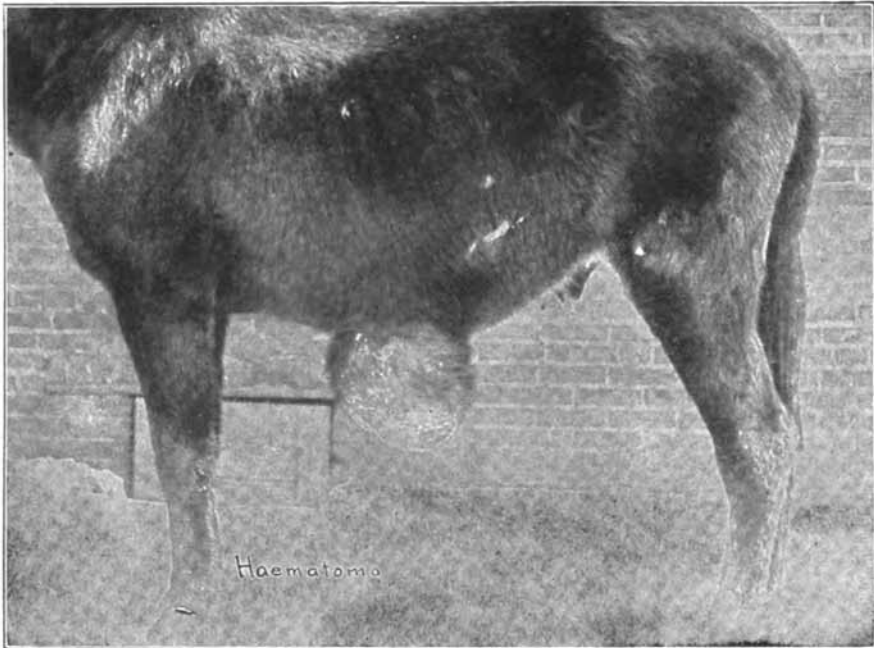


FIG. 79.—*Hematoma*, caused by rupture of spur vein.

within the vessels and escapes into the anemic area because of the diminished pressure.

A *hematoma* is a circumscribed collection of extravasated blood in the tissues and is usually the result of hemorrhage from an artery.

SURFACE HEMORRHAGE is designated according to its origin, thus:

Epistaxis is hemorrhage from the nasal mucous membrane and is quite common in acute nasal glanders.

Hematemesis is hemorrhage from the stomach and is observed in animals poisoned with arsenic and those afflicted with gastric ulcer or gastric carcinoma.

Hemoptysis is hemorrhage from the lungs. It may be the result of excessive exertion, abscess formation, tuberculosis, etc.

Hematuria is hemorrhage into the urinary tract or bloody urine. The blood may escape from the kidney, and if so there will be tubular casts discernible on microscopic examination of the urine; it may come from the ureter or bladder, and would then be thoroughly mixed with the urine; or it may have its origin from the urethra and would not be mixed with the urine but would usually precede it.

Hematidrosis is hemorrhage from the surface of the skin and is the so-called sweating of the blood and is caused by increased permeability of cutaneous capillaries.

Enterorrhagia is hemorrhage from the intestinal mucosa and may be differentiated from hematemesis by the appearance of the extravasate in the feces. The extravasate in hematemesis has the appearance of coffee bean grains in the feces while the enterorrhagia extravasate retains the hemoglobin color and is not broken up into granules. (The coffee bean appearance of blood extravasated into the stomach is due to the action of the hydrochloric acid of the gastric juice.) Enterorrhagia is caused by infection as in anthrax and by caustics.

Hematometra is hemorrhage from the uterine mucosa, the extravasate being almost entirely retained in the uterus. This is usually caused by improper removal of retained placenta.

Metrorrhagia is hemorrhage from the uterine mucosa and the extravasate passes out of the uterus. Menstruation in the human is an illustration of metrorrhagia.

Hemocoelia is hemorrhage into the peritoneal cavity and is caused by rupture of the peritoneum or some abdominal organ.

Hemothorax is hemorrhage in the pleural cavity, and is caused by ruptured pleura as a result of fracture of a rib, etc.

Hematocoele is hemorrhage into the tunica vaginalis cavity. This may be the result of laceration or rupture of the tunica vaginalis testis.

Effects.—The effects of a hemorrhage depend upon the quantity of blood lost and the location and secondary changes of the extravasate. In health the vascular system practically maintains a constant blood pressure by accommodating the capacity of the blood channels to the volume of the blood.

The quantity of blood that an animal may lose without being seriously affected varies according to its age and health.

The blood tissue of the horse has been estimated at from 1-16 to 1-12 of the total body weight. One-tenth of the estimated total amount of blood in the body has been withdrawn from horses used in the production of anti-toxin once every two weeks for from six to eight months without injurious results.

From $\frac{1}{4}$ to $\frac{1}{2}$ of the volume of the blood in the body may be withdrawn at once and the animal recover. Hemorrhage from a small vessel has little effect upon the welfare of the body for the quantity lost is immediately restored from the lymph and other fluids of the body. Thus there may be a constant hemorrhage from the digital artery of the horse for twenty-four hours without injurious consequences.

A sudden large loss of blood diminishes blood pressure and this results in imperfect action of the heart valves. The blood is churned back and forth, becomes mixed with air and this frothy mass accumulates beneath the valves and prevents their closure.

Hemorrhage is serious when it occurs in the more delicate or the more highly organized tissues. Thus the amount of extravasate into the cerebrum may be very small and yet produce sufficient disturbance to destroy life, while the same amount of extravasate into the muscles of the thigh, forearm, etc., would probably not be observed.

The extravasation of blood into one of the body cavities, as the pleural or peritoneal cavity, will be partially absorbed as entire blood before it becomes coagulated, the remaining unabsorbed portion will be in part disintegrated and carried out by the leucocytes and the remaining portion will finally become organized and remain as a mass of fibrous tissue. If the loss of blood is not sufficiently large to materially diminish the blood pressure and the extravasate remains free from infection there will be very little inconvenience from the hemorrhage; but if the extravasate becomes infected the outcome will be more serious. If the extravasate is into some important tissue the secondary changes will be of more consequence than when in the body cavities.

There is a natural tendency for self arrest of hemorrhage, because, 1st, blood pressure is diminished during hemorrhage and thus coagulation is favored; 2nd, the endothelium of the injured vessels becomes roughened and thus thrombic formation is favored; and 3rd, fibrinogen is liberated from vascular endothelium and thus the coagulation of the blood is favored.

LYMPHORRHAGIA.

DEFINITION.*(Extent of lymphatic system).**(Lymph transdate quantity determined by blood pressure).***ETIOLOGY.***Ruptured vessel or space.***LOCATION.***Surface, because of lymph spaces and low pressure.**Thoracic duct.***APPEARANCE.***Macroscopic.**Microscopic.***EFFECTS.**

Lymphorrhagia is the escape of lymph from ruptured lymphatic vessels. The lymphatic system in general is the connecting system between the blood capillaries and the jugular vein. In this system lymph is that portion of the blood which passes, through (or is secreted by), the capillary walls into the perivascular spaces and consists of plasma diluted, leucocytes, and usually contains considerable waste material. Lymph varies in its composition depending upon the source, location and condition of the surrounding tissue. The lymph of the lacteal system depends upon the kind of food-material digested and the length of time since its ingestion.

Etiology.—Lymphorrhagia is the result of laceration or rupture of the lymphatic channels. Because of the low pressure within the lymphatic vessels, lymphorrhagia takes place only upon surfaces or into the body cavities. Lymphorrhagia onto a surface, if long continued, results in the so-called lymphatic fistula. Rupture of the abdominal portion of the thoracic duct accompanied by the escape of its contents into the peritoneal cavity produces the condition known as chylous ascites.

Chylous ascites is differentiated from abdominal dropsy or ascites proper by examination of the accumulated fluid. The fluid of chylous ascites and lacteal fluid are practically identical in composition. Ascitic fluid proper is diluted lymph and contains no evidence of chyle or lacteal fluid. Lymphorrhagia may also occur into the pleural cavity as a result of the rupture of the thoracic portion of the thoracic duct.

The effects of lymphorrhagia depend upon the extent, location and length of duration of the process. Extensive lymphorrhagia from a large lymphatic vessel depletes the body because of the loss of food substances, albumin, etc., in the lymph. Lymphorrhagia from the thoracic duct, especially into the peritoneal cavity, is serious because of the loss of food.

OEDEMA, DROPSY OR HYDROPS.

DEFINITION.

ETIOLOGY.—

- Increased production.*
- Increased permeability (Cohnheim.)*
- Increased pressure.*

OBSTRUCTED OUTFLOW.

- Valvular insufficiency or stenosis (cardiac).*
- Gravid uterus.*
- Tumor, Abscess, Ligature, etc.*

LOCATION.

- Peritoneal cavity (ascites).*
- Thoracic cavity (hydrothorax).*
- Pericardial cavity (hydropericardium).*
- Arachnoid space (hydrocephalus external).*
- Lateral ventricles (hydrocephalus internal).*
- Tunica vaginalis cavity (hydrocele).*
- Subcutaneous lymph spaces (anasarca) (in legs only, stocking).*

APPEARANCE.

- Macroscopic.*
- Microscopic.*

EFFECTS.

Oedema, dropsy or hydrops is the accumulation and retention of lymph in the lymph vessels and spaces. Lymph is the conveyor of metabolic substances to and from all tissues of the body except those directly supplied by the blood capillaries. The quantity of lymph in the lymphatic channels is determined by the permeability of the capillary walls and the rapidity of lymphatic absorption. In health there is a balance between the transudation of lymph from the blood vessels and its absorption into the lymph vessels. In oedema there is either a larger amount of lymph transuded or a smaller amount absorbed.

Etiology.—The causes of oedema may be:

1. *Increased transudation* which may be caused by (A) Increased permeability (or secretory function) of the capillary walls, thus allowing an increased amount of fluid to escape from the blood. (B) Hyperemia: which produces an increased intracapillary pressure resulting in sufficient injury to the endothelial lining to allow an increased outflow of plasma. Passive hyperemia is more frequently associated with oedema than active hyperemia. Thus, tricuspid stenosis or tricuspid insufficiency is usually associated with general dropsy. "Stocking" is an oedema usually resulting from venous hyperemia.

2. *Obstructed outflow of lymph.* Swollen lymphatic glands, the result of inflammatory disturbances or neoplasms, and

external pressure hinder the passage of lymph and hence favor its accumulation. As the anastomoses of lymph channels is quite complete the obstruction of the outflow of lymph is a minor cause.

Varieties of oedema according to location are as follows:—



Fig. 80.—Dog with *Ascites*, a result of an hepatic tumor.

Ascites: an abnormal accumulation of an oedematous fluid in the peritoneal cavity usually resulting from obstructed portal circulation.

Hydrothorax, and abnormal accumulation of oedematous fluid in the pleural cavity or cavities. It is usually unilateral in the horse and is caused by obstruction of the internal thoracic vein.

Hydropericardium; and abnormal accumulation of oedematous fluid in the pericardial sac. This variety is very rare as a primary condition. It is caused from venous obstruction of cardiac vessels or vessels of the cardiac sac.

Hydrocele: an abnormal accumulation of an oedematous fluid within the vaginal tunic, e. g., the so called “water seed”, caused by adhesion of the vaginal tunic in the inguinal canal which is usually the result of improper castration.

Hydrocephalus: an abnormal accumulation of oedematous fluid in the serous cavities of the brain or its meninges caused by venous hyperemia. Thus external hydrocephalus is an

affection of the subarachnoidean spaces and internal hydrocephalus an affection of the ventricles of the brain.

Anasarca: an abnormal accumulation of oedematous fluid in the subcutaneous areolar tissue.




Fig. 81.—Subcutaneous Oedema, caused by valvular insufficiency.

Appearance. *Macroscopic.*—Oedema of the body cavities results in their distention and in the displacement of the normal cavity contents as a result of the accumulated fluid. The serous membrane becomes discolored. Oedematous fluid is thin, water-like, pale yellow, or colorless, contains less albumin and is less coagulable than either blood serum or inflammatory exudate. An oedematous tissue is swollen, flabby, soft and pits upon

pressure, and if incised, a watery, pale straw colored fluid escapes.

Microscopic.—The intercellular spaces are increased in extent, hence the cells are farther apart than normal and may be undergoing degeneration or atrophy, or be swollen and contain vacuoles.

Effects.—The effects of oedema vary according to the causative agent, the tissue involved, and the length of duration of the process. If the etiologic factor is capable of reproducing or increasing in quantity, as infectious agents (Bacillus of Malignant Oedema), there is more extensive tissue destruction than when the oedema is produced by other agents. Oedema of the meninges of the brain or spinal cord may result in degeneration and destruction of the nerve cells and death of the diseased animal. On the other hand oedema of the subcutaneous tissues of the metacarpal or metatarsal region is of little consequence. Oedema of brief duration does not, as a rule, produce permanent injury to the involved tissue, but an oedema of long standing is of serious consequence because of the extensive hydropic infiltrations of the cells of the affected tissue and because of the constant depletion of the system. Hydropic degeneration, thrombosis and necrosis are frequent sequellae of oedema.

THROMBOSIS.

DEFINITION.

ETIOLOGY.

- Injured endothelium.*
- Mechanical—Artery forceps.*
- Atheromatous degeneration.*
- Insufficient nutrition.*
- Foreign bodies—Parasites, etc.*
- Retarded rate of blood flow.*
- Increased coagulability of blood.*

PROCESS OF FORMATION.

LOCATION.

- Occurs in all vessels, more prevalent in veins and heart.*

VARIETIES OF THROMBI.

- Color.*
- Red.*
- White.*
- Mixed.*
- Extent.*
- Partial.*
- Lateral.*
- Parietal (annular).*
- Complete (obstructive).*

EXTENSION OF THROMBI.

APPEARANCE.

SECONDARY CHANGES OF THROMBI.

- Decolorization.*
- Softening.*
- Simple.*
- Infective.*
- Organization.*
- Calcification.*

EFFECTS DEPEND UPON.

- Vessels obstructed.*
- Secondary changes of thrombi.*

Thrombosis is the condition resulting from a coagulation of blood within the vessels or heart during life. A thrombus is the coagulated blood within a living vessel. The accumulation and adhesion of leucocytes on the interior of vascular channels is also spoken of as a thrombus. The term thrombus should not be confused with a coagulum or a clot. A coagulum is coagulated blood within a vessel formed after death of the vessel wall, and a clot is coagulated blood formed outside of the vessel.

Thrombosis is of quite common occurrence. It is occasionally a sequel of parturition. Thrombic formation of one or both of the iliac arteries of the horse is a demonstrated cause of lameness. Thrombo-embolic colic of the horse is caused by thrombosis of the anterior mesenteric artery. The appearance of ante-mortem clot is familiar to all post-mortem examination observers. Intravenous or intra-arterial injections are probably always succeeded by thrombic formation at the

point of the injection, but the thrombi resulting therefrom are usually of little consequence.

Etiology.—The coagulation of blood is a complex chemical reaction and is not thoroughly understood. From the various investigations it may be concluded that three factors are essential in the coagulation of blood. 1st. There must be soluble albumins from which fibrin is derived. 2nd. Fibrin ferment (fibrinogen) which is probably derived from leucocytes and blood plates. (It is probable that vascular endothelium may also liberate fibrinogen.) 3rd. Soluble lime salts. The following are the most frequent immediate causes of thrombic formation.

1. *Injury of the vascular endothelium* which may be caused by: (A) Mechanical interference, as torsion by artery forceps, or ligation; (B) Extension of disease from other portions of vessel walls, as atheromatous degeneration; (C) Insufficient nutrition the result of passive hyperemia; (D) Foreign bodies. Thrombic formation succeeding injury of the vascular endothelium is apparently a reaction on the part of the injured cells for protection and to prevent hemorrhage until the wound is repaired. Many thrombi are thus formed and later removed by phagocytes, without causing sufficient inconvenience to be clinically recognized.

2. *Retarded flow of blood* which may be caused by a weak heart or the relaxation of the blood vessels especially the veins. Frequently the so called "ante-mortem clot", which is a thrombus, is observed in post-mortem examination of horses that have died of pneumonia, pleurisy, peritonitis and other exhaustive diseases that are accompanied by a weak heart action.

3. *Variations in the composition of blood*, as increased number of platelets, which increase its coagulability, (probably because of the production of fibrinogen), contamination with bacteria, etc.

Process of Formation.—The process of formation varies according to the kind of thrombus formed. A red thrombus is formed when there is vascular obstruction and it is formed because of the coagulation of the blood contained in the obstructed vessel. Coagulation in thrombic formation does not differ from extravascular coagulation. White thrombi are formed as a result of leucocytic adhesion, and the deposition of the fibrin from the blood plasma on an injured internal vascular surface. The leucocytes and fibrin may continue to accumulate until the vessel is obstructed.

Location.—Thrombi form in the heart, veins, arteries, and

capillaries. They occur more frequently in the heart and veins because of the presence of valves.

Varieties of Thrombi.—Thrombi may be classified on the basis of color and extent:

1. *Color.* Thrombi are variable in color according to their structure and may be red, white or mixed. A thrombus formed in a vessel in which there is complete stasis of blood will occupy practically the entire vessel-lumen and be red. On the other hand a thrombus formed gradually by the deposition of fibrin upon a roughened endothelial surface of a blood vessel will be white. A mixed thrombus may be formed as a result of blood-stasis in a vessel in which there was a white thrombus, or by a red thrombus becoming partially detached from the vessel wall and contracting, thus allowing the blood to pass through the partially obstructed vessel and depositing fibrin (a white thrombus) upon the red thrombus.

2. *Extent.* A thrombus may be complete or obstructive, i. e., occupy the entire lumen of the vessels, or it may be partial. A partial thrombus may be lateral, i. e., be found along one side of a vessel. It may also be parietal, i. e., extend around the entire lumen of a vessel.

Extension of Thrombi.—A thrombus may form as a plug in a vessel or may extend a considerable distance in the vessel, the extension usually being in the direction of the blood stream. Thus a bicuspid valve thrombus may extend, by continued deposit, out into the posterior aorta until it has reached the iliac arteries, or a thrombus arising in the metatarsal region may extend up through the metatarsal and continuing veins until it reaches the posterior vena cava. The extension may be the result of direct growth or deposit upon the original thrombus or it may be the result of fragments becoming detached (emboli) and floating in the blood stream until they arrive at the junction of blood vessels too small to allow them to pass and so form secondary thrombi or produce embolism.

Appearance of Thrombi.—*Macroscopic.*—A red thrombus appears similar to a blood clot but is usually a little more dense. It is red, jelly-like and quite easily broken and may be partial or complete. A mixed thrombus is practically the same as the red except in color. A white thrombus is usually a little more brittle than the red, is yellowish white in color and if formed at different periods, strata may be observed.

Microscopic. A red thrombus is practically identical with a blood clot, i. e., it is composed of fibrin in which white and red

blood cells are entangled. A white thrombus consists essentially of a mass of fibrin in which an occasional leucocyte or platelet may be found.

Secondary Changes of Thrombi.—1. *Decolorization.* A red thrombus may become decolorized as a result of degenerative changes in the red blood cells. The contained hemoglobin be-




Fig. 32.—A Thrombus from the posterior aorta of a horse also a section of the posterior vena cava of a cow containing a thrombus.

ing liberated may in part be converted into other pigments and in part may be carried away by invading leucocytes.

Softening. Thrombi, either red or white, are sometimes degenerated, disintegrated, absorbed and carried away as a result of the following:

(A) Simple softening is a noninfective, degenerative process that begins in the center of the thrombic mass and consists of albuminous, granular or fatty degeneration. The specific cause of the degeneration is not known but is no doubt the result of ferments. The degeneration extends from the center until the entire thrombus is involved. The disinte-

grated material may be carried away by leucocytes or may pass into the blood stream.

(B) Infective softening is an infective degenerative process, the result of bacterial invasion into the thrombus. The source of bacteria, that infect thrombi, is usually from the blood or lymph. Suppuration or liquefaction is the resulting change.

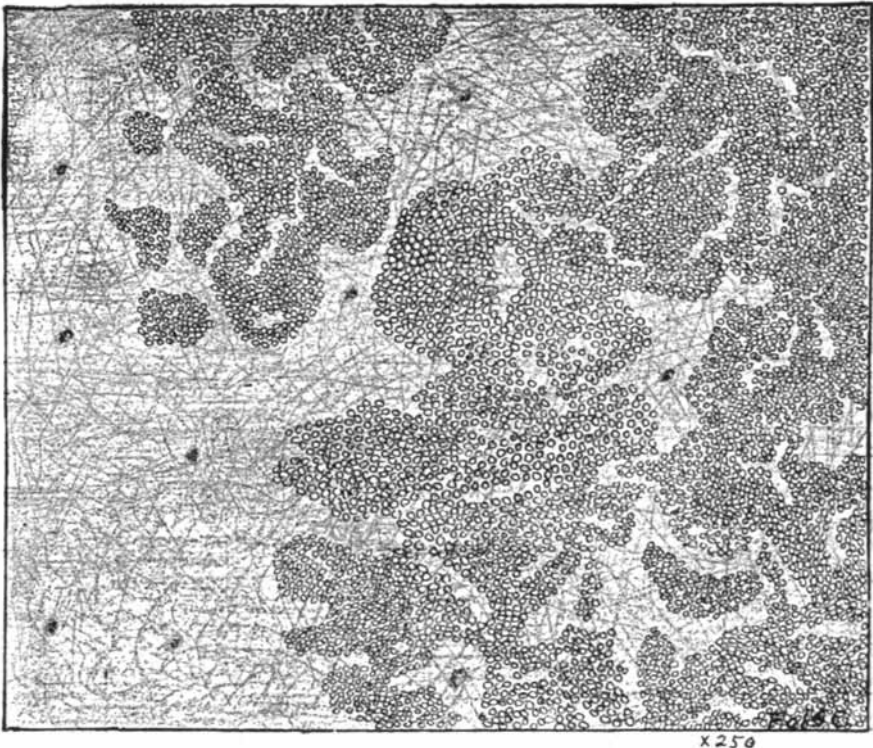


Fig. 83.—Red Thrombus, showing the fibrin, red cells and leucocytes.

The removal of the degenerative products may be accomplished either by the blood stream or by the leucocytes. The outcome of infective softening is likely to be much more serious than when simple softening occurs.

3. *Organization.* If the thrombus does not undergo degeneration it usually becomes organized, but it may become calcified. Very soon after a thrombus is formed the fibrin contracts as it does in the blood clot, thus reducing the size of the thrombus, and if it was a complete or occluding thrombus the reduction may be sufficient to allow the circulation to be re-

established. The endothelium and the vasa vasorum of the contacting vessel proliferate and extend into the thrombus soon after the fibrin contracts, the vasa vasorum usually being of sufficient extent to produce complete vascularization of the thrombus. The proliferated endothelial cells become fibrous connective tissue cells and produce fibrous connective tissue which later contracts and thus reduces the size of the thrombus. The dead and disintegrated tissue in the thrombus is carried away by leucocytes, thus reducing the size of the thrombus still more. The contraction of the fibers usually continues until there is a mere cicatrix where there once existed an occluding thrombus. (This is a favorable termination.) The organization may result in the formation of an excessive amount of fibrous tissue which may practically occlude the vessel, and the vessel itself become a fibrous cord.

4. *Calcification of the thrombi* in the human is quite common, the calcified thrombi being called phleboliths and arterioliths, according to the vessel in which they occur. The same changes occur in thrombi of lower animals.

Effects --The effects of thrombi depend upon the vessel in which it occurs and the nature of the thrombus. If it occurs in a terminal vessel the outcome will be different than if it occurs in a vessel having collateral branches. If the thrombus is occluding the outcome will be different than if it is parietal. A thrombus that is brittle or is easily detached will produce different results than one that is not easily broken and is adherent to the vessel wall. The general condition of the vessel wall is also a determining factor on the subsequent changes of a thrombus. The principle results are as follows:

1. *Obstructed circulation*, which may be either partial or complete, depending upon the nature of the thrombus and of the vessel and the rapidity with which collateral circulation is established. Continued partial obstruction in veins favors hyperemia with its consequent oedema. Degeneration in arteries favors anemia and atrophy. Complete obstruction results in necrosis with or without formation of infarcts.

2. *Production of embolism* by fragments becoming detached and occluding smaller vessels.

3. *Formation of new blood vessels.*

EMBOLISM.

DEFINITION.

SOURCE OF EMBOLI.

*Thrombic fragments.**Cells, fat, leukemia, tumor, etc.**Parasites.**Air.*

LOCATION, where vessels branch.

EFFECTS.

Embolism is a condition resulting from an obstruction of a blood vessel by a foreign body (embolus) that is suspended in the blood and is too large to pass through the vessel. An embolus is a foreign body in the blood such as air, sarcoma cells, etc.

Source of Emboli.—*Thrombic fragments.*—Fragments from disintegrating thrombi float in the blood until they arrive at vessels that are too small to allow them to pass and there becoming impacted produce embolism. An entire thrombus may also become detached and float in the blood stream as an embolus which, when impacted, would produce embolism. A thrombus in an artery usually extends back to, and sometimes beyond the first branch, the projection frequently becoming loosened and carried into the branch as an embolus.

Abnormal cells.—Leukemia is frequently accompanied by leukemic infarcts, a result of plugging of vessels by the enlarged leucocytes or leukemic cells. Metastatic sarcomata are the result of sarcomatous cells floating in the blood and becoming impacted in small vessels where they multiply, thus producing secondary tumors. Fat cells are a frequent cause of embolism especially in the human, after a fracture of a long bone in which the blood vessels are lacerated and fat cells from the marrow enter the blood stream.

Parasites.—Embolism may be the result of animal parasites. The *Strongylus armatus*, in the larval stage is found in the blood vessels of the horse and frequently produces aneurisms of the anterior mesenteric artery. Here a thrombus forms, the fragments of which passing on as emboli thus produce obstructions in the intestinal vessels which may result in thrombo-embolic colic.

Vegetable microorganisms may cause embolism, thus bacteria in the blood are emboli. Pyemia result from metastases of pyogenic organisms and pus. Apoplectic anthrax in sheep may be the result of emboli of *Bacillus anthracis* plugging the cerebral capillaries thus producing embolism.

Air may act as an embolus and obstruct small vessels, or it

may become mixed with the blood and become entangled in the cardiac valves, thus interfering with heart action (a horse was destroyed in four minutes by injecting air into the jugular vein).

Location.—Embolism occurs most frequently in arteries and in the portal circulatory system. Venous emboli as a rule pass to the right side of the heart and into the pulmonary arteries where they lodge. Fragments of thrombi from intestinal veins pass into the portal system and are lodged in the hepatic capillaries thus producing embolism. Thrombic fragments from

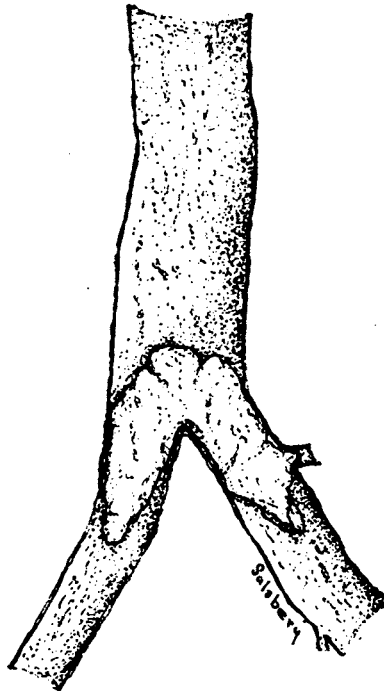


Fig. 84.—Embolism. The embolus lodged at the point of division of an artery.

the pulmonary veins, bicuspid valve and semi-lunar valves pass into the aorta and through its various branches and terminals as emboli and finally they occlude the containing vessel and thus produce embolism. Paradoxical embolism is the name applied to the condition resulting from obstruction of an artery with an embolus derived from the venous system and which has passed from the right side of the heart to the left through the foramen ovale.

In some rare instances it appears that an embolus travels in the direction opposite to the flow of blood and produces obstruction; this is called retrograde embolism.

Effect.—The results of embolism depend upon the composition of the embolus, obstructed circulation and infarction.

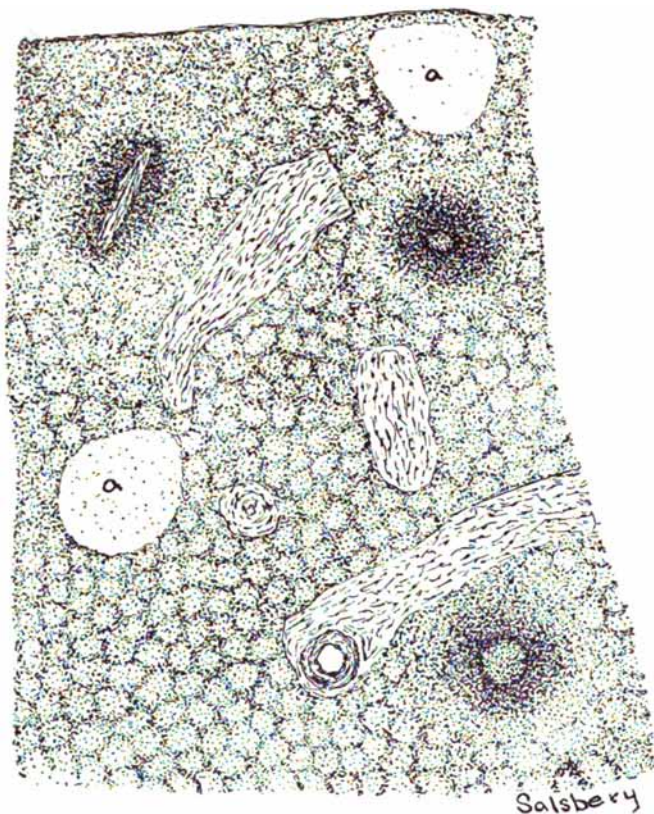


Fig. 86.—Anemic infarcts in the spleen.
a. Infarcted areas due to emboli in capillaries supplying them.

Composition of the embolus.—Emboli composed of cells having the power to multiply, at the point of impaction (embolism) become secondary foci or metastases of the primary pathological condition, as metastatic sarcomata, leukemic infarctions, etc. Pathogenic bacterial emboli not only obstruct circulation, but also produce metastases of that disease as in necrobacillosis, anthrax, etc. Filarial emboli and emboli composed of fatty cells produce a mechanical effect only. Air emboli in small vessels are absorbed after a time.

Obstructed circulation.—Obstructed circulation when produced by non-infective emboli will have the same effects and terminations as the non-infective obstructive thrombi.

Infarction.—Infarction is the process of obstructing a vessel with an embolus. The area supplied by the obstructed vessel is called an infarct. The area of infarction is determined by the region supplied by the occluded vessel and is usually wedge-shaped. An area supplied by an artery that has been infarcted does not become bloodless at once because some of the blood remains in the vessels of the infarcted area and some may enter the periphery of the infarct through anastomosing capillaries and venules of adjacent regions.

Infarcts may be anemic or hemorrhagic.

An anemic infarct is one in which there is limited anastomoses of venules and capillaries of contiguous areas. The blood remaining in the vessels of an anemic infarct soon becomes decolorized and the area appears pale in color. Anemic infarcts usually undergo necrosis early because of the lack of nutrition. The type of necrosis is largely dependent upon the nature of the embolus. Infarcts produced by infectious emboli usually suppurate or putrefy and infarcts produced by non-infective emboli may become liquified, absorbed and replaced with fibrous tissue or it may become caseated or calcified and surrounded by a fibrous capsule and persist for a long time.

A hemorrhagic infarct is one in which there are anastomoses of the vessels of the infarct and the venules and capillaries of contiguous areas through which blood passes and becomes stagnated in the affected area. Hemorrhagic infarcts may become decolorized, there may be inflammation established around their periphery, or the blood and the involved tissue may be disintegrated and absorbed.

Infarcts may become cystic, caseous, calcareous, absorbed and substituted with fibrous tissue, or they may become infected and there may be abscess formation or gangrene.

Infarction occurs most frequently in the kidney, spleen, brain, lung and less frequently in the heart, liver, retina, etc.

Typical terminal arteries are common in the kidney and spleen and hence infarction frequently occurs in these organs. In the kidney anemic infarcts are most common, hemorrhagic and anemic infarcts occur in the spleen. Cardiac infarction is not common and is usually caused by thrombosis of the coronary vessels. Cerebral anemic infarction occurs occasionally and the infarct usually undergoes simple softening, hemorrhagic cerebral infarction is rare.

ISCHEMIA.

*DEFINITION.**ETIOLOGY.*

- Diminished calibre of supplying arteries.*
- Stimulation of vaso constrictor nerves.*
- Inhibition of vaso dilator nerves.*
- Tonic spasms of vessel musculature.*
- Occlusion of supplying arteries.*
- Mechanical.*
- Tumors.*
- Thrombi, etc.*
- Collateral hyperemia.*

APPEARANCE.

- Macroscopic, pale, flabby, lower temperature.*
- Microscopic, cell degeneration, atrophy or necrosis.*

EFFECTS—*Depend upon extent and duration and may be atrophy or necrosis.*

ANEMIA, as usually considered, is a condition in which there is either a deficiency in the quality or in the quantity of blood. The discussion of this theme will be found in special pathology.

ISCHEMIA is a condition in which there is insufficient or total absence of blood in a part of the body.

Etiology.—Ischemia may be caused by influences that diminish the calibre or occlude the vessels supplying blood to a part or by collateral hyperemia. The calibre of arteries may be diminished by contraction of the vessel musculature induced by low temperature, high temperature, drugs, etc., which stimulate the vaso-constrictor nerves, or inhibit the vaso-dilator nerves or cause tonic spasms of the vascular muscle. The supplying arteries may be occluded by mechanical pressure produced by bandages, ligatures, harness, collar, thrombi, emboli, neoplasms, tissue proliferations and tissue infiltrations. Ischemia in one part may be caused by hyperemia in a related part, because the blood of the entire body is easily contained in the vessels maintained at the normal calibre, blood pressure causing an equal distribution of it; and if the vessels of one area are increased in calibre, followed by an increased inflow of blood, the quantity of blood will be diminished in some part, thus a marked hyperemia of the spleen is usually accompanied by ischemia of the stomach. It is possible for sufficient blood to collect in the vessels of the liver to drain the system to a sufficient extent that the animal would die of ischemia of the brain.

Appearance.—*Macroscopic.*—An ischemic tissue appears bloodless and is pale, flabby and of a lower temperature than the same tissue with a normal blood supply. If incised the tissue appears dry and there will be limited or no hemorrhage.

Microscopic, the blood vessels are practically empty and the tissue cells are more or less shriveled as a result of insufficient moisture.

Effects.—The outcome of ischemia is determined by the length of time it exists and the degree of completeness of the condition. Temporary, partial ischemia usually terminates in complete recovery. Continued partial ischemia is a frequent cause of atrophy. Complete absence of blood for a considerable time results in necrosis.

HYPERMIA.

DEFINITION.

ETIOLOGY.

Enfeebled circulation.

Mechanical interference.

APPEARANCE.

Macroscopic, bluish, cold clammy.

Microscopic, engorged veins, degeneration.

EFFECTS—*Depend upon cause, duration, degree and location and may be fibrosis, oedema, thrombosis, necrosis and recovery.*

Hyperemia is a condition in which there is an increased quantity of blood in a part. The condition is practically local for an increased total amount of blood could not be retained in the general circulation without increasing the general blood pressure which would result in an increased production of lymph and hence diminish the volume of blood. Physiologic hyperemia is evident whenever an organ or part is active. Local pathologic hyperemia may be passive (venous) or active (arterial).

PASSIVE OR VENOUS HYPEREMIA.

Passive or venous hyperemia is a condition in which there is a normal quantity of blood constantly flowing into an organ or part, but a diminished quantity flowing out. An excess of venous blood consequently accumulates in the part.

Etiology.—Passive hyperemia is caused by enfeebled circulation due to weak heart, bicuspid and tricuspid insufficiency or stenosis, or diseased vessels and by pressure upon the outgoing vessels by ligatures, bandages, neoplasms, dislocations, fractures, etc.

Appearance. *Macroscopic.*—The affected tissues are bluish in color and usually feel spongy, cold and moist when palpated.

Microscopic.—A tissue affected with venous hyperemia has distended capillaries and venules, the lymph spaces are engorged with lymph and the cells are swollen and their protoplasm cloudy.

Effects.—The outcome of venous hyperemia depends upon the cause, degree, duration and organs affected. Thus venous hyperemia resulting from infective phlebitis is more serious than if caused by noninfective agencies. A venous hyperemia caused by complete obstruction of a vein is more likely to be fatal than one resulting from partial obstruction. Venous hyperemia of short duration is usually of little consequence but, if long continued, it results in necrosis or fibrosis depending upon the degree of obstruction. Venous hyperemia of vital organs, as the brain or lungs, is more likely to have a fatal termination than if some less important structure as a muscle were involved.

Therapeutic Venous Hyperemia properly produced results in (a), diminution of pain, probably because of the dilution of the irritating substances (b), destruction of bacteria, the accumulated blood serum possessing strong bactericidal properties (c), increased nutrition because of the increased amount of blood. Bier's hyperemic treatment of open joints by producing venous hyperemia illustrates this type.

Pathologic Venous Hyperemia may result in fibrosis, oedema, thrombosis, necrosis, or recovery. A long continued slight venous hyperemia usually results in fibrosis and is noted in the liver of animals affected with a slight tricuspid insufficiency or stenosis. A marked venous hyperemia, but not caused by complete venous obstruction usually results in oedema, and is noted in the peritoneal cavity (ascites), in animals in which the portal circulation is partially obstructed. Venous hyperemia caused by complete obstruction results in thrombosis and is observed in intussusception of the intestines. If other venous channels are unable to convey the blood from a part in which there is a complete venous thrombus, necrosis occurs as in strangulated herniae. Venous hyperemia of short duration, even though it is quite extensive, results in complete recovery if the cause is removed and the tissues are repaired.

ACTIVE OR ARTERIAL HYPEREMIA.

ETIOLOGY.

- Increased calibre of arteries.*
- Stimulation of vaso-dilator nerves.*
- Inhibition of vaso-constrictor nerves.*
- Paralysis of vessel musculature.*
- Collateral ischemia.*
- Diminished pressure.*

APPEARANCE.

- Macroscopic, red, hot, swollen.*
- Microscopic, engorged arteries and capillaries.*

EFFECTS.

- Hypertrophy, hyperplasia, inflammation, recovery.*

Active or arterial hyperemia is a condition in which there is an increased inflow of blood to a part or organ without an equally increased outflow.

Etiology.—Arterial hyperemia is caused by an increase in the calibre of the supplying arteries, by collateral ischemia and by diminished external pressure. The calibre of the supplying artery may be increased by stimulation of the vaso-dilator nerves, by heat, chemicals, etc., by inhibition of the vaso-constrictor nerves, and by paralysis of the muscular tunic of the artery.

The calibre of the surface vessels is in part the result of ex-

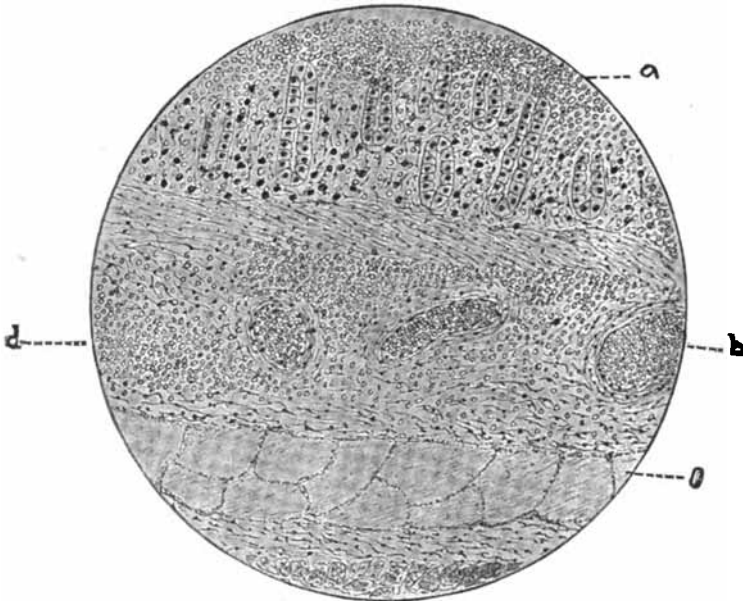


Fig. 86.—Hyperemia, hemorrhage and oedema of intestine of a horse.

- | | |
|----------------------|---------------------------|
| a. Surface exudate. | c. Area of oedema. |
| b. Engorged vessels. | d. Subsurface hemorrhage. |

ternal pressure. If the external pressure is materially diminished, there will be arterial hyperemia of the cutaneous arteries as is evidenced in hyperemia produced by cupping. Collateral ischemia may cause hyperemia of the related parts for the same reason that collateral hyperemia may cause ischemia.

Appearance.—*Macroscopic.*—An arterial hyperemic part is scarlet red in color, usually feels dense, dry and has an increased temperature. If the tissues are incised, blood escapes freely.

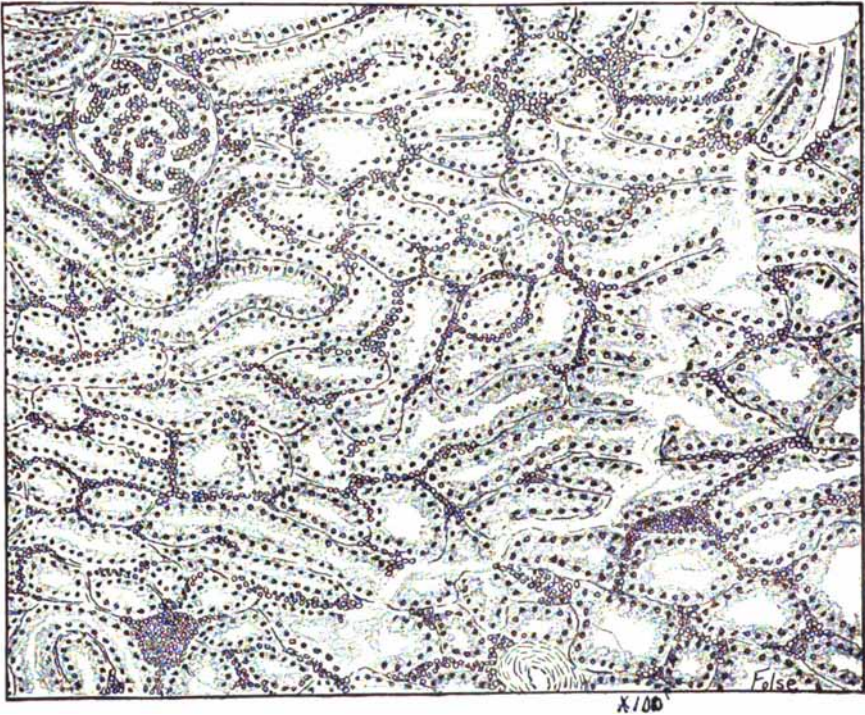


Fig. 87.—Hyperemia of Kidney, showing engorged capillaries.

Microscopic.—Tissues affected with arterial hyperemia contain dilated arteries and capillaries, the lymph spaces are engorged with lymph, the tissue cells may be considerably swollen and diapedesis may be noted.

Effects.—The effects of arterial hyperemia depend upon the cause, degree, and duration and organs affected. Arterial hyperemia caused by infective agencies is more serious than if caused by other means. Arterial hyperemia of a sthenic type is usually succeeded by inflammation and asthenic hyperemia may terminate in recovery.

Arterial hyperemia of short duration is less serious than it would be if long continued, thus, active pulmonary hyperaemia is occasionally aborted in the horse and such animals are usually ready for service in 24 to 48 hours, but if active pulmonary hyperemia continues for 24 hours it is succeeded by inflammation (pneumonia).

Arterial hyperemia varies in different organs. Affections of the more highly organized structures are usually more serious.

Physiologic arterial hyperemia is a condition in which there is an increased amount of blood flowing into a tissue because of increased physiologic demand, thus during gastric digestion an excess of blood passes to the stomach through the gastric arteries.

Therapeutic arterial hyperemia, when properly produced in a diseased part, results in (a), diminished pain, (b), resorption of inflammatory exudate, hemorrhagic extravasate, and oedematous transudate, (c) increased nutrition, thus by the alternate use of cold and hot applications an arterial hyperemia is produced and is of value in strained tendons, bruises, etc.

Pathologic arterial hyperemia, may produce hypertrophy, hyperplasia and permanent arterial dilatation. Excessive development of a part (hypertrophy or hyperplasia) may result from a long continued active hyperemia as in thickening of the skin as a result of continued application of blistering agents. but arterial hyperemia is as a rule of short duration for it usually terminates in recovery or is succeeded by inflammation.

CHAPTER VI. INFLAMMATION.

DEFINITION.

GENERAL CONSIDERATION OF STIMULI AND REACTIONS.

ETIOLOGY.

Non-infective.

Mechanic.

Thermic.

Electric.

Chemic.

Infective.

Non-suppurative.

Suppurative.

FACTORS CONCERNED IN INFLAMMATION, (Phenomena.)

Vascular.

Constriction of vessels.

Dilatation of vessels.

Acceleration of rate of blood flow.

Retardation of rate of blood flow and leucocytic margination.

Oscillation of blood in the vessels and diapedesis.

Stasis.

Exudation.

Exudate.

Composition.

Physic.

Chemic.

Histologic.

Varieties.

Serous.

Fibrinous.

Hemorrhagic.

Factors determining quality and quantity.

Cause of inflammation.

Condition of animal.

Location of process and of tissue affected.

Significance of the exudate.

Increased amount of nutrition to the affected part.—

Dilutes, counteracts, neutralizes or destroys the irritant.

Circumscribes the inflammatory process.

Chemotaxis.

Phagocytosis.

THE SIGNS OF INFLAMMATION.

Redness

Swelling.

Increased temperature.

Pain.

Impaired function.

EFFECTS UPON THE TISSUE INVOLVED.

Degeneration.

Parenchymatous.

Fatty.

Mucoid.

Serous.

Amyloid.

Hyaline.

Necrosis.

Regeneration or proliferation.

*THE KINDS OF INFLAMMATION.**Etiology.**Simple.**Infective.**Non-suppurative.**Suppurative.**Surface.**Sub-surface.**Exudate.**Serous.**Fibrinous.**Hemorrhagic.**Tissue.**Parenchymatous.**Interstitial.**Time, activity and results.**Acute.**Chronic.**Miscellaneous.**Catarrhal.**Purulent.**Ulcerative.**Vesicular.**Pustular.**Proliferative.**Specific.**TERMINATION.**Resolution.**Tissue proliferation.**Dissolution.**CONCLUSIONS.*

Inflammation is a name applied to a group of pathologic processes including circulatory disturbances, retrogressive and progressive tissue changes. The term inflammation is difficult to define because of the several factors entering into the process and of the variation of each factor. It may be defined as the reaction of a living animal tissue to an irritant.

A stimulus is anything that produces action in a living tissue. An irritant is anything that produces excessive stimulation in a responsive tissue. Stimuli and irritants differ only in degree. Mild friction of the skin is a stimulus to that structure. When the friction is intensified and the cutaneous function is overstimulated the friction becomes an irritant. All living tissues respond to stimuli and likewise to irritants. The response or reaction of a living tissue to an irritant, i. e. excessive tissue stimulation, accompanied by circulatory disturbances and by destructive or proliferative tissue changes, constitutes the process known as inflammation. The general phenomena of inflammation will be better understood if some preliminary considerations of the reaction to stimuli are first discussed.

General Consideration of Stimuli and Reactions.—It is a

well known fact that all living things (organisms) respond to stimuli. A stimulus is that which excites or produces a temporary increased vital action, or it is any substance or agent capable of producing activity in a living tissue or producing an impression upon a sensory organ. The extent or degree of response to a stimulus is directly proportional to the organization and complexity of the tissue and especially those tissues which are: (a) capable of being stimulated; (b) capable of transmitting an impulse; and (c) capable of interpreting the impressions produced by the impulse. The following discussion of response to stimuli is confined to animal tissues because inflammation affects animals only.

Protozoa, although of the simplest structure, consisting of a single cell, respond to the various stimuli. They respond to light. Thus, if a portion of a cover glass preparation of living amoebae be exposed to intense light, the amoebae in the lighted area will, in a short time, become restless and begin to move about and will finally move away from the area of light. By a specially arranged hot stage, so that there are areas of different temperature, amoebae will be observed to accumulate in the areas of favorable temperature and emigrate from those of unfavorable temperature. That is, they respond to or are responsive to thermic stimuli. In a similar way amoebae respond to various chemical stimuli. If a drop of acid be so placed that it will slowly diffuse into the water or fluid in which the amoebae are being studied, they will move away from the acid. If an amoeba be divided by mechanical means so that one segment contains the entire nucleus and the other segment has no nucleus, it will be observed that the nucleated segment responds to the stimulus by regenerating tissue to replace the nonnucleated segment which was removed. On the other hand, the nonnucleated segment of the amoeba may survive the shock of separation, but soon begins to degenerate and finally dies. Thus is shown the response of living structure to photic, thermic, chemic and mechanic stimuli.

If more complex animals be considered there will be observed a similar response to stimuli. Thus, the hydra responds to the various kinds of stimuli and has a remarkable power of regeneration of tissues. Vermes are very responsive to stimuli and all observers have noticed that when an angle-worm is cut in two both ends will crawl away. Vermes are among the lowest forms of animals that possess cells corresponding to white corpuscles or leucocytes of higher animals. These cells are observed to emigrate to the point of injury or to surround

the foreign bodies or substances that are experimentally introduced into the bodies of vermes. This reaction is analogous to the reaction of the mammalian leucocytes.

The discussion so far, has been with reference to animals that possess no blood or vascular systems, or at least only in a rudimentary form.

Vertebrates are more highly organized and are consequently more responsive to stimuli than invertebrates. Mammalia are the most complex in structure of all animals and they are likewise most responsive to stimuli.

The mammalian cornea is a nonvascular structure being composed of fused layers of fibres arranged parallel to the surface. Between the layers of fibres connective tissue cells and lymph spaces are found but no nerves. The cornea is covered externally by the conjunctiva. If the cornea be irritated there will be a reaction, the extent of which depends upon the intensity of the irritant. A puncture of the cornea with a sterile needle produces the following reaction or tissue changes; (a) within a few hours after the injury the affected area appears swollen and the cells that were punctured begin to degenerate while the uninjured cells immediately surrounding the needle puncture become tumefied and vacuolated; (b) from twenty to thirty hours after the puncture, wandering cells appear in and around the injured area, and as the cornea is nonvascular they must be migratory connective tissue cells; (c) by the third or fourth day the punctured cells will have been removed, by solution or otherwise, from the affected areas. Those cells surrounding the injury will have divided by mitosis, the newly formed cells replacing those that were destroyed and the wandering cells will have migrated from the injured focus. (The destroyed epithelial cells of the conjunctiva are replaced by those next to the injury).

If sterile iron dust, or other insoluble granular material is aseptically introduced into the cornea, a reaction, as described above, will take place, and, in addition, the migratory connective tissue cells will ingest or incorporate the introduced particles and carry them out of the injured focus.

When the cornea is injured more severely, as by the application of a caustic solution (irritant), in addition to the above reaction, a migration of leucocytes from the marginal corneal vessels usually occurs within thirty hours. Some of the invading leucocytes become destroyed and some of them may multiply, but they usually all disappear from the point of injury within from forty to fifty hours. The length of time

necessary for repair of such an injury is variable according to the extent of the injury and the readiness of response of the tissue.

In vascular tissue the following reaction occurs. An aseptic cutaneous incision unites almost immediately if the wound margins are placed and maintained in exact apposition. The tumefaction is slight because of the limited extravasate from the severed vessels. There is a slight exudate which coagulates and cements the margins or lips of the wound. In a microscopic section through such a wound some cells are found destroyed and others injured. The cells bordering such an injury sometimes increase in size to such an extent that they project into the cement between the two incised surfaces. Wandering cells and leucocytes in varying numbers appear throughout the entire injured area. The cement (exudate) and the degenerated and necrotic marginal cells are later absorbed. The cells bordering the incision multiply by direct cell division, the newly formed cells replacing those destroyed. New capillaries extend through the newly formed tissue. Finally the leucocytes emigrate and disappear from the injured area.

In a more extensive injury, such as a gaping wound that later becomes infected, a more complex reaction is observed. The following changes take place during the first twenty-four hours after an injury of this nature is inflicted. There is hemorrhage, the extent of which depends upon the size of the vessels severed and the gaping of the wound. The extravasated blood accumulates in the wound and also infiltrates the adjacent tissues. The injury (irritation) causes hyperemia, especially of the arterioles, resulting in engorgement of the capillaries. From the engorged and dilated capillaries there is marked exudation. The exudate escapes upon the wound surface and infiltrates the tissues of the injured area. The accumulation of the hemorrhagic extravasate and the inflammatory exudate plus the increased size of the vessels (hyperemia) tumefies or swells the injured area. There is an accumulation of mononuclear leucocytes or wandering connective tissue cells in the injured tissue and an immigration of polymorphonuclear leucocytes. Many cells are destroyed outright by the injury or by the action of infectious bacteria. Those cells bordering the destroyed cells are injured and become tumefied and may later undergo necrosis. The cells, especially the connective tissue cells located peripherally to the injured cells, become enlarged and multiply by indirect cell division. The injured cells are repaired and the newly formed

cells are massed together and project outward thus replacing the destroyed cells.

The discharge from such a wound after twenty hours consists of serum, shreds and fragments of necrotic tissue, dead cells (especially leucocytes) and a variety of microorganisms.

The reaction in the above case consists of circulatory disturbances, degeneration, necrosis, and regeneration of tissues.

Etiology.—The exciting causes of inflammation may act from within the body, hematogenous or lymphogenous, or from without, i. e., extraneous as burning, etc. They may produce their action by direct contact upon surfaces of the body as from a blistering agent externally applied, or, by contact internally, as from arsenic. They may produce their effect while being excreted, as in the production of nephritis by cantharides or turpentine. Some harmless agents may become irritants as the result of chemic change produced by some of the body juices or fluids (lysins).

The causes of inflammation may be divided into two general classes, non-infectious and infectious.

NON-INFECTIOUS.—The non-infectious causative factors are not as active in producing inflammatory disturbances as the infectious agencies, but they are of some importance and should not be overlooked. Some have positively stated that "There is no inflammation without infection." Reasonable interpretations of clinical and experimental observations supply sufficient evidence that there is inflammation without infection. The following are the principal non-infectious causes of inflammation.

Mechanic or traumatic.—Surgical wounds which heal by primary union are undisputed examples of mechanically produced inflammation. The reaction taking place in an aseptic incision consists in cell-destruction, slight circulatory disturbances, leucocytic immigration and regeneration of tissue. Such a reaction is typical of inflammation and the affected area is devoid of any infection. A sterile needle introduced into a tissue, the surface of which is aseptic, produces a reaction identical to the reaction observed in primary union of tissue. Mechanic or traumatic causes of inflammation may produce, or cause to be produced in the injured cells, chemic substances that are responsible for the reaction.

Thermic.—A temporary exposure to a high or low temperature is sufficiently irritating to produce a marked inflammation. Let those doubting this statement take the chimney from a lighted lamp and hold it in the hand for one minute and

they will acknowledge that heat produces all the symptomatic evidences of inflammation and there is no infection. The principle object in the use of the thermo-cautery is to produce or establish inflammation. A thermo-cautery, or any severe burn, produces tissue necrosis, as well as the destruction of bacteria in that area (sterilization), and an inflammatory zone is immediately established around the necrotic tissue which is sterile and may remain free from infection.

A short exposure to an extremely low temperature produces an inflammation. If the exposure is of long duration necrosis is likely to occur. "Chilblains" is an inflammation resulting from temporary exposure to a low temperature. Sloughing following freezing of calves' ears, pigs' tails and cocks' combs are familiar examples of necrosis resulting from long exposure to extremely low temperature. An inflammatory zone is established around necrotic areas produced by freezing similar to the inflammatory zone observed around necrotic areas produced by burning. Thermic variations may produce chemic substances in injured tissues which are sufficiently irritating to establish inflammation.

Electric.—It is common knowledge that electricity causes inflammation. Animals injured by lightning usually show evidences of cutaneous inflammation. In cities animals as well as men frequently contact wires charged with powerful electric currents and receive local injuries that are usually inflammatory in their nature.

Chemic.—There are many chemicals that are irritants. A number of them are used as therapeutic agents when irritants are indicated. Mineral acids, caustic alkalies, mercury salts and arsenic are some examples of chemic agents that produce inflammation when applied in dilute solutions, and necrosis when applied in more concentrated form. A 10 per cent solution of nitric acid applied to the skin for a very short time produces inflammation. Inflammatory symptoms following the nitric acid application appear immediately; and, as the acid is a disinfectant, the inflammation cannot be the result of infection. In animals poisoned by any of the mineral poisons there may always be observed an inflammation in the mucosa of the alimentary tract more extensive than could have been produced by infection in the limited time of action.

Many reptiles, bees, wasps, and ants introduce chemic substances into animal tissues that are extremely injurious and establish inflammation of very rapid evolution.

INFECTIOUS OR VITAL AGENCIES are the most important etiologic

factors in the production of inflammation because they are the most frequent offenders. Infection usually produce inflammatory disturbances through the action of chemic substances elaborated by the infecting micro-organisms, as metabolic products. The infection may be local and produce localized inflammation as in a superficial abscess and in coccidiosis. The elaborated chemic substances may be absorbed from the localized infection and produce inflammation elsewhere in the body. Infection may be general and produce conditions similar to inflammation in practically all the tissues of the body as in generalized anthrax. However, the term inflammation is usually confined to local disturbances. The extent of irritation produced by any infecting organism is dependent upon the virulency of the given organism and the resistance of the infected animal. Thus, infection with *Streptococcus pyogenes equi* may produce pyemia in one animal and only a local abscess in another. Again, some bacteria, as the anthrax bacilli, may produce septicaemia in one animal and localized inflammation in another. A concise etiological classification of inflammation produced by living organisms is impossible because of variations both in the virulency of the organisms and in the resistance of the tissues. Animal parasites are of considerable consequence in the production of inflammation. They may produce inflammation by mechanical interference, as the *Echinorychus gigas* which inserts its barbed proboscis into the intestinal mucosa thus injuring the tissue as well as opening an avenue for the entrance of various bacteria. The *Trichina spiralis* by perforating the intestinal wall and by burrowing in the muscular tissue produces sufficient irritation to establish inflammation, the results of which are evidenced on microscopic examination of a lesion. It has been suggested that the etiological factor of rabies is an animal parasite; the round-celled infiltration of the ganglionic nerve cells and perivascular spaces having marked characteristics of the lesions of inflammation. Psorospermosis, a condition resulting from psorospermic infestation, is inflammatory in its character.

In a general way infective inflammations may be discussed as non-suppurative and suppurative.

The non-suppurative infective inflammations are those inflammatory disturbances in which there is no purulent fluid or pus produced. As examples the following may be cited—septic infection succeeding nail pricks in horses feet; blackleg in calves caused by the *Bacillus anthracis symptomaticus*. (Sar-

cophysematous bovis); malignant oedema caused by the *Bacillus* of malignant oedema.

Suppurative infective inflammation is characterized by the formation of pus. The causative bacterial agents of suppuration are designated as pyogenic bacteria or pyobacteria. The following are the most important bacteria of this class:

Staphylococcus pyogenes aureus.

Staphylococcus pyogenes albus.

Staphylococcus pyogenes citreus.

Strepto-coccus pyogenes

Baccillus pyocyaneus.

Factors Concerned in Inflammation.—The animal body is an intricate mechanism composed of different tissues in various combinations. The phenomena of inflammation are the changes that take place in the tissues plus the conditions resulting from those tissue changes, thus including all the changes taking place in the inflammatory focus. The following are the most important.

VASCULAR DISTURBANCES.—These are universally present in animals possessing a vascular system, but inflammation, or a condition analagous to it, occurs in the tissues of animals that have no vascular system, and in nonvascular tissues of animals that have a vascular system. Hence vascular changes are not essential in the process. The vascular changes are dependent upon nervous influence, because the calibre of blood vessels, especially arteries, is controlled by vasomotor nerves, i. e., vasodilators and vaso-constrictors; stimulation of the former producing dilatation, of the latter constriction of the vessel. Inflammatory areas become necrotic when dilatation of the supplying arteries and arterioles is inhibited. In experiments in which dilatation of the arterioles takes place the inflammatory process is limited and usually terminates in recovery in a short time. Necrosis usually succeeds inflammation in tissues in which communications of the vasomotor nerves have been destroyed. For example, the cubital nerve in the horse probably contains the vasomotor fibres that innervate the vessels of the foot and the median nerve the sensitive fibres that innervate the pedal structures. Median neurectomy is not succeeded by vascular disturbances, but cubital neurectomy is frequently succeeded by vascular disturbances and excessive exudation that terminates in necrosis followed by sloughing of the hoof.

The following vascular changes occur in an inflammatory focus and in the order designated:

Decreased calibre of the supplying arteries and arterioles.

Temporary contraction of arteries is the first result of the application of an irritant. The cause of the constriction of the arteries is a spasmodic contraction of the musculature of the vessels. This is succeeded by a marked arterial dilatation.

Dilatation of the arteries and arterioles. The response to stimuli on the arteries is rapid and always active, in veins slow and usually passive, in capillaries either rapid or slow but always passive. Dilatation of vessels in an inflamed area is caused by stimulation of the vaso-dilators or inhibition of the

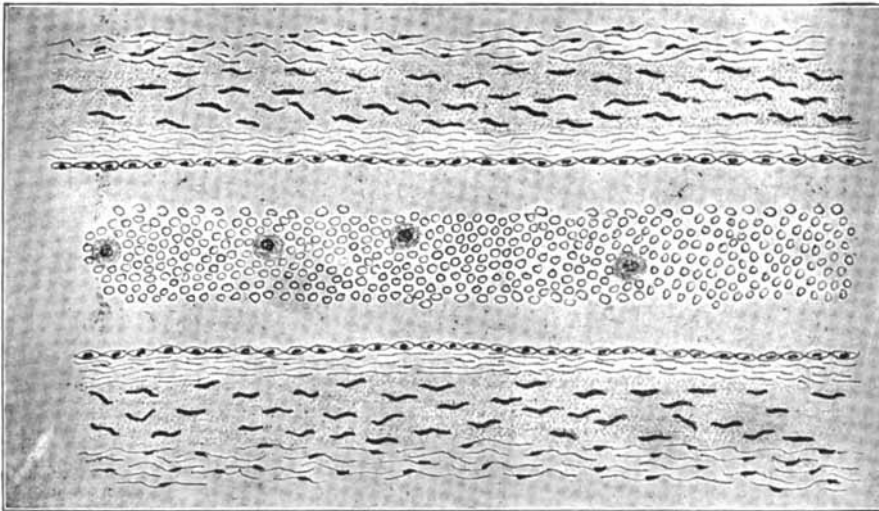


Fig. 88.—Blood vessel, showing **Corpuscles** occupying central portion of stream, typical of normal circulation.

vaso-constrictors. An increase in the calibre of the arteries results in an increased amount of blood flowing through them and into the capillaries. The increased amount of blood in the capillaries mechanically increases their calibre and also increases the amount of blood which enters the related veins and results in a dilatation of them. By increasing the lumen of a vessel the resistance to the flowing contents is correspondingly diminished and this results in a temporary acceleration of the rate of blood flow.

Acceleration of the rate of flow of the blood. The corpuscles occupy the axial, or central part of the stream as in the normal circulating blood. The arterial dilatation plus the acceleration of the blood flow constitute the essential factors in active hyperemia.

Retardation of the rate of flow.—A long continued dilatation of a vessel results in injury especially to the endothelial lining. The injured endothelial cells become swollen, roughened and sticky. The leucocytes begin to appear in the peripheral portion of the stream, probably because of the liberation of some chemic substance by the endothelium that exerts a partial chemotactic action upon the leucocytes. They roll,

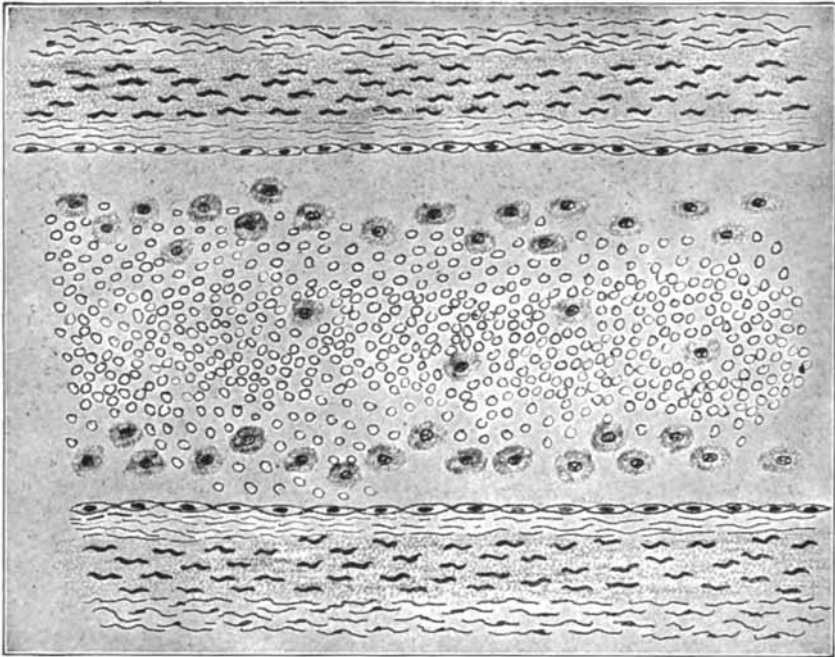


Fig. 39.—Dilated blood vessel showing corpuscles spread throughout the entire lumen typical of first stages of hyperemia.

tumble, and creep along over the swollen endothelial cells and finally adhere to their roughened surfaces. The continued attachment of leucocytes to the endothelium diminishes the calibre of the vessel and increases the resistance thus retarding the rate of blood flow.

Oscillation.—The resistance of the flowing blood, due to the roughened endothelium of the vessels and accumulation of leucocytes becomes so increased that the propelling force is momentarily overcome. The blood in the engorged capillaries and arteries may temporarily cease flowing or it may flow toward the heart, i. e. in the reverse direction during the diastolic periods. This to and fro movement is termed oscillation.

Stasis.—The resistance may become greater than the propelling force and the circulation cease for a varying period of time. This condition is denominated stasis.

Exudation.—Varying quantities of the fluid and of the cellular constituents of the blood pass through the vessels normally and an increased quantity escapes through during inflammation. The portion of the blood that escapes through the blood vessels is called exudate. The passing of the exudate

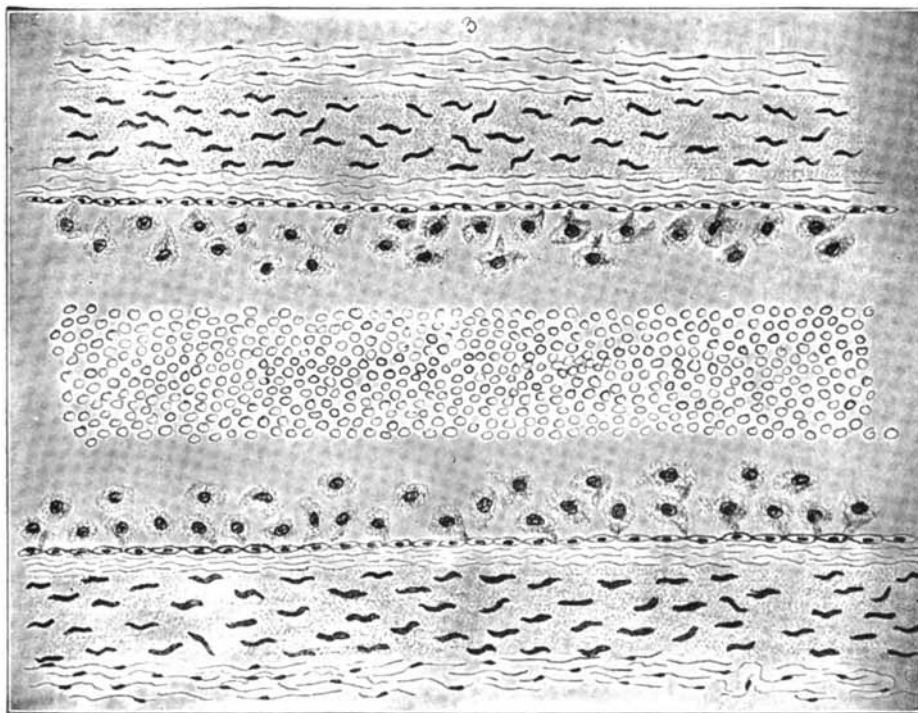


Fig. 90.—Blood vessel showing margination of leucocytes typical of the first stages of inflammation.

through the vessel wall is termed exudation. It is still undetermined whether the normal tissue lymph is a secretory product of the capillary endothelium or is produced by such physical processes as diffusion or filtration. The source of the inflammatory exudate is no doubt, the same as the source of normal tissue lymph. Exudation is a result of the vascular disturbances.

It has been previously stated that in normal circulatory blood the corpuscles occupy the axial stream and the plasma the

peripheral stream. The corpuscles occupy the axial stream because they have a greater specific gravity than the plasma. Why the leucocytes enter the peripheral or plasmatic stream in inflammation has not been clearly determined, but it is probable that this margination is a result of chemotactic influences. After the leucocytes become margined they pass through the vessel wall as follows: Small protoplasmic processes extend and project through the vessel wall. These processes gradually increase in size until the entire leucocyte has, by protoplasmic extension, passed through. The leucocytes usually pass between the endothelial cells but they may pass directly through

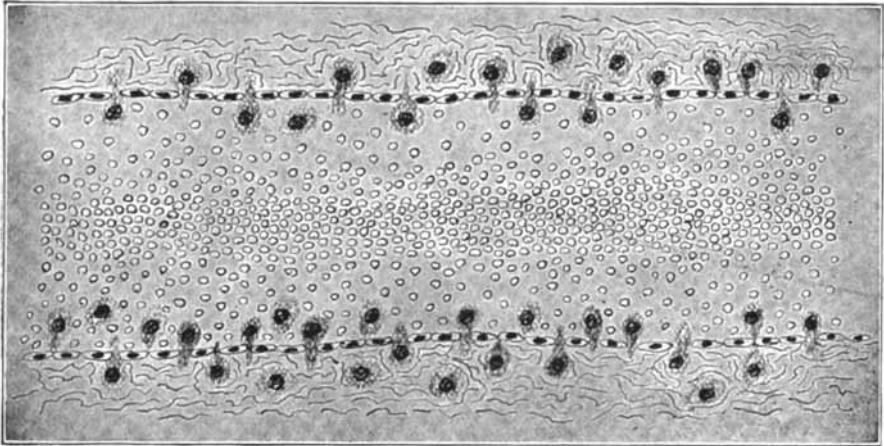


Fig. 91.—Blood vessel showing **diapedesis** of leucocytes typical of the exudative stage of inflammation.

them. The exudation of erythrocytes is passive, the cells being forced through the vessel wall by pressure. To recapitulate: fluid exudation is either a physical process, such as filtration, or a physiologic process, a secretion; leucocytic exudation is a physiologic process depending largely upon the chemic influences of the adjacent tissues, i. e., chemotaxis; exudation of erythrocytes is a physical process resulting from intravascular pressure plus diminished resistance of the vessel wall.

Exudate. 1. Composition.—Inflammatory exudate contains varying quantities of cells suspended in a fluid (plasma, tissue juice, etc). The fluid part of the exudate contains proteids (serum albumin and serum globulin) in excess of normal plasma. It has a specific gravity of 1018 or more. The quantity of proteid is directly proportional to the severity of the process and

is never less than 4 per cent and frequently as much as 6 per cent. It usually coagulates readily if withdrawn from the inflammatory tissues. The coagulability of inflammatory exudate is so constant that it may be used in differentiating inflammation from oedema. The exudate is usually acid in reaction. The fluid portion of the exudate is similar to the blood plasma with the exception of the varying percentage of proteids, and the presence of some other soluble substances. Leucocytes are the principal cellular elements found in the exudate, erythrocytes occurring only in certain inflammatory conditions, such as croupus pneumonia.

The following types of leucocytes are especially concerned in inflammation; polymorphonuclear, lymphocytes small and large. Polymorphonuclear leucocytes with neutrophile granules are the type most frequently found in an area affected with acute inflammation, providing the causative irritant was not too severe. About 70 per cent of the leucocytes present are of this type. These cells appear in the affected area in the beginning of the process. They have the power of amoeboid movement and may emigrate from the blood and lymph vessels independently of the fluid exudate. These cells possess phagocytic properties and probably produce and liberate antitoxic and bactericidal substances. They are the pus cells and constitute the bulk of the exudate in suppuration. These cells may be destroyed and disintegrated in the field of action or when the inflammatory process ceases they may migrate from the injured area and reenter the lymph or blood vessels. They do not become formative cells and never produce new tissue.

Eosinophylic leucocytes, (polymorphonuclear leucocytes hav-

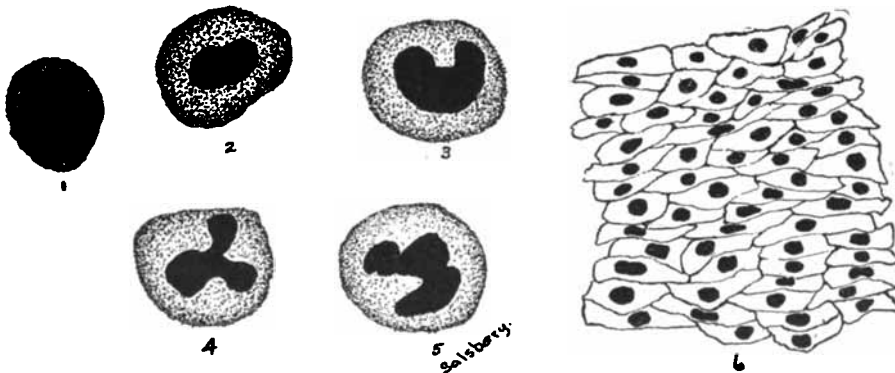


Fig. 92.—Types of cells in inflammatory exudates.
 1. Lymphocyte.
 2. Transitional leucocyte.
 3. Mononuclear leucocyte.
 4—5. Polymorphonuclear leucocytes.
 6. Endothelial cells from lining of an artery.

ing acidophile granules), appear early in an inflamed area. They are usually quite limited in number except in localized inflammation induced by animal parasites. There are frequently observed in the liver, kidney, and other tissues, foci composed of a mass of eosinophiles and appearing as inflammatory centers. These eosinophilic inflammatory foci are probably the result of invasion of animal parasites. Eosinophiles are abundant in the lesions of bursittae and in epizootic lymphangitis. Their origin is, so far as has been determined, from the blood, the lymph and tissue spaces indirectly, and the bone marrow directly. The specific action of these cells in inflammation is not known. They do not aid in the formation of new tissues.

Mast cells or polymorphonuclear leucocytes with basophile granules are observed in subacute inflammation (Adami). Their origin is from bone marrow. Their nuclei apparently become disintegrated in inflamed tissue. The significance of these cells has not been determined.

Lymphocytic invasion of the affected areas and an excess of them in the blood characterize some of the slow going or chronic inflammatory processes such as tuberculosis and actinomycosis. These cells also appear in affected tissues in the later stage of acute inflammation but are never very abundant. They may have their origin from the blood, the lymph and from adjacent lymphoid tissue. The large lymphocytes may have their origin from the small lymphocytes. Lymphocytes have a very limited power of amoeboid movement. They have never been observed to ingest bacteria although they may incorporate fragments of destroyed tissue cells or other inert substances. These cells may partake in the formation of new tissue but this has not yet been positively determined.

Cells other than leucocytes are sometimes observed in inflammatory foci. Endothelial cells, wandering connective tissue cells, giant cells, and red blood corpuscles may be present in inflamed areas.

Endothelial cells are especially evident in serous membranes affected with inflammation. They appear later in the process than either polymorphonuclear leucocytes or lymphocytes. Their origin is probably from pre-existing, like cells. They usually have a sluggish movement, are slightly phagocytic and also ingest fragments or particles of inert substances. These cells may be destroyed or they may emigrate from the affected area.

Wandering connective tissue cells are usually present in inflamed tissues. These cells do not appear until some time

after the injury is inflicted because of their slow movement. Their source is from tissue spaces, and they are the preexisting wandering connective tissue cells that occur in practically all tissues of the immature animal. They may be phagocytic but this property is not usually well developed. They are especially active in the process of repair.

Giant cells, so-called, are of common occurrence in some inflammatory processes especially tuberculosis and actinomycosis. It is probable that endothelial cells are the progenitors of giant cells. Some investigators have intimated that wandering connective tissue cells may produce giant cells. The giant cells may be formed either by a multiplication of nuclei without divi-

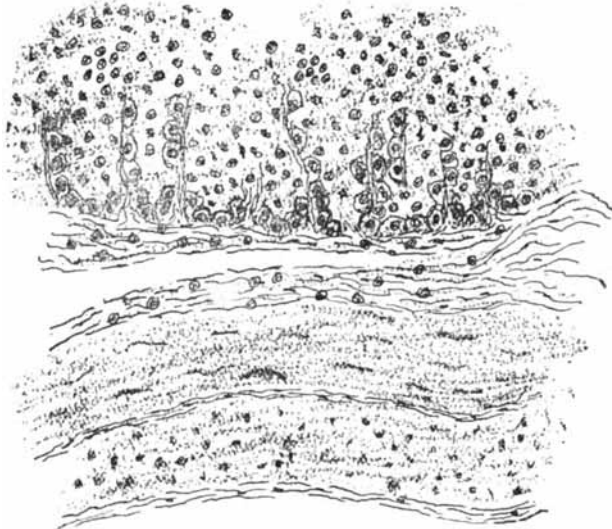


FIG. 13.—Gastritis, hog, induced by a caustic, showing destruction of gastric mucosa.

sion of the cell body or by a fusion of several independent cells (Syncytium). The latter view is the one most accepted at the present time. The function of the giant cell has not been specifically determined, but those in tubercular lesions frequently contain many tubercle bacilli indicating that they are phagocytic.

Red blood corpuscles or erythrocytes occur in the inflammatory exudate as a result of intense engorgement of the vessels. They begin passing through the vessel wall after the leucocytic migration. Increased intravascular pressure is the principal cause of their escape from the vessel, their passage through the vessel wall being entirely passive.

2. Varieties.—Inflammatory exudates may be serous, fibrinous, or hemorrhagic.

a. A serous exudate continues in the fluid state as long as it remains in the tissues or tissue spaces. It is composed almost entirely of fluid, having very few cells. This variety of exudate is characteristic of mild inflammatory conditions. The constancy of the fluidity of the serous exudate is the result of the action of enzymes that continually convert the albuminous substances into soluble compounds as proteoses and peptones.

b. Inflammatory fibrinous exudate contains two enzymes, one of which (leucoprotase) is active in an alkaline medium and the other in an acid medium. "These enzymes probably exert their greatest activity in a neutral medium, slight changes in reaction increasing digestion by the one, and suspending di-

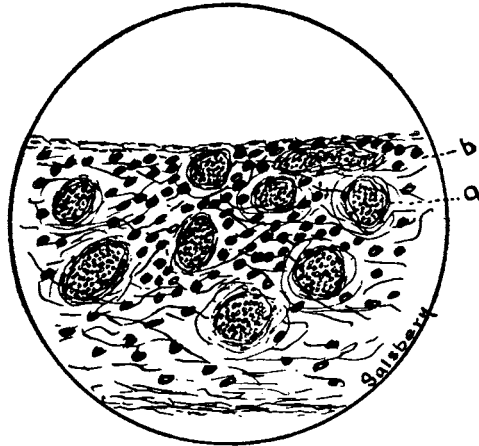


Fig. 94.—Acute Pleurisy.
a. Engorged vessels. b. Exudate.

gestion by the other." In suppuration the acid digesting enzyme probably disappears (Barker). A fibrinous exudate is one that coagulates within the tissues or tissue spaces. The coagulation of the exudate is identical with the coagulation of blood and is probably due to the liberation of fibrin forming enzymes from disintegrated leucocytes. Fibrinous exudate is the variety observed in inflammation resulting from severe irritation. The exudate usually contains many cells and a large amount of proteids.

c. Hemorrhagic exudates are those in which the red blood cells as well as leucocytes and plasma have passed through the vessel wall. This exudate coagulates the same as the fibrinous

exudate. Intense irritants are usually the causative agents of hemorrhagic inflammation. Croupous pneumonia is characterized by a hemorrhagic exudate.

A so-called purulent exudate has been described but pus is not purely exudative for some of its constituents are not derived from the blood. Pus is composed of altered leucocytes, tissue shreds, and usually bacteria, suspended in a fluid liquor-puris. Liquor puris is blood plasma and dissolved tissue. Pus contains no fibrin, the proteid constituents being converted into soluble compounds by cellular enzymes and bacterial ferments.

3. The following are probably the determining factors of the quality and quantity of inflammatory exudate.

a. Cause of inflammation:--Generally speaking a mild irritant or injury produces a serous inflammation, and an intense irritant produces fibrinous inflammation. Mechanical injuries, when there are no surface abrasions, produce an inflammation of a mild degree and the exudate is limited in quantity and is usually of a serous nature. Such injuries, however, usually produce abrasions which favor the invasion of micro organisms. Thermal disturbances of mild degree, produce a serous exudate, if more severe the exudate is extensive and of a fibrinous or hemorrhagic character. The use of a thermo-cautery is an excellent example of thermal production of inflammation and the severity of its use demonstrates the intensity of inflammation and the variations of the exudate. An irritating chemical substance injected into a tissue produces inflammation characterized by excessive exudation especially of a serous fluid. The more irritating the chemical, the greater the quantity of exudate and the greater the percentage of proteids. External application of chemical irritants produces inflammation characterized by a serous or by a fibrinous exudate. This latter may be observed in the application of blistering agents. Infective inflammation is usually accompanied by a marked exudate from the beginning of the infection. The quantity and quality of the exudate varies with the virulency of the organism. There are some exceptions however, e. g., tetanus infection causes a very limited exudate regardless of the virulency of the tetanus bacillus. In some infections, as malignant oedema, the exudate is largely fluid. In suppuration the exudate is almost entirely leucocytic.

b. Condition of the animal effected. The exudate is usually limited in animals having normal vessels, heart action, and blood. In those animals in which the vessels are diseased and especially if the endothelium has been injured there is a ten-

dency to excessive exudation. A weak heart is conducive to excessive exudation, e. g., inflammatory oedema. Animals possessing dilute blood (hydremia) are predisposed to excessive fluid exudation. The leucocytic amoeboid movement may be temporarily suspended, or it may be increased during inflammation, resulting in an absence or in an excessive number of leucocytes in the exudate. In animals having a clean close build the exudate is not so extensive as it is in those animals of a loose flabby make-up.

c. The location and tissue affected. Exudation is in direct proportion to the vascularity and density of the tissue. Inflammation in compact bony tissue or beneath dense fascia, liga-

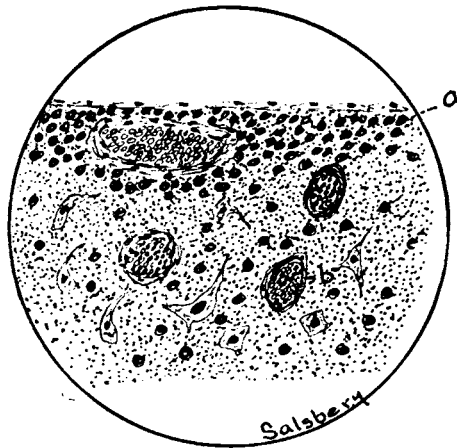


Fig. 95.—Acute Meningitis.
a. Exudate. b. Engorged vessels.

ments or tendons is accompanied by a limited exudate. Inflammation of the cutaneous structure is usually associated with excessive exudation, which accumulates in the subcutaneous areolar tissue. Inflammation of serous and mucous membranes is accompanied with exudation which may in part be discharged upon the surface but is usually accumulated in the substructures.

4. Significance of the exudate.—The significance of the exudate has had various interpretations. Virchow considered that the irritation producing the inflammation resulted in increased cellular activity in the injured area and that the exudate supplied increased nourishment to the area in which there was an excessive metabolism. Others have attributed to the exudate the “flushing out” of the injured area thus mechanically carrying

away the irritant. The exudate dilutes the irritant, especially chemical irritants, thus reducing the activity of the causative agent and mitigating the inflammatory process.

It has been determined that serum possesses some substances, as opsonins, antitoxins, bacteriolysins and bactericides, that are detrimental to infectious agents either by their bactericidal action or by chemical union with bacterial products. Thus the exudate reduces the irritation of infection by rendering bacteria inactive or by neutralizing their products. Phagocytes are very important factors in the exudate as they ingest and destroy infectious micro-organisms. The opsonic index championed by Wright of London is based on the above.

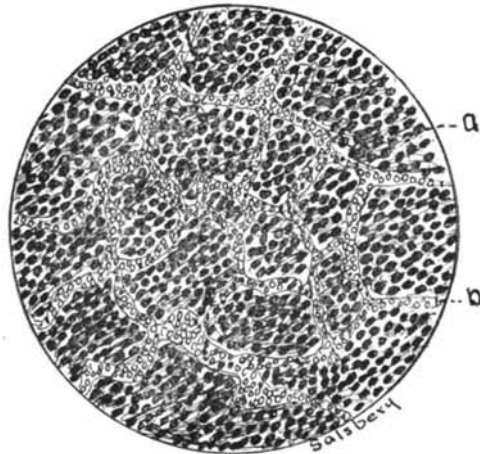


Fig. 96.—Inflammation. Gray Hepatization.
a. Air cells engorged with leucocytes. b. Hyperemia of capillaries

In aseptic incised wounds the exudate is of value in cementing the incised surfaces together, although new tissue formation is retarded by an exudate. The exudate mechanically protects the injured surfaces in gaping wounds and possesses bactericidal properties for a short time after the injury has been inflicted. After the exudate becomes inactive in its protecting properties it is a favorable medium for infection and is then probably detrimental. Injurious chemic substances may result from the aseptic dissolution of an inflammatory exudate.

Fibrinous exudates may be injurious or beneficial depending upon the location and the changes taking place in the exudate. The fibrinous exudate in croupous pneumonia is injurious because it coagulates in the alveoli of the lung thus preventing the respiratory function of that area. The fibrinous

exudate in serous cavities is beneficial, especially in localized inflammation, because it limits or circumscribes the inflammatory irritant or process by coagulating thus producing adhesions of the two serous membranes. Many horses upon which paracentesis abdominis or paracentesis thoracis is performed might succumb to generalized peritonitis or pleurisy if the inflammatory process established at the point of the puncture was not circumscribed by adhesions the result of organization

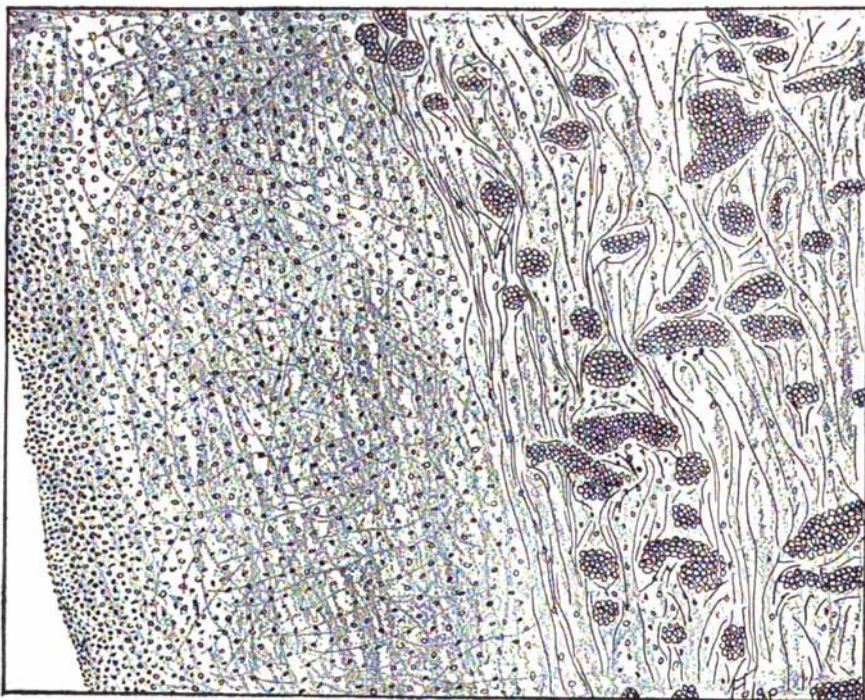


Fig. 97.—Fibrinous Pleurisy, showing an extensive exudate upon surface,

of fibrinous exudate. The immediate effect of a fibrinous exudate in a serous cavity is beneficial but the adhesions are frequently permanent thus interfering with the normal functioning of the part affected. The fibrinous exudate is also beneficial in croupous enteritis because of the protection of the diseased mucosa from mechanical injuries by food stuffs. It is on the other hand injurious in croupous enteritis for the exudate is a favorable nidus for bacteria and they may produce substances that are irritating to the injured mucosa. The coagulated exudate may also hinder intestinal secretion. The

fibrinous exudate of diphtheritic inflammation is very injurious because of its coagulation and pressure upon the tissues.

CHEMOTAXIS.—It has been determined by experiment that chemic substances exert a definite influence upon motile cells. There is always a leucocytic migration into capillary glass tubes previously charged with turpentine or croton oil and then inserted into living animal tissues. The same migration is observed when the capillary tubes are charged with bacteria or their products. Negative results are obtained when the tubes are charged with quinine or chloroform. This attraction of leucocytes toward chemic substances is **positive chemotaxis**. The repulsion of leucocytes from chemic substances is **negative chemotaxis**. The term "Chemotaxis" unmodified includes positive and negative. Leucocytic **migration** into an inflammatory area is a result of chemic influence or chemotaxis.

PHAGOCYTOSIS.—This is the incorporation and destruction of pathogenic bacteria and other foreign substances by phagocytes. Phagocytes are cells having the power of ingesting and destroying microorganisms and other foreign particles. Polymorphonuclear leucocytes having neutrophile granules are the most active cells concerned in phagocytosis. Endothelial cells and wandering connective tissue cells may be under some conditions phagocytic. The phagocytic property of cells is variable depending upon the virulency of the micro-organisms or strength of the chemic substance and upon the resistance of the phagocyte. Bacteria are enveloped by protoplasmic extensions from the cell body until they are entirely included in the aggressive phagocyte. After the enveloping process there may be observed digestion vacuoles surrounding the bacteria. The included bacteria are destroyed by ferments produced by the phagocyte. It is an intracellular digestion. The length of time necessary for the phagocyte to destroy the bacteria is variable. The bacterial destruction may be instantaneous or the bacteria may possess sufficient vitality to destroy the phagocyte. There is considerable evidence that infection is frequently generalized in the animal body by leucocytes that have enveloped bacteria and wandered to another portion of the body. The included bacteria destroy the leucocyte and, thus liberated, establish a new center of infection.

Phagocytosis is a very important factor in inflammation. No doubt many localized inflammatory conditions are aborted and the intensity of the attack of other infective inflammatory conditions reduced by the process of phagocytosis. There is a peculiar variation of phagocytosis occasionally observed,

e. g., leucocytes becoming phagocytic toward other leucocytes. Fixed tissue cells may under some conditions become phagocytic towards leucocytes; this perhaps is for the purpose of obtaining nutrition for the fixed tissue cells.

The Signs of Inflammation.—Inflammation may be recognized in exposed tissues by the so-called “Cardinal signs:” redness, swelling, increased temperature, pain and impaired function. These signs are usually perceptible in the early stages of acute inflammation, but they may not be evident throughout the entire process. Mild, chronic inflammation may not be accompanied by any of the above signs. These signs are very variable in either acute or chronic inflammation of internal organs.

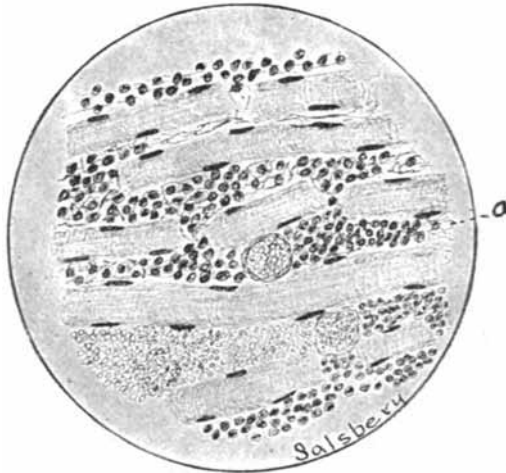


Fig. 98.—Acute Myositis.

a. Leucocytis exudate. Muscle fibres disintegrated and vessels engorged.

Redness (Rubor) is a constant sign in the early stages of acute inflammation. It is the result of an excessive amount of blood in the vessels of the affected area.

Swelling (Tumor) is characteristic of acute inflammation. It is the result of the accumulation and retention of the inflammatory exudate plus the increased amount of blood in the part. The extent of the swelling is in a direct ratio to the density of the tissue. Thus the swelling resulting from subperiosteal inflammation may not be detected because of its limited extent. On the other hand, the swelling succeeding inflammation of loose areolar tissue may be very extensive, as in cellulitis. The swelling resulting from inflammation is usually firm, dense and quite resistant in contradistinction to swelling resulting from

oedema, e. g., the tumefaction accompanying tendonitis is dense, while the swelling accompanying "stocking" is soft and doughy.

The temperature (Calor) of tissue affected with active inflammation is invariably increased. This is the result of the excessive cellular action in the inflamed area and the increased amount of blood flowing into the part.

Pain (Dolor) is a common symptom of inflammation. This may be the result of pressure upon nerve endings by the accumulated exudate. However, oedema is accompanied by an excessive accumulation of fluid in the tissues, and oedematous tissues are not hypersensitive. It seems more probable that inflammatory pain is the result of the injurious action of the irritant or soluble products of the exudate upon the sensory nerve endings. The inflammatory pain is often referred to some other part of the body, e. g., in pleurisy the pain frequently appears abdominal.

Impaired function (Functio laeso) is a constant feature observed in inflammation. In the beginning of the process the function of the affected tissues (especially secretory) is in excess of the normal, but this is succeeded in the later stages by depression of the function. The increased function is a result of increased nourishment, increased stimulation, and probably increased pressure is also a factor; the depressed or diminished function is the result of the injurious action of katabolic products, produced by excessive cellular action, and of the irritant producing the inflammatory process. Thus, in the beginning of acute nephritis there is an excessive amount of fluid (urine) excreted, this is succeeded by diminution or complete suppression of the excretion (urine).

Effects upon the Tissue Involved. — As a result of the inflammatory process the tissues involved may undergo various changes. These changes may be *degenerative, necrotic, regenerative or proliferative* in character. Degeneration usually precedes regeneration, but the two conditions may be independent of each other; thus in ulceration, degeneration and necrosis may alone be evident, and in the formation of a tubercle of tuberculosis proliferation is the principal process. Both conditions may exist at the same time in different parts of an affected area, degeneration taking place in the center of the diseased area and regeneration or proliferation in the periphery. Inflammation not accompanied by either degeneration or regeneration is rare. The injuries or irritants establishing inflammation may and frequently do produce death of some of the tissue cells; necrotic tissue is sufficiently irritating to pro-

duce inflammation, and necrotic areas are usually surrounded by an inflammatory zone. Inflammation is confined to the reactive process of the injured cells and should not be confused with the death of the cells or necrosis.

Degeneration and regeneration are distinctly opposite processes. The former is destructive, resulting in impairment and death, while the latter is constructive, resulting in overgrowth and proliferation. Degeneration is caused by insufficient food, inhibition of irritating products, or excessive and frequently perverted functional activity. Regeneration occurs when there is an adequate supply of nutrition, and depends upon the rever-




Fig. 99.—Chronic Pneumonia.

- a. Alveolus. c. Wandering leucocytes.
b. Fibrous proliferation.

sion of the cells to the embryonic type or stimulation of the reproductive properties of the cells, the latter usually at the expense of the normal functional activity. Both processes affect the cellular elements of the tissues, primarily and actively, and the intercellular substances secondarily and passively. Some exceptions will be mentioned later. The leucocytes and wandering cells may also undergo changes similar to those which the fixed tissue cells are subject. In general, degeneration characterizes acute inflammation and regeneration characterizes chronic inflammation. The importance of either of the above processes depends upon their extent. The general consideration of the two processes has been combined for the sake of comparison; but they will now be considered separately.

Degeneration.—Practically all degenerations, to which tis-

sues in general are subject, are common in inflamed tissues. The following are the principal ones that have been described.

1. Parenchymatous degeneration (cloudy swelling), is the most common type in acute inflammatory tissues. It is indeed rare to examine sections of tissue affected with acute inflammation and not find this degeneration. The presence of parenchymatous degeneration is an additional factor frequently resorted to in differential diagnosis of inflammation. This type of degeneration occurs in all tissues, but more especially in glandular structures.

2. Fatty degeneration does not occur as frequently as parenchymatous degeneration. Like parenchymatous degeneration, it occurs in tissues affected with acute inflammation. It invariably occurs in combination with parenchymatous degeneration and is usually a sequel of the latter. The presence of fatty degeneration in inflammatory tissue may cause confusion in microscopic diagnosis, especially if the degeneration is extensive. The degeneration is common in epithelium (glandular), muscular tissue and connective tissue.

3. Mucoïd degeneration is quite common in inflamed tissues. It is characteristic of catarrhal inflammation. This degeneration affects the intercellular substance as well as the cells. Mucus is bactericidal, therefore it is protectant and beneficial, unless produced in sufficient quantity to induce mechanical injury. Epithelium and connective tissue are most frequently affected by this degeneration.

4. Serous degeneration, or more properly infiltration, is characteristic of tissues affected with inflammatory oedema or other inflammations in which there is excessive serous exudation. This condition results from the passage into the cells of extracellular serous fluid. The infiltrated fluid mechanically interferes with the activity of the cell. It occurs most frequently in muscular and connective tissue and occasionally in epithelium.

5. Hyaline degeneration is of common occurrence in tissues affected with chronic inflammation. It is the conversion of the tissue into a clear, waxy substance. It is common in the muscular tissue of blood vessels in chronic inflammatory foci as well as in fibrous tissue resulting from proliferative inflammation.

6. Amyloid degeneration has been observed in chronic inflammatory tissues (Adami), although this is not a common sequel of inflammation.

An intercellular degeneration specifically affecting the cement substances between the myocardial cells has frequently

been observed in myocarditis. This causes a separation of the heart muscle cells, i. e., fragmentation, which seriously interferes with their function. The striations of muscle cells frequently disappear as a result of inflammation.

Necrosis (local death).—All degenerations produce impairment of function and frequently end in necrosis of the affected cells. Destruction of tissue is a common result of inflammation because of the various degenerations that accompany the inflammatory process. Suppuration is a type of inflammation and is a liquifying necrosis. Necrosis of inflammatory tissue often occurs independently of suppuration, though both conditions result from the same cause. Destroyed tissue constitutes a factor in the future changes that occur in the affected tissue. Superficial necrotic tissue is usually cast off. Ulceration is the condition resulting from a continuous and sometimes a progressive cellular necrosis. An ulcer is a denuded surface resulting from continuous and sometimes a progressive cellular necrosis.

Subsurface necrotic tissue may be disintegrated or dissolved, and pass out of the affected area in the exudate or be carried out by phagocytes; necrotic tissue may become surrounded and permeated by large numbers of leucocytes which liberate dissolving ferments, thus forming an abscess; this liquefied necrotic mass may become inspissated, a condition termed caseation; the necrotic tissue may become impregnated with calcium salts, denominated calcification; finally, the necrotic tissue may become dissolved and encapsulated, thus forming a cyst.

Regeneration.—This process usually begins when degeneration ceases, although it may be evident from the first. Cells concerned in regeneration undergo a reversionary change, becoming similar to embryonic cells. Reproduction is an active, vital property of embryonic cells, and this is also the principal function of regenerating cells. The appearance of a tissue containing an exudate with the succeeding degeneration has been previously discussed. A concise comprehension of such tissue is essential to a clear conception of the appearance of regeneration in an inflammatory zone. Whether degenerated cells are capable of regeneration depends upon the kind of cells and the extent of the injury to them. Regeneration of tissues impaired or destroyed by acute inflammation consists in the enlargement and proliferation of the contiguous uninjured cells. The exudate is usually diminished in quantity at this stage. Proliferation in tissues affected with chronic inflammation is, in reality, a fibrous hyperplasia. Cirrhosis of any structure is usually the

result of chronic inflammation. The lowest types of tissues, i. e., those passive in function, are most easily and most frequently regenerated, e. g., connective tissue. Surface epithelium is frequently regenerated—muscular and nervous tissues

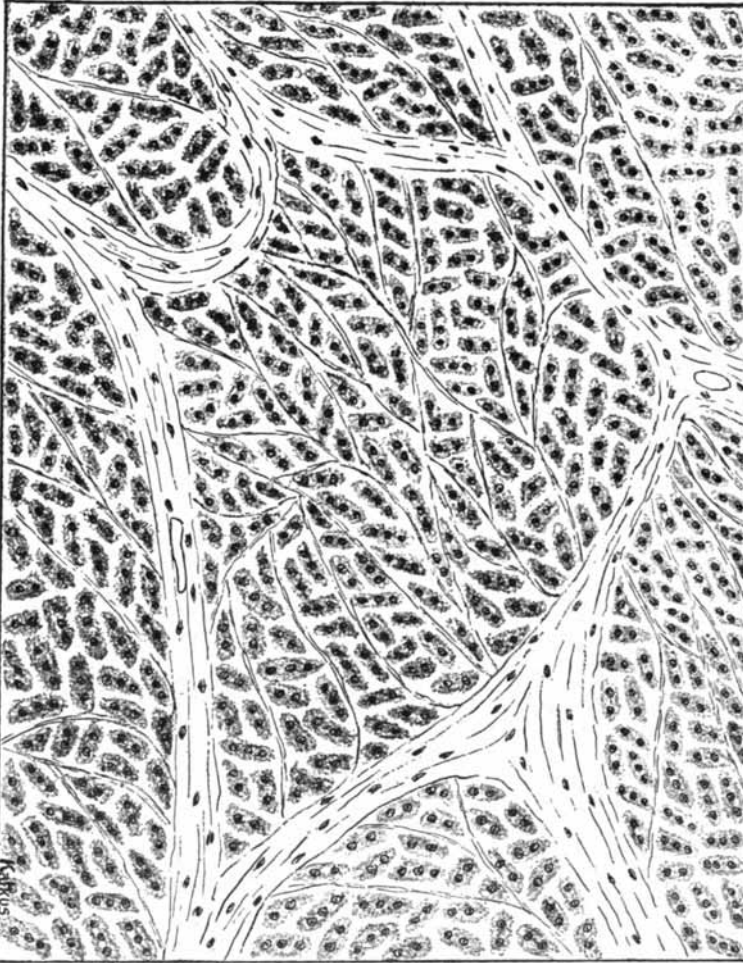


FIG. 100.—Chronic Hepatitis, showing intralobular fibrous formation, which results in hypertrophic cirrhosis.

are rarely regenerated. The age of the individual is an important factor in the regeneration of injured tissues. Tissues in young animals regenerate more readily than like tissues in old animals.

The origin or source of the cells that regenerate connective

tissue is still a disputed point. It is certain that fixed and wandering connective tissue cells are capable of this function. Endothelial cells are a type of fixed connective tissue cells which are active in regeneration of connective tissue. Mononuclear leucocytes as well as lymphocytes may be capable of producing connective tissue. The regenerating connective tissue cells (fibroblasts) are either oval or spindle shaped, the latter predominating, especially during the active regeneration period.

Endothelial cells are active in the production of new vessels. Inflammatory tissue is usually more vascular than normal tissue. In the vascularization of an inflammatory area the endothelial cells produce long protoplasmic projections. Several of these projections of different adjacent cells may fuse, thus forming an anastomotic channel, or a single projection may separate in a longitudinal direction, thus producing an extension of the old channel. As the protoplasmic projections become larger and longer there is an activity in the cell nucleus indicative of mitosis, and cell division soon follows. This process of protoplasmic projections and mitosis continues as long as the inflammatory process is active. The irregular blood channels (capillaries) so formed become surrounded by a layer of involuntary muscle tissues and yellow elastic tissue as a result of extension of muscle fibres and connective tissue cells from the adjacent vessel, the whole structure being surrounded by a loosely arranged layer of white fibrous connective tissue. Thus the capillary becomes an arteriole. These cells that are active in vascularization are designated angioblasts. They are the progeny of endothelium.

Inflammatory injuries to surface epithelium, as epidermis or mucous membrane, are usually repaired by multiplication of the cells bordering the injury.

Irregular masses of nucleated protoplasm have been observed in myositis and may represent regenerating muscle cells.

Kinds or Types or Inflammation.—It is difficult to classify inflammation because of the numerous variable factors that compose it. The following classification is based upon etiology, exudate, tissue involved, and time or severity of attack.

Etiology.—Etiologically, inflammation may be classified as simple and infective.

1. Simple inflammation is noninfective and results from mechanic, thermic, electric or chemic interference.

Fractures, sprains, bruises and surgical-procedure wounds are types of mechanic inflammation.

As types of thermic inflammation, burns and frozen tissues

may be mentioned. Local inflammatory disturbances resulting from lightning or contact with electric currents are types of electrically established inflammation. The following may be mentioned as chemic inflammations; formalin dermatitis, arsenical enteritis, chlorine pneumonitis, turpentine nephritis, and those induced by the bites of poisonous reptiles, scorpions, bees, wasps and ants; also those caused by the products of bacteria and animal parasites. The inflammatory processes established by mechanical interference may and usually do become infected either by external contamination or by the deposition of infectious agents from the blood or lymph.

2. Infective Inflammation is of more frequent occurrence than non-infective. It is the kind of inflammation that concerns the practitioner, veterinary inspector and sanitarian because of its tendency to become generalized in the infected animal, and is frequently transmissible to other animals. All tissues are susceptible to infective inflammation except hair, wool, feathers, and the insensitive, nonvascular portions of the teeth, hoofs, claws and horns. Infective inflammation may be either non-suppurative or suppurative.

(a) Nonsuppurative infective inflammation is typified in malignant oedema, blackleg, localized anthrax and the earlier stages of tuberculosis and actinomycosis, and is characterized by the general phenomena of inflammation previously discussed. Infective inflammation may be nonsuppurative in the earlier stages and in the later stages be complicated by typical suppuration, as in tuberculosis. More rarely nonsuppurative inflammation continues throughout the entire process, as in blackleg.

(b) Suppurative infective inflammation or suppuration.—Suppuration is liquefying necrosis, and may be surface or subsurface, circumscribed or diffuse. The liquefied necrotic tissue produced by suppuration is pus. Pus is a fluid, varying from a thin watery substance to a thick, sticky, tenacious mass, and is usually alkaline in reaction. The color of pus is determined by the infective agent, and it may be white, lemon yellow, golden yellow, greenish yellow, green or black, and is frequently tinted red with blood. Pus obtained from horses, donkeys and mules is usually white or grayish white; from cattle, creamy yellow; from sheep, greenish yellow, and from hogs, green or greenish yellow. Pus is usually odorless, although it may undergo putrefaction with the evolution of ill-smelling gases. Actinomycotic pus has a nutty odor (Mayo). Pus may have a greasy, smooth, sticky or granular feel when rubbed between the fingers, depending upon its composition.

Histologically, pus is composed of pus cells, i. e., leucocytes (the most of which are necrotic, though some of them may possess vitality), shreds of necrotic tissue and tissue cells (the type of which depends upon the tissue affected), usually pyobacteria in varying numbers (many of them being included in the pus cells) and liquor puris (the plasma or fluid portion of the exudate and the fluid resulting from the solvent action of the various ferments). Animal microparasites are found in the pus resulting from their activity. Practically all of the pus cells are derived from polymorphonuclear leucocytes, and are usually the neutrophile variety, there being only an occasional mononuclear leucocyte. Extensive nuclear fragmentation and parenchymatous and fatty degeneration of the cell protoplasm are evident in most pus cells, indicating that they have undergone necrosis. Degeneration or necrosis are also present in the fixed tissues of the suppurative areas. The pus found in acute abscesses or discharging from granulating wounds is usually a creamy fluid, yellowish in color. Sanious pus is a reddish fluid resulting from an admixture with blood. Ichorous pus is an acrid, corrosive fluid that excoriates the tissues it contacts. Muco-pus and sero-

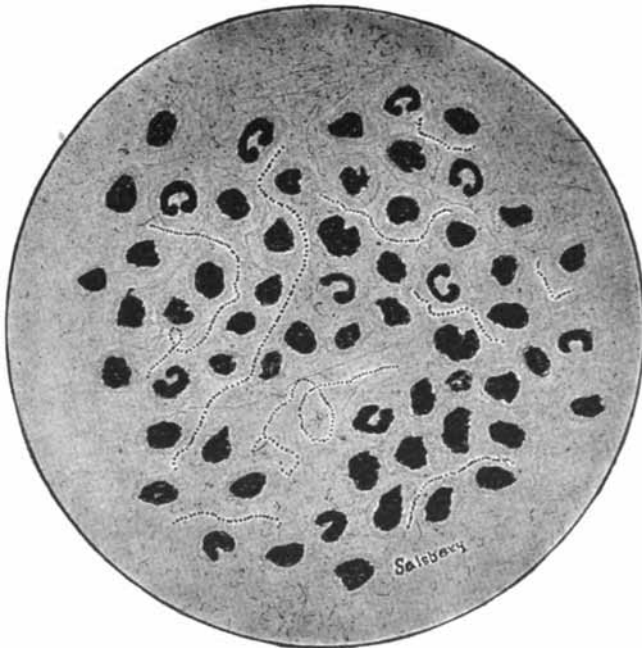


Fig. 101.—Drawing of a pus smear from a case of strangles, showing the organism arranged in chains—the *Streptococcus pyogenes equi*.

pus are mixtures of mucous and pus, and of serum and pus, respectively. Putrid pus is a thin, ill-smelling fluid, the result of putrefaction.

Infection is the usual cause of suppuration. The following is a brief description of the process. Pyogenic micro-organisms gain entrance either by deposition upon or into a wound by passing through the tissue or are carried and deposited by the blood or lymph, and, finding conditions favorable, develop and multiply. In their development, pyobacteria produce chemic substances that are sufficiently irritating to establish an active hyperemia and also to exert a positive chemotactic influence, the latter attracting at first mononuclear leucocytes and later causing the migration of neutrophilic polymorphonuclear leucocytes to the focus of infection. Multiplication of the pyobacteria and leucocytic immigration continue. Phagocytosis becomes evident in leucocytes and some other cells, e. g., endothelial cells. Liberated ferments, produced by the pyobacteria, leucocytes and other cells, cause degeneration, necrosis and, finally, solution of the tissue involved. Continued pyobacterial multiplication stimulates an increased leucocytic immigration, and the tissues are thus densely packed with cells. There is a marked accumulation of leucocytes around the suppurative focus apparently attempting to circumscribe the affected area. Thus the process continues, there being a progressive liquefying central necrosis within and a marginal leucocytic accumulation without. The condition is repeated until the resistant influences of the animal body destroy the pyobacteria, or until the pyobacteria have destroyed the involved tissue, or the entire animal. (Suppurative osteitis may occur subperiosteal or in the osseous tissue proper. Leucocytes invade the lacunae and produce solution of the mineral matter, and thus the bone becomes porous. If this process continues the bone ultimately liquefies; this is termed caries.)

Surface suppuration (purulent inflammation) is suppuration of a surface tissue. Pus produced in surface suppuration constitutes a purulent discharge, and a persistent purulent discharge is termed pyorrhoea. Inflammation of a mucous membrane accompanied by a purulent discharge is purulent catarrh. In purulent catarrh the surface epithelium is infiltrated with leucocytes frequently to such an extent that the epithelial cells are disintegrated, become loosened and exfoliate. The surface cells of serous membranes and the skin are similarly affected in purulent inflammation. In any purulent inflammation there is always

an engorgement of the subsurface vessels and the related areolar tissue is infiltrated with inflammatory exudate.

Subsurface suppuration may be circumscribed or diffuse. Suppurative centers become circumscribed first by a dense wall of leucocytes and later by a fibrous capsule. The capsule is in nearly all cases denser on the side next to the more important tissue. Fibroblasts that form the circumscribing fibrous capsule are probably the wandering connective tissue cells or their progeny. The collection of pus in tissues, or lymph spaces, and as considered by some in body cavities, constitutes an abscess. The circumscribed pus may, by solvent action of its ferments,

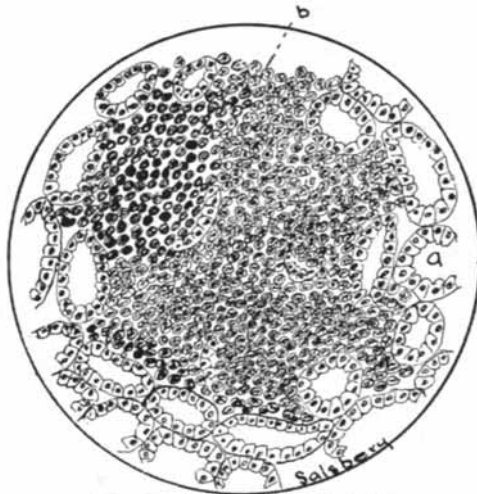


Fig. 102.—Suppurative Nephritis.
 a. Normal kidney tubule. b. Suppurative focus surrounded by kidney tissue.

dissolve or erode the limiting structure (cells or capsule), and be liberated; the erosive action being in the direction of the least resistance. In this way a surface discharge is effected. The channel of exit of the pus may persist and become circumscribed by a fibrous wall, thus forming a fistulous tract. If the pus cavity is completely evacuated by surgical interference or otherwise, and the cause removed, the surrounding tissue will, by proliferation, fill the space previously occupied by the pus. The pus in an abscess may be absorbed and the destroyed tissue be replaced by regeneration. If the capsule is exceedingly dense the contained pus may become caseated and calcified.

Abscesses may be classified as superficial and deep; primary or metastatic (metastatic abscesses may or may not be embolic), simple or multiple, subfascial and intermuscular. A hot abscess

results from rapid, active suppuration, as submaxillary abscesses in strangles, while the so-called cold abscess results from a slow suppurative process, as in tuberculosis. Accumulations of pus in body cavities as the peritoneal, pleural, pericardial, synovial and the facial sinuses constitute empyema. Vesicles may become infiltrated with leucocytes, which become pus cells, and thus the vesicle becomes a pustule.

Diffuse suppuration is not limited by any definite border line. It is the result of agencies possessing sufficient strength or virulency to continuously and progressively destroy and liquefy tissue or it occurs at a time when the resistance of the animal or its tissues is so greatly diminished that there is inability to successfully antagonize the causative agent. Purulent infiltration is the permeation of tissues with pus. Phlegmonous inflammation is the rapid and usually extensive infiltration of tissues with leucocytes (pus cells), and occurs most frequently in the subcutem and submucosa.

Exudate.—According to the nature of the exudate inflammation may be classified as serous, fibrinous, and hemorrhagic. The physical properties, chemic and histologic composition of inflammatory exudate has been previously discussed.

(a) Serous inflammation is characterized by a serous exudate. Inflammation of serous membranes and inflammatory disturbances of other tissues than serous membranes, caused by mild irritation, may be of this type. Occasionally serous inflammation is the result of intense irritation as in malignant oedema. The terms serous inflammation and inflammation of serous membranes should not be used interchangeably, because inflammation of serous membranes may be characterized by fibrinous or hemorrhagic exudate. A circumscribed accumulation of inflammatory serous fluid (exudate) in the deeper layers of the epidermis or mucosa constitute a vesicle. Inflammatory oedema, a serous inflammation, is the condition resulting from the diffusion of an excessive amount of inflammatory serous exudate into tissues as in cellulitis (inflammation of sub-cutem).

(b) Fibrinous inflammation designates that type of inflammatory disturbances in which there is produced a coagulable exudate. The exudate may coagulate within the tissues or upon the tissue surface. Croupous inflammation is the term applied to the condition resulting from the coagulation of the exudate upon a tissue surface. Diphtheritic inflammation is the condition produced by coagulation of the exudate within the tissue and upon its surface. Croupous inflammation and diphtheritic in

flammation are not distinctly separable although the former is usually milder than the latter. Typical croupous exudate may be detached without serious injury to the surface tissue but the diphtheritic exudate cannot be removed without detaching or extensively lacerating the surface tissue. Croupous pneumonia and croupous enteritis are examples of croupous inflammation, the former being the most frequent type of pneumonia in horses and the latter occurring occasionally in cattle. Roup or avian diphtheria, and diphtheritic stomatitis and enteritis are examples of diphtheritic inflammation, the former being common in fowls the latter in pigs. Fibrinous exudate may be present in inflammation of serous membranes, constituting fibrinous pleurisy, peritonitis, etc.

(c) Hemorrhagic inflammation is significant of the action of an extreme irritant. Hemorrhagic exudate coagulates, especially upon surfaces, though it may coagulate within a tissue. Inflammation of tissues in which the blood vessels are of meager structure (capillaries), and hence easily permeated or ruptured, is frequently of this type. Croupous pneumonia is a hemorrhagic inflammation. Nephritis and hepatitis are frequently accompanied by a hemorrhagic exudate.

(Mucus and pus have been described as inflammatory exudates by some and as inflammatory products by others.) They

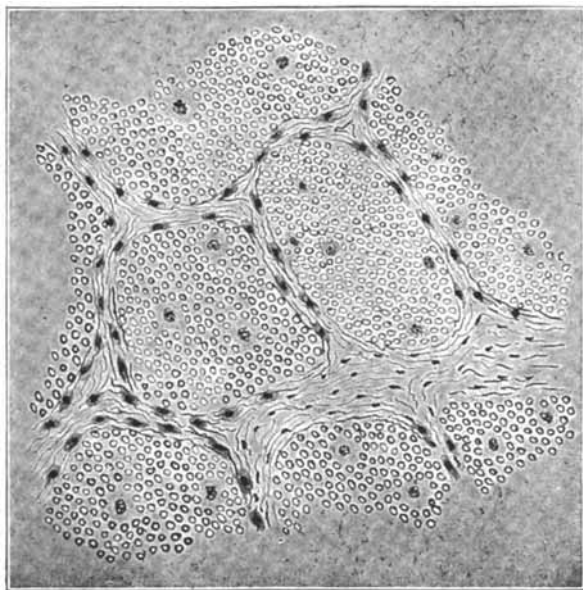


Fig. 103.—Hemorrhagic Exudate (Red Hepatization.)

are not inflammatory exudates. Inflammation of mucous membranes in which there is an excessive production of mucus is catarrh or catarrhal inflammation. (Suppuration is inflammation accompanied by the formation of pus and may be surface or sub-surface. Purulent inflammation is surface suppuration.)

Tissue.—Histologically a gland or organ is composed of parenchymatous and interstitial tissue. Parenchymatous tissue is the essential or functioning portion of a structure, as hepatic cells. Interstitial tissue or stroma is the supporting framework of an organ or part as the stroma of a lymph node. The process of inflammation may occur in either the parenchyma or stroma. Classifying upon the basis of tissue affected then, there are the two forms, namely, parenchymatous and interstitial inflammation.

(a) Parenchymatous inflammation is usually the result of severe, active irritation, the interstitial type results from the long, continued action of mild irritants. The two types may be present simultaneously in the same structure or they may occur independently.

(b) Interstitial inflammation is often the sequence of parenchymatous, although it may be the initial process. Inflammation of the hepatic cells is parenchymatous hepatitis, of the hepatic interlobular tissue, interstitial hepatitis, etc.

Time, Activity and Results of the Process.—It is questionable if the length of time an inflammatory process continues should constitute a factor in its classification. By common usage, inflammation would be classified according to the time basis, as acute and chronic. Formerly this classification was based upon the time element alone, but the duration of inflammation is so variable that it is now recognized as an insignificant factor. The activity and results of the process are the basic essentials relied upon in differentiating acute and chronic inflammation.

(a) Acute inflammation is characterized by a sudden onset, by a vigorous action and by production of retrogressive changes in or destruction to the tissue affected.

(b) Chronic inflammation is characterized usually by an insidious onset, by a mild action, and by resulting in proliferation of tissue. The proliferated tissue may induce retrogressive changes, as atrophy, but this is only an indirect result of the process.

Either acute or chronic inflammation may occur throughout the entire reaction or they may both prevail at the same time in different parts of the same structure. The causative agents may become less active as the process continues, thus acute inflam-

mation is often succeeded by chronic inflammation. Injuries of tendons are usually accompanied by acute inflammation, but this usually subsides early and is succeeded by chronic inflammation. Chronic inflammation may be succeeded by acute inflammation provided that the irritating factor be sufficiently increased or the resistance of the animal diminished.

Miscellaneous.—a. Catarrhal inflammation is inflammation of a mucous membrane, accompanied by an excessive production and discharge of mucus.

b. Purulent inflammation is characterized by the production of pus. This term is confined, by some, to surface suppuration.

c. Ulcerative inflammation is one in which there is erosion of surfaces, i. e., the production of ulcers.

d. Vesicular inflammation is one characterized by the presence of vesicles.

e. Pustular inflammation is one characterized by the presence of pustules.

f. Proliferative inflammation is practically the same as chronic inflammation. It signifies the production of new tissue.

g. Specific inflammation is one resulting from a specific infection, as glanders.

Termination.—The tendency of the reaction produced by an injury is always favorable, but the reaction may be so sudden and extensive or continued so long that its results may be harmful. The termination of inflammation depends upon the extent, intensity, and duration of the irritant and the resistance of the tissues. Inflammation may terminate in resolution, tissue proliferation or dissolution.

Resolution embraces the processes of repair and these may be summarized as follows:

a. Removal of the cause.

b. Re-establishment of circulation. This may be accomplished in a few hours or perhaps not for several days depending upon the extent of the injury and the kind of tissue injured.

c. Restoration of vessels to their normal condition. The length of time required for restoration and the completeness of the process depends upon the severity of the injury and the re-establishment of the circulation.

d. Removal of the inflammatory exudate. The time required to remove the exudate depends upon its nature. Serous exudates are usually removed by **resorption, i. e.,** by the lymph channels. Fibrinous and hemorrhagic exudates are usually dissolved and absorbed, or they may be carried away by phagocy-

tes. Exudates may in part be consumed as nutrition by local cells.

e. Disposal of necrotic tissue. Necrotic tissue is disposed of by sloughing, absorption, phagocytosis, or sequestration. Small areas of necrotic tissue are usually promptly absorbed or disposed of by phagocytic action. Considerable time is usually required in disposing of large areas or masses of necrotic tissue, unless it is superficially located and separates from the surrounding tissue and sloughs. Subsurface necrotic tissue may be gradually liquefied and absorbed, discharged through a fistulous tract (submaxillary abscess of Strangles), collected and carried out by phagocytes, encapsulated, or sequestered, and remain permanently in the tissue. Encapsulated necrotic tissue may become infiltrated with calcium salts.

f. Regeneration of degenerated tissue and replacement of necrotic tissue. The regeneration of degenerated tissue consists in replacing the injured or destroyed cell protoplasm by normal protoplasm. If only a few cells are destroyed the adjacent cells reproduce and thus renewal is usually rapid. Connective tissue cells and surface epithelium are easily and efficiently regenerated, but cardiac muscle, ganglionic nerve and cartilage cells are rarely perfectly regenerated. Large areas of necrotic tissue are usually substituted by fibrous tissue. This proliferated tissue is termed granulation tissue in the beginning and cicatricial tissue after it has become dense and more or less contracted. Granulation tissue consists of capillary loops surrounded by masses of cells. These cells are largely fibroblasts and produce fibro-connective tissue. After the fibro-connective tissue has been formed it contracts, thus becoming cicatricial tissue. Cicatrization is of value in closing gaping wounds, but is injurious when it occurs in internal organs as the liver, because the pressure produces atrophy and obstructs circulation. The capsule surrounding pus cavities, after the purulent fluid has been evacuated, becomes a granulating membrane which soon fills the gap with fibrous connective tissue. Exuberant granulation results from excessive multiplication of cells, undue extension of capillary loops, and failure of contraction of the fibrous tissue.

Tissue Proliferation.—The tissue proliferated in inflammatory resolution takes the place of tissues that pre-existed and had become necrotic, while that occurring in inflammation resulting from long continued mild irritation is not a substitution but an addition to the tissue already existing. In this latter phase tissue proliferation may begin in a very short time after the inflammation is established or it may not appear for two, three,

or several days. Fibro-connective tissue is invariably the product of tissue proliferation. Fibro-connective tissue proliferation is closely associated with chronic inflammation, in fact it is almost inseparable from it. The proliferated tissue appears first in the frame-work of the tissue involved and may later extend into the parenchymatous tissue. If the proliferated tissue is excessive it may, by pressure, produce atrophy of the parenchymatous tissue. Cicatrization of the proliferated tissue causes an irregular lobulation and constriction of the involved organ, as in cirrhosis of the kidney. Strictures of hollow organs are produced in the same way. Adhesions of serous membranes are produced by fibrous tissue formed during inflammation.

Dissolution or destruction is a result of intense irritation. Necrosis of tissue is frequently a sequence of inflammation. A single cell or only a few cells may be destroyed or large areas of tissue may undergo necrosis. Ulceration results from constant cellular necrosis. Circulation may be obstructed by an inflammatory exudate and cause necrosis in large masses of tissue. It may terminate fatally, in partial recovery, or in resolution, depending upon the importance of the tissue involved in the affected animal.

Conclusion.—Inflammation is the reaction of a living tissue to an irritant.

Inflammation is a complex process, the result of many factors.

It is not always a result of infection.

It is an adaptive, reparative and protective process.

It may produce sufficient reaction to cause destruction of the portion involved and occasionally of the entire organism.

CHAPTER VII. PROGRESSIVE TISSUE CHANGES.

REGENERATION.

DEFINITION.

EXTENT—Depends upon age and tissue involved.

Blood.

Connective tissue.

Fibrous.

White.

Yellow.

Cartilage—Rarely regenerated perfectly.

Bone.

Epithelium.

Surface—Complete and perfect.

Glandular—Irregular and incomplete.

Muscle—Perfect regeneration rare.

Nerve—Cells do not regenerate, fibres do.

Regeneration is the process by means of which destroyed tissues are replaced. Tissue destruction is the result of necrosis, primarily, and inflammation and degeneration, secondarily. Regeneration is accomplished by multiplication of pre-existing adjacent cells or by invasion and multiplication of wandering connective tissue cells. The proliferating cells assume the characteristics of embryonal cells, that is, their reproductive property is over-developed and their other vital functions depressed. The power of regeneration of a tissue is inversely proportional to its specialization. Regeneration of the tissues of the less complex animals is more nearly perfect than that of the tissues of highly organized animals; thus invertebrates regenerate entire organs or parts. Spallanzani cut off the legs and tail of a salamander and observed in the course of three months six crops of these members. In the entire three months 687 perfect bones were reproduced and the regeneration was perfect regardless of the point of amputation. The tissues of young growing animals are more easily regenerated than those of mature animals. Single cells or small areas of tissue are more perfectly regenerated than large areas. In some cases destroyed tissues are not regenerated but are replaced by fibrous tissue. The functions of some destroyed tissues and organs may be performed by other structures. Thus, if the tibia of a dog is destroyed, the fibula increases in size and assumes its function. Destruction of one kidney is succeeded by a compensatory hypertrophy of the other

kidney. The law of specificity, i. e., cells beget like cells, is the same in regeneration and in physiologic processes. Regeneration is the outcome of the unhindered multiplication of cells.

Blood is continually regenerated during the natural life of an animal. The normal maintenance of blood is a physiologic process, but regeneration of blood or some of its constituents may, under certain conditions, be abnormal, as in leukemia. Leucocytes are produced in lymphoid tissue of the lymph nodes, spleen and bone marrow, and it is possible that they may multiply in the tissue spaces. Erythrocytes probably have their origin in the red marrow of bones in adult animals. The red blood corpuscles are nucleated in the beginning but the nucleus vanishes by solution or extrusion before the cells reach the general circulation except in case of severe hemorrhage or other conditions in which there has been rapid, extensive loss or destruction of blood.

Blood vessels are usually the first tissue regenerated in the repair of wounds. Blood vessels are formed in the embryo by canalization of large mesodermal cells, many of which fuse, thus forming continuous canals that later become blood vessels. This

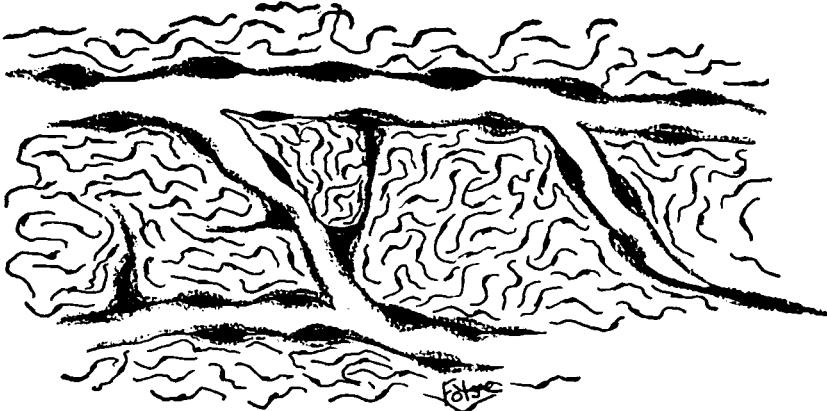


Fig. 104.—Vascular Regeneration, showing vascular buds.

type of vascular formation is not common in repair of injured vessels or regeneration of destroyed vessels. The usual manner of vascular regeneration is by the growth and development of endothelial buds from adjacent vessels. These buds are solid, conical processes which extend outward from the capillary endothelium. The buds or processes increase in size and become hollow at their base, the cavity being thus continuous with the lumen of the pre-existing vessel. As the buds increase in size

there is an increase in the number of cells composing them. Union or fusion of buds or processes from different vessels results in anastomosis or inosculation. These processes are thus the forerunners of capillaries and by a dilatation and an increase in the thickness of their walls due to formation of fibrous and muscular tissue, arteries and veins are formed. The new vessels produced in the repair of an injury are invariably in excess of the normal vascular requirements of the part. The excess vessels in an injured area are obliterated by cicatrization.

Connective tissue is usually completely regenerated. Connective tissue is regenerated from pre-existing connective tissue cells, wandering cells and endothelial cells.

Mucoid connective tissue is not normally found in the adult animal except in a modified form in the vitreous chamber of the eye. Mucoid tissue is not regenerated, although it is possible that other types of regenerated connective tissue are mucoid in the beginning.

Fibrous connective tissue is rapidly and completely regenerated. White fibrous connective tissue is frequently substituted for other tissues. The fibres in regenerated fibrous con-




Fig. 105.—Fibrous Regeneration.

nective tissue have the same origin as those in normal fibrous tissue. Regeneration of white fibrous tissue may be studied in the union of the ends of a tendon after tenotomy. The space between the ends of the tendon is filled with blood and lymph which escaped from the severed vessels. The pre-existing connective tissue cells bordering the wound in the tendon, together with wandering cells, begin proliferating within forty-eight hours, their progeny being fibroblasts. The fibroblasts produce a tangled mass of fibrous connective tissue, and at the same time there is vascularization of the extravasate which occupies the space between the severed ends of the tendon. After the ends

of the tendon are firmly united by the mass of newly formed fibrous tissue the extravasate and the fibres, excepting those extending in a longitudinal direction, are absorbed. Finally the repair is so complete that the defect is not visible to the unaided eye and is difficult to detect microscopically. Scars are bands, sheets or masses of white fibrous tissue and indicate imperfect regeneration, the fibrous tissue in scars being largely a substitution tissue.

Yellow elastic tissue is not as perfectly regenerated as white fibrous tissue. White fibrous tissue usually is substituted for yellow elastic tissue when the latter has been destroyed.

Regeneration of cartilage is very imperfect probably because of its irregular supply of nourishment. Destroyed cartilage is usually replaced by fibrous tissue. In some instances injuries to cartilage are succeeded by excessive cartilaginous proliferation. A case was observed in which the arytenoid cartilage was severed in an operation to relieve roaring; six months later there had developed at the point of operation a cartilaginous mass as large as a goose egg. Perfect regeneration of cartilage does occur, although it is rare. Regenerating cartilage cells are derived from the inner portion of the perichondrium. Fibrous tissue formation usually precedes the regeneration of cartilage, although it may be formed from the beginning.

Osseous tissue is usually perfectly regenerated. The cells that produce osseous tissue are called osteoblasts. Osteoblasts are usually derived from the osteogenetic layer of the periosteum, although they may have their origin from undifferentiated connective tissue cells. The formation of osseous tissue is usually preceded by mucoid, fibrous or cartilaginous tissue. The various stages of osseous regeneration are very similar to those of normal bone formation. Osseous regeneration may be illustrated by the union of a fracture as follows: Blood and lymph vessels are ruptured when the fracture is produced. Blood and lymph escapes into the surrounding tissues and the interstice between the two ends of the fractured bone. The injury produces necrosis and establishes inflammation. Vascularization of the injured area initiates the process, after which there is solution of the extravasate, exudate and necrotic tissue. Osteoblasts accompany the newly formed vessels and produce irregular masses of fibrous tissue which later calcify. The calcareous tissue is infiltrated with osteoclasts derived from the blood which dissolve out regular canals in the regeneration of long bones, and irregular cavities in the regeneration of flat or irregular bones. Osteoblasts appear in the canals and cavities, formed

by the osteoclasts, and produce fibrous lamellae which are later calcified. This process continues until the canals or cavities are filled with lamellae excepting a small central cavity which contains blood vessels, thus Haversian systems are frequently completely regenerated. Excess of osseous tissue formed over and around bones at the line of fracture (provisional callous), is usually later reabsorbed.

Adipose tissue is not a typical primary tissue. It is derived from the undifferentiated connective tissue cells by the conversion of their protoplasm into fat. Adipose tissue is consumed when the food supply is deficient, and the cells become typical connective tissue cells or are destroyed. Adipose tissue is also formed when the food supply exceeds the demand as a result of production and accumulation of fat in the connective tissue cells.

Dentine is not replaced except in some of the lower animals.

Epithelium of surfaces is constantly destroyed and regenerated. The outgrowth and shedding of the superficial epidermal cells is a physiologic process. Epithelization of small abrasions of the epidermis and mucous membranes is rapid and complete, the regenerating cells having their origin from the epithelium bordering the injury. If the denuded surface is large regeneration may proceed from the cells of the sweat glands of the skin, or mucous glands of mucous membranes as well as the epithelium bordering the injury.

Squamous epithelium is more completely regenerated than columnar. Constant destruction of columnar cells may cause the production of short columnar cells and finally squamous cells. This, however, is rare, as the law of specificity is practically without exception. Glandular epithelium is not regenerated as perfectly as surface epithelium (excepting the sweat glands, oil glands, mucous glands, gastric glands, Brunner's glands, crypts of Lieberkühn and uterine glands). Any of the foregoing will regenerate from small islands of cells either in the duct or body of the gland. The epithelium of the mammary gland increases in amount during lactation and diminishes when lactation ceases. By observation it has been determined that mammary epithelium regenerates after it has been destroyed by abscess formation or other destructive processes, provided newly formed fibrous tissue is not substituted. By analogy it might be supposed that the destroyed epithelium of salivary glands and of the pancreas may be regenerated, but this has not been clinically or experimentally demonstrated. The liver is a tubular gland and regeneration of a single cell or a few cells is not

uncommon, but large areas of liver tissue are probably never regenerated, although some pathologists claim that they have observed the regeneration of the major portion of a liver lobe in the dog, cat and rabbit. Kidney cells, especially of the tubules, are constantly regenerated, although the regeneration of an entire tubule has never been observed. The testicular and ovarian tissues are probably never regenerated except in the physiologic maintenance of spermatogenesis and oögenesis.

Muscular tissue is imperfectly regenerated. Injuries of involuntary muscular tissue are usually repaired by the substitution of fibrous tissue which may later be replaced by involuntary muscular tissue, the latter being derived from the adjacent muscle cells. Two or three days after an injury to a voluntary muscle fibre, the nuclei near the injury divide and a multinucleated protoplasmic mass is formed on the damaged fibre. These protoplasmic masses extend into the substituted fibrous tissue and may split longitudinally into regular fibres but more frequently they die and disintegrate. Destroyed heart muscle cells are invariably replaced by fibrous tissue.

Nerve cells are not regenerated, at least in adult animals, although their processes, axones and dendrites, are regenerated in peripheral nerves. After a nerve fibre is injured the axone degenerates to the distal end and to the first or second node of Ranvier proximally. A few days after the injury the axone, if its continuity has not been destroyed, begins to elongate, extending peripherally, in the direction of least resistance, which is in the old sheath. If the axone extends in the original sheath the tissue deprived of its nerve supply may become perfectly innervated. The rate of growth of an axone has been variously estimated at from .1 mm. to 1mm. in twenty-four hours. Foot lameness in horses that has been completely relieved by metacarpal and metatarsal neurectomies, sometimes reappear, in from eighteen months to three years after the operation, thus indicating that there has been reinnervation. If the proliferating axone does not continue in the original nerve sheath it may become entangled and coiled up in the scar tissue, of the wound, thus producing sensitive scars and amputation neuromata.

WOUND HEALING.

DEFINITION.**CLASSIFICATION.***Etiology.**Traumatic.**Thermic.**Chemic.**Location.**Surface.**Subsurface, (Cephalic, cervical, thoracic, etc.)**Character.**Incised.**Punctured.**Lacerated.**Contused.**Stab.**Gun shot.**Bites.**Condition.**Aseptic.**Septic.***HEALING.***Primary union, (First Intention.)**Hemorrhage arrested.**Approximation of wound margins.**Adhesion of wound lips with exudate.**Multiplication of related cells.**Vascularization.**Epithelization.**Secondary union, (Second Intention.)**Hemorrhage arrested.**Immigration of leucocytes to wound margins.**Infection.**Suppuration.**Granulation.**Cicatrization.**Epithelization.*

The regeneration of the individual tissues has been discussed. The simultaneous regeneration of the tissue-complex of an area in which there has been previous tissue destruction constitutes wound healing. A wound is the result of sudden interruption of the continuity of tissue or tissues. Some have restricted the term 'wound' to those conditions resulting from traumatisms; others confine it to injuries of soft tissue, and again some maintain that wounds occur only upon a surface. There is no good reason for restricting the term, because both thermic and chemic influences produce tissue destruction not distinguishable from wounds mechanically inflicted. A fracture is a break in the continuity of osseous tissue and is repaired in the same way as wounds of soft tissue. Rupture of the liver or spleen is characterized by tissue destruction and regeneration, the entire process being identical with that in surface wounds. Wounds result from sudden and violent action. Thus ulcers or necrotic

tubercular centers are not wounds. A bruise may or may not be a wound, depending upon the nature of the lesion, i. e., whether or not the interruption of tissue has been affected.

Wounds may be classified as to *cause, location, character, and condition.*

1. Etiologically wounds may be traumatic, thermic or chemic.

2. According to location wounds may be, surface or subsurface, abdominal, cervical, thoracic, etc.

3. As to their character, wounds may be incised, punctured, lacerated, contused, stab, shot, or bullet and from bites.

4. Wounds may be noninfectious and infectious.

Traumatic wounds usually heal more readily than wounds resulting from thermic or chemic causes because traumatism is caused by mechanical force only and the destructive influence ceases immediately upon removal of the cause; whereas the influence of thermic and especially chemic causes are more lasting as their action continues after the wound has been produced.

Wound healing may be of one of two types, healing by primary union (first intention), and healing by granulation (second intention or secondary union). These two modes of healing differ only in extent. Other methods of healing have been described as immediate union, healing by third intention, and healing under a scab. Immediate union, signifies union of parts of a cell or the cut ends of fibres, etc., and is now thought to be impossible; healing under a scab and healing by third intention are properly discussed under the caption of primary union or granulation.

Healing by Primary Union.—This is the most desirable method of wound healing and is usually obtained in veterinary practice only in surgical wounds and recently inflicted, clean cut wounds. This mode of healing is of short duration and is accompanied by little if any infection and limited inflammation. Healing by primary union takes place only in clean cut wounds, i. e., when the tissues are smoothly and evenly divided and in which hemorrhage is limited and easily controlled. After hemorrhage ceases or has been arrested the extravasate coagulates thus agglutinating and drawing the wound margins together. If the incised surfaces or severed tissues be approximated by surgical procedure the coagulated extravasate and exudate assists in maintaining them in that position. In surface wounds varying quantities of serum and lymph discharge and coagulate upon the surface thus forming a scab. The injury producing the wound and the extravasate are sufficiently irritating to es-

establish hyperemia and in some cases slight inflammation accompanied by a serous exudation and a leucocytic immigration. The hemorrhagic extravasate is gradually disintegrated and removed by phagocytes and at the same time, there is enlargement and extension by multiplication of the marginal tissue cells of the wound into the coagulum which serves as a support for the regenerating tissue.

Vascularization accompanied by fibrous formation initiates the process of regeneration in the healing of a wound by primary union. Vascularization is usually limited because of the small size of the wounds. The newly formed vessels are capillaries and supply the regenerating tissue. Fibrous tissue is produced in sufficient quantities to replace all tissues destroyed.

Disintegration of the coagulum and regeneration of new tissue thus proceed until the newly formed tissue has entirely replaced the extravasate. The scab is firmly held upon the wound

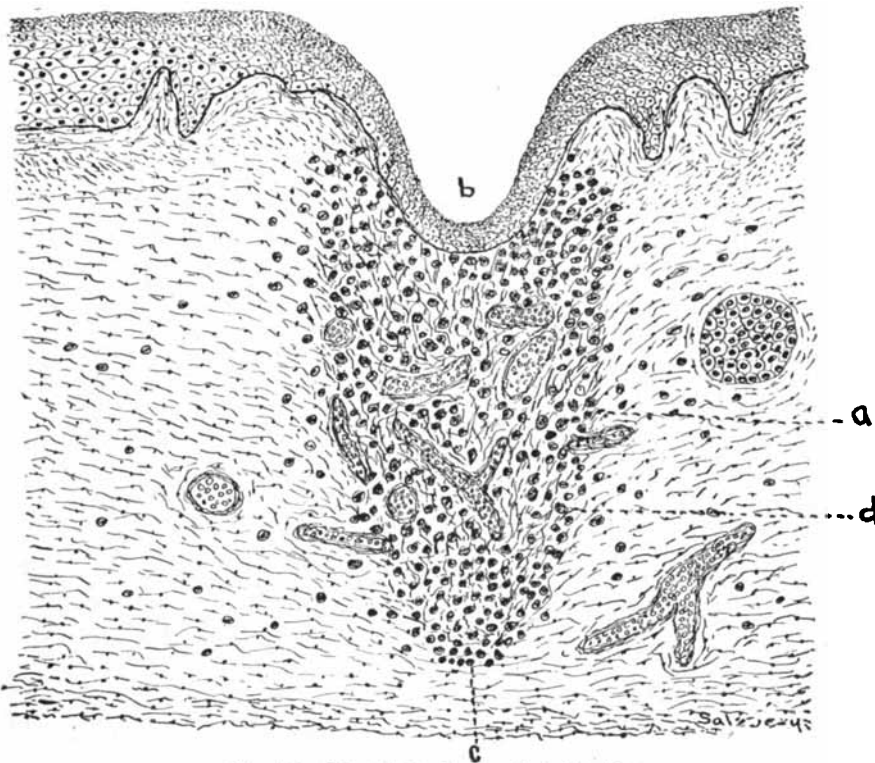


Fig. 106.—Wound Healing by first intention.

- a. Fibrinous exudate with proliferation of vessels.
- b. Regeneration of epithelium.
- c. Bottom of wound.
- d. Leucocytes.

by fibrils continuous with the coagulated extravasate and as the latter is absorbed the scab gradually becomes loosened and finally drops off leaving a shining surface. The regenerated tissue formed in the extravasate is embryonic fibrous tissue the amount of which depends upon the quantity of coagulum. Upon the embryonic tissue thus formed, in surface wounds, epithelization is usually rapid and complete. The scar appears pale pink and is tender until cicatrization takes place and then appears white, dense, firm and hard. Whether the fibrous tissue produced in wound healing is substituted later by the normal tissues of the part involved depends upon the generative power of the tissues destroyed.

To recapitulate, healing by primary union embraces, coagulation of the hemorrhagic extravasate, agglutination of the wound margins, hyperemia, inflammation, vascularization, fibrous formation, disintegration of the hemorrhagic extravasate and inflammatory exudate, cicatrization, epithelization and substitution.

Healing by granulation.—This is the usual mode of wound healing in domestic animals. It differs from the healing by primary union in that there is invariably infection and suppurative inflammation, degeneration and necrosis preceding regeneration. This mode of healing takes place in irregular wounds having lacerated margins and in which there is considerable destruction of tissue and extensive hemorrhage and in wounds the margins of which are not approximated. The extravasated blood may coagulate in the wound, especially in subsurface wounds, and also in surface wounds in which the margins are approximated and retained by mechanical means, such as sutures, adhesive tape, etc. In lacerated or gaping surface wounds, as wire cuts, the coagulum becomes detached and drops out leaving the wound margins covered by a thin layer of coagulated serum. Within a short time after the injury is inflicted there is extensive leucocytic immigration into the tissues bordering the wound. The infective micro-organisms cause destruction and solution of the marginal cells until the tissue resistance or local immunity checks their activity. Upon the exposed wound surfaces there appears velvet like projections (granulations), which are capillary loops regenerated from adjacent vessels.

Between and intermingled with the granulations, regeneration of connective tissue takes place. Constant exposure of the wound insures continued infection which retards the granulation more or less, depending upon the extent of the infection.

the degree of activity of the micro-organisms and the resistance of the tissue. The destroyed tissue in the wound is ultimately replaced with granulation tissue and, if the wound is upon the surface, epithelization proceeds as in healing by primary union. The embryonic granulating connective tissue contracts i. e.,

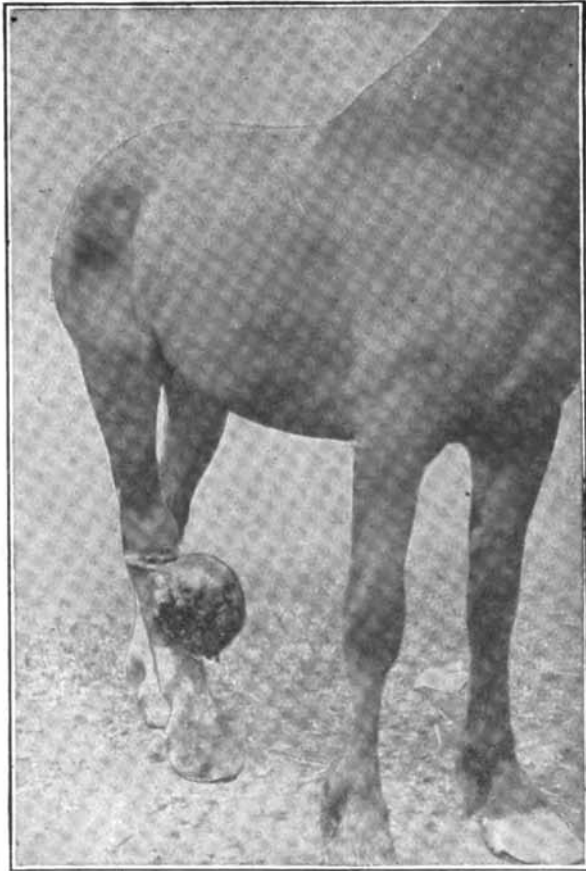


Fig. 107.—**Exuberant Granulation**, resulting from wire cut.

cicatrizes about the time that epithelization occurs. Cicatrization constricts and obstructs the capillary vessels, that are in excess of the normal, thus diminishing the blood supply. If cicatrization does not occur new capillary loops (granulations) are rapidly extended producing a fungoid bloody growth, called excessive or exuberant granulation (proud flesh).

The efficient regeneration and substitution of the destroyed

tissues in wounds that heal by granulation is possible only in very young animals and in tissues not highly organized.

To recapitulate, healing by second intention embraces sup-
puration, granulation, cicatrization, epithelization and substi-
tution.

In some individuals the formation of fibrous connective tis-
sue is continuous and there is formed large masses of cicatrical
tissue known as keloids. Keloids are classified with neoplasms
by some authors.

HYPERTROPHY.

ETIOLOGY.

Antenatal.

Unequal pressure.

Amniotic adhesions.

Post-natal.

Increased nutrition.

Increased function.

Internal secretion.

Diminished pressure.

APPEARANCE.

Macroscopic.

Microscopic.

TISSUE AFFECTED.

EFFECTS.

Hypertrophy literally means excessive nutrition. By usage
the term has come to mean, an abnormal increase in the size of
an organ or part. In a more restricted and definite sense, hy-
pertrophy is a term applied to that condition resulting from an
abnormal increase in the size of the essential cells of the part.
Thus an increase in the size of the liver as a result of an in-
creased amount of the interstitial tissue or an increase in the
size of a kidney due to an accumulation of an inflammatory ex-
udate or oedematous transudate is not an hypertrophy, al-
though such conditions have been called false or pseudo-hyper-
trophy. Tumors produce an increase in the size of the struc-
ture affected, but this should not be confused with hypertrophy.
Hyperplasia is a condition resulting from abnormal increase in
the number of the cells though it is difficult to differentiate
from hypertrophy.

COMPENSATORY HYPERTROPHY is the name applied to that type
of hypertrophy caused by increased functional activity. Thus
an increased blood pressure maintained for some time induces
compensatory hypertrophy of the heart.

CONCENTRIC HYPERTROPHY is a term denoting an hypertrophy of

the tissues of a hollow organ, accompanied by a diminution in the lumen of the hollow organ, e. g., hypertrophy of the heart, oesophagus, intestine, or any other hollow organ in which the hypertrophied tissues occupy a portion and thus diminish the lumen of the organ.

In some instances hypertrophy represents a normal, physiologic process. The increased size of the pregnant uterus, and the enlargement of the mammae during the gestation period are examples of physiologic hypertrophy. Increased size of the heart and voluntary muscles in horses trained for racing represents a physiologic hypertrophy. After the destruction of one kidney by disease or the removal of one by operation, the remaining kidney increases in size and ultimately performs the function of both, this is functional or physiologic hypertrophy and also compensatory hypertrophy. In fact practically all hypertrophies are physiologic, however, the hypertrophied structures are abnormal, therefore the condition is pathologic.

Excessive development of an entire animal i. e., giantism is designated by some as general hypertrophy.

Excessive development of a part as one foot is designated local hypertrophy. Local hypertrophy is much more common than general hypertrophy.

Hypertrophy may be inherited, (natural) or acquired. Acquired hypertrophy may be antenatal or postnatal.

Etiology.

INHERITED HYPERTROPHY.—The cause of inherited hypertrophy is unknown except that there is an inherited impulse to grow large. This type of hypertrophy is noted in giants.

ANTENATAL HYPERTROPHY is usually the result of unequal pressure and amniotic adhesions.

THE CAUSATIVE FACTORS OF POSTNATAL HYPERTROPHY are, 1st, increased nutrition, 2nd, increased function, 3d, a stimulus, probably an internal secretion, that causes the affected tissue to consume excessive quantities of food. Two or more of these etiologic factors are usually evident in all cases of hypertrophy.

Increased nutrition.—A long continued, mild arterial hyperemia in a tissue insures increase of the nutritive supply to the affected part and such parts usually become hypertrophic.

Increased function is the prime causative factor of physiologic or functional hypertrophy. Increased function is intimately associated with increased nutrition, in fact long continued increased function without increased nutrition is not possible. In the production of functional hypertrophy the part must be

accustomed to the extra work gradually. An excessive amount of work, assumed at once, by any structure will produce atrophy or degeneration. Cardiac hypertrophy is invariably functional as it usually is the result of valvular defects. Hypertrophy of the involuntary muscle anterior to a stricture is also functional as it results from increased muscular action to force the contents of the intestine past the stricture. Voluntary muscular hypertrophy is also functional.

Some unknown cause is active in the production of certain hypertrophic conditions. This unknown cause is probably an internal secretion, at least this would appear to be the cause of hypertrophy of the mammae and uterus in pregnant animals. That certain internal secretions are required to sustain the normal balance in the growth of tissues is evident in disease of the pituitary body which frequently results in excessive development of certain parts (acromegaly).

By diminishing the external pressure, experimentally, some parts have been noted to become hypertrophic. This is because of arterial hyperemia produced by diminished pressure.

Appearance.

Macroscopically, hypertrophied organs or parts are larger and heavier than normal and may be regular or irregular in shape. The general appearance of hypertrophied parts other than size is not usually sufficiently distinct to differentiate them from normal.

Microscopic.—Renal compensatory hypertrophy is characterized by increased length and size of the uriniferous tubules. Hypertrophy of muscular tissue is characterized by increase in the size of muscle cells. In general hypertrophied organs or parts contain an excess of parenchymatous tissue.

Effects.—The effect of hypertrophy varies according to the tissue affected. There is usually an increased functional capacity in an hypertrophied structure. The heart musculature may become hypertrophied to such an extent that its force ruptures some important blood vessel and causes death. Increased function of hypertrophied suprarenal bodies tends to increase blood pressure by the production and elimination of large quantities of adrenaline which causes constriction of arteries and cardiac dilation or rupture.

HYPERPLASIA.

DEFINITION.**VARIETIES.***Parenchymatous.**Interstitial.***ETIOLOGY.****APPEARANCE.***Macroscopic.**Microscopic.***TISSUE AFFECTED.****EFFECTS.**

Hyperplasia, according to the derivation of the word, is excessive formation. Hyperplasia and hypertrophy are incorrectly used interchangeably by some. Hyperplasia should be used to designate the condition resulting from an abnormal increased size of a part due to an increase in the number of cells of the part. Accepting the last definition, hyperplasia may be due to an increased number of parenchymatous cells, or an increased number of interstitial cells the two types being called parenchymatous hyperplasia and interstitial hyperplasia respectively. Parenchymatous hyperplasia and numerical hypertrophy are sometimes used synonymously. Interstitial hyperplasia is practically the same as fibrous hyperplasia.

Parenchymatous hyperplasia is not of common occurrence. It is usually either inherited or congenital. The descended or scrotal testicle of single cryptorchids is usually enlarged because of an increased amount of parenchyma and hence is an example of parenchymatous hyperplasia.

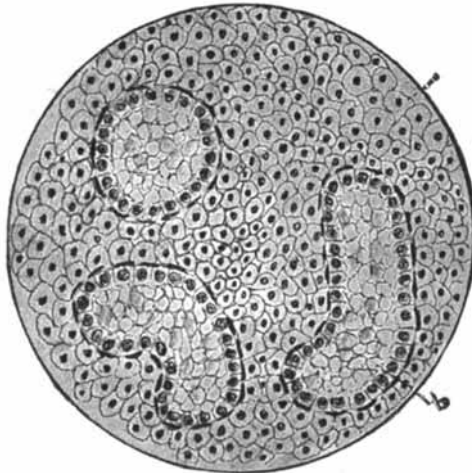


Fig. 108.—**Hyperplasia Interstitial Testicular Cells.**
 a. Interstitial hyperplastic tissue. b. Seminiferous tubules not fully developed.

Interstitial hyperplasia is quite common as it is usually evident in chronic inflammatory tissues and it is also occasionally observed in structures affected with functional fibrosis as is evident in the liver of animals afflicted with disturbances of the cardiac valves.

Etiology.

The cause of parenchymatous hyperplasia is unknown. Interstitial hyperplasia is produced by the long continued action of mild irritants or other substances that produce over stimulation.

Appearance.

Macroscopic.—Parenchymatous hyperplastic structures are regularly or irregularly enlarged and are heavier than normal.

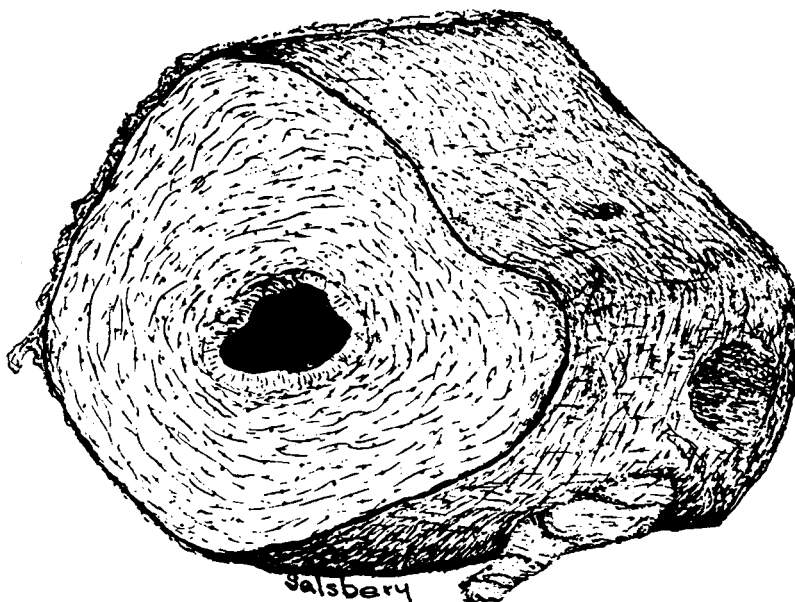


Fig. 108.—Pen drawing of an **Hyperplastic Ureter**, ox, natural size.

Interstitial hyperplastic parts vary in appearance according to the amount of hyperplastic fibrous tissue. The part may vary from normal to dense, hard, pale irregularly lobulated masses of fibrous tissue.

Microscopic.—Parenchymatous hyperplastic structures have the same appearance microscopically as sections of normal tissue.

Sections of tissue affected with interstitial hyperplasia contain an increased quantity of fibrous tissue which may be readily

recognized microscopically especially if the section is stained with hematoxylin and picro-fuchsin.

Effects.

A part affected with parenchymatous hyperplasia will have an increased functional capacity. The effects of an increased functional capacity of a structure depends upon the part involved, and may or may not be injurious to the animal in which it occurs.

Interstitial hyperplastic structures have an increased quantity of fibrous tissue and usually a diminished amount of parenchymatous tissue and a diminished function. Interstitial hyperplasia of the walls of hollow organs may cause irregularity of the lumen (intestine) and hinder passage of the organ's contents.

METAPLASIA.

Metaplasia is the name applied to the conversion of a developed or matured tissue into another closely related. Under normal conditions a matured tissue has specific cells and a characteristic structure. The character of a tissue may be changed by certain pathologic conditions. Metaplasia should not be con-

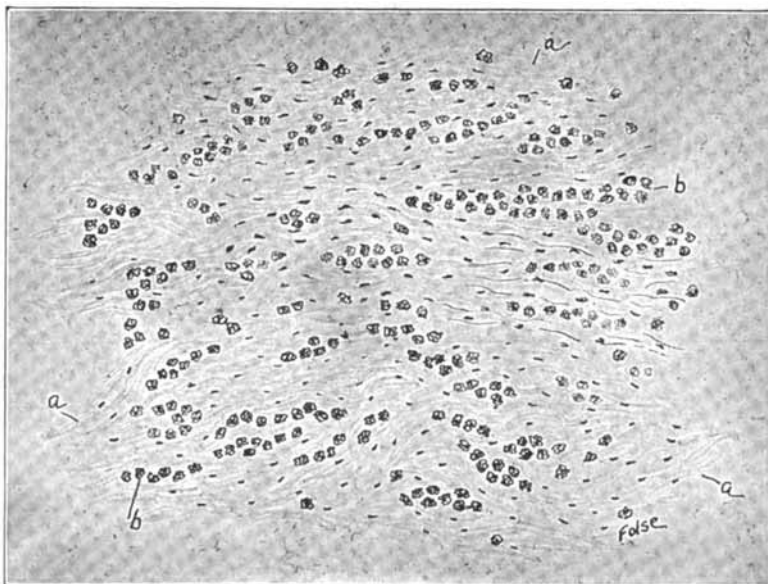


Fig. 110.—Fibrous Tissue Ossification.
a. Fibrous tissue. b. Osteoblasts.

fused with degenerative or infective tissue changes which are observed in functional or inflammatory fibrous formation. Metaplasia is usually concerned in the conversion of one variety of a primary tissue into another variety of the same tissue as fibrous tissue into bone and occurs in physiologic processes as well as in disease.

Metaplasia occurs in scars, the conditions consisting of the replacement of fibrous tissue by osseous tissue. This type of metaplasia is also evident in bone spavin, ringbone, sidebone, as well as in scars resulting from fistulous withers, poll evil, etc. Metaplastic osseous formation was recently noted in the omentum of a sheep. The conversion of lymphoid tissue into adipose tissue is metaplasia. The replacement or substitution of squamous epithelium for cubic or columnar epithelium represents a type of metaplasia.

Metaplasia is of little significance except as a pathologic condition.

CHAPTER VIII.

RETROGRESSIVE TISSUE CHANGES.

DEFINITION.

ETIOLOGY.

Variations in nutrition.
Chemic poisons.
Chemic reaction of tissue.
Variations of temperature.
Variations of function.

VARIETIES.

Atrophy.
Degeneration.
Infiltration.
Pigmentation.

Physiologic cell growth and function are dependent upon normal metabolism. Retrogressive processes are those conditions in which normal cell growth and function are diminished or suspended. Retrogressive tissue changes are caused primarily by abnormal cell metabolism or abnormal functioning, and are accompanied by structural or chemic alteration of the cell protoplasm or diminution in the size of the cells.

Metabolic disturbances may be caused by the following:

Diminished nutritive supply caused by (a) occlusion or diminution of the calibre of nutrient vessels; (b) insufficient supply of food to the animal; (c) incomplete or lack of digestion of the ingested food; (d) failure of absorption of digested food; (e) inability of the cells to utilize digested food that has been carried to them. Nutrition may be supplied in excess of the normal requirements, thus disturbing the metabolic equilibrium. Excess nutrients may be stored within the cells or they may be converted into energy by oxidation. In the former the stored food is a mechanical hindrance to cell action and in the latter the cell is overworked in converting the food into energy. Withholding of nutrient substances from cells produces destructive metabolism and ultimately cell death.

Chemical substances, i. e., poisons exert their action on cells by combining with some of the protoplasmic constituents or by accelerating, inhibiting or suspending the action of the cell enzymes, thus interfering with metabolism.

Chemic reaction of a tissue influences the action of cell

enzymes, and hence is a factor in metabolism and in bringing about retrogressive tissue changes.

Variations in temperatures.—The various albumens of protoplasm are coagulated at different temperatures. An increase of 3.6° F. is sufficient to coagulate one group of albumins and an increase of 9° F. is usually fatal because of the coagulation of other important albumin constituents of the cell protoplasm. Fever is invariably accompanied by coagulation of some albuminous constituents of protoplasm although it is possible that chemic substances as well as the high temperature may have some influence in this coagulation. Diminished temperature retards metabolic processes and if tissues are exposed for a sufficient time to a low temperature the protoplasm dies and metabolism ceases.

Diminished or increased cell functioning are factors in the causation of retrogressive changes. Diminished functioning for a considerable length of time results in atrophy and if functioning of a specific part is decreased progressively through several generations there will be failure of development of that part (aplasia). Excessive functioning, to a limited extent, in a part supplied with an excess of food, produces hypertrophy. Functioning beyond the nutritive supply produces degeneration and finally destruction of the cells.

Retrogressive tissue changes include atrophy, degeneration, infiltration and pigmentation.

ATROPHY.

DEFINITION.

DIFFERENTIATION.

KINDS.

Physiologic.

Pathologic.

ETIOLOGY.

Physiologic.

Senility.

Pathologic.

Disturbed nutrition.

Disturbed function.

Undue pressure.

APPEARANCE.

Macroscopic.

Microscopic.

TISSUE AFFECTED.

EFFECTS.

Atrophy is that condition in which there is a decrease in the size of an organ or tissue caused by a decreased size or a diminished number of the composing cells. In some instance the interstitial tissue increases and replaces the atrophied cells and the affected organ does not diminish in size. The term atrophy

is usually restricted to a local diminution in size, as, of an organ or part, although it has been applied to the condition resulting from a general wasting away of all the tissues of the body, i. e., emaciation.

Atrophy is differentiated from degeneration by the fact that the former is purely a diminution in the size of the part, (a result of decreased size or diminished number of the cells and without any alterations in the cell protoplasm) while the latter consists of chemical changes of the cell protoplasm and may result in increased or diminished size of the cells. Atrophy and degeneration may occur simultaneously in the same structure, the resulting condition being known as atrophic-degeneration or degenerative-atrophy. Hypoplasia is an underdevelopment in contradistinction to atrophy, which is diminution in the size after the part has been developed.

Atrophy may be physiologic or pathologic.

PHYSIOLOGIC ATROPHY is a term used to designate the normal diminution in the size of an organ or part. This occurs in the thymus gland which is well developed at the time of birth. Soon after this it begins to diminish in size and is practically extinct by the time the animal matures. The mammary gland atrophies after lactation ceases. Testicles and ovaries atrophy after the period of reproduction or sexual activity. Senile atrophy is a term employed to designate all atrophic conditions occurring in the tissues of old or aged animals. Senile atrophy is a physiologic process.

PATHOLOGIC ATROPHY is a term used to designate abnormal diminution in the size of an organ or part. Pathologic atrophic disturbances involve muscular, glandular and nervous tissue although no tissue is exempt. This type of atrophy is of frequent occurrence, viz., diminution of muscle cells in lameness, sweeney, etc., diminution in the size of the liver in hepatic atrophy, renal, cardiac, splenic and gastric atrophy.

Etiology.—Pathologic atrophy may be the result of either disturbed nutrition or disturbed function.

Disturbed Nutrition.—Atrophic disturbances resulting from mal-nutrition are most frequently the result of insufficient food. Cells receiving insufficient food gradually shrink in size, possibly because of auto-digestion. Insufficient nutritive supply may be due to a diminished quantity of blood or an impoverished blood. Diminished quantity of blood, i. e., a local anemia, is a result of diminishing the calibre or obstructing the supplying vessels.

Thrombic formation, aneurisms, etc., may cause partial or even

complete obstruction of nutritive vessels and thus be a causative factor in atrophy. Starvation, or failure, of assimilation of food is a cause of atrophy (general). However, in such cases atrophic degeneration of the cells is usually evident by the time the body weight has diminished $\frac{1}{10}$ of the total weight. Certain chemic substances may indirectly be of significance in the production of atrophy, but they influence either the cell nutrition or function.

Excess nutrition may induce metabolic disturbances of sufficient gravity to cause the cells to become sluggish and more or less inactive to such an extent that they will become atrophied. However, excess food is a much less frequent cause of atrophy than insufficient food.

Disturbed function.—Diminished or excessive functioning are causative factors in producing atrophy, the former being the most frequent cause. Tissues deprived of function usually become more or less atrophied. When an afferent nerve fibre is disconnected from its end organ, (the mechanism by which it picks up impressions), it begins to atrophy at once, probably because of its failure to function. Muscles not functioning atrophy. Thus there is muscular atrophy during most cases of lameness. Diminished cardiac function resulting from diminished blood pressure, is succeeded by atrophy of the heart muscle. Glandular structures become atrophied because of disuse.

Excessive functioning. long continued, causes fatigue and in some instances paralysis, the latter usually being succeeded by atrophy. Atrophy from excess function is sometimes observed in race horses, show animals and is not uncommon in musicians, acrobats, trapeze operators, etc.

Pressure.—Aside from the influence of the vaso-motor mechanism there may be sufficient pressure from tumors, hyperplastic formations, mechanical contrivances, as harness, etc., to diminish or obstruct vessels and cause atrophy. Pressure may also exert influence other than diminishing the blood supply, for constant pressure alone causes atrophy, e. g. pressure atrophy of osseous tissue. Pressure atrophy, accompanying cirrhosis of glandular structures as the liver or kidney, is usually caused by pressure of the newly formed fibrous tissue which partially obstructs the nutrient vessels. However, the compression of the parenchymatous cells disturbs their metabolic equilibrium and is also a factor of some importance.

Appearance. *Macroscopic.* Atrophied organs are usually diminished in size, are irregular or regular in shape, have a dry shrunken anemic appearance and are usually pigmented. The

parenchymatous tissue is most frequently involved, interstitial tissue rarely becoming atrophied. The diminution in size may be uniform throughout, the atrophied part thus retaining its normal shape, or the diminution may be unequal in different parts, thus producing a lobulation of the affected portion. Atrophied bone usually maintains its normal external shape, as the process is essentially a rarefaction in which the Haversian and medullary canals are increased in size. Pulmonary atrophy may consist of diminution of the alveolar membranes to such an extent that they rupture, thus producing large cavities. Atrophic muscular tissue is usually more intensely pigmented than normal muscle. The source of the excess pigment in atrophic muscles may be from the atrophied muscle cells or it may have its origin from the blood.

Microscopic.—The cell body and nucleus shrink in size in simple atrophy without previous alteration in the cell structure. In numerical atrophy the cells first diminish in size and then disintegrate and die. Thus atrophy, disintegration and necrosis are evident in numerical atrophy. The appearance of atrophic tissues vary according to the structures involved. Atrophic kidney tissue is characterized by the diminution in the size or in the number of the glomerular and tubular cells. The tubules and glomeruli may collapse the supplying capillaries becoming obliterated by pressure of the hyperplastic fibrous tissue. In muscular atrophy, the muscle cells diminish in size probably because some of the fibrillae disappear.

Effects.—The effect of atrophy depends upon the structure involved the extent of the condition and the age of the animal. If the involved structure is not vital and the atrophy is of only slight extent and in a young animal, in which the regenerative power is good, the part will recover if the cause is removed. Extensive atrophy of vital structures in old animals is usually fatal or at least predisposes to other conditions that are fatal. Again, a part may partially recover after atrophic disturbances.

CLOUDY SWELLING.

*DEFINITION.**OCCURRENCE.**ETIOLOGY.**Chemic.**Bacterial products.**Phosphorous, Arsenic, etc.**Thermic.**APPEARANCE.**Macroscopic.**Microscopic.**TISSUE AFFECTED.**Epithelium.**Muscle.**Nerve.**EFFECTS.*

Cloudy swelling, albuminous, granular or parenchymatous degeneration is a retrograde metamorphosis in which the protoplasm of the cell becomes granular. The granules in cells affected with cloudy swelling are albuminous, at any rate they are soluble in an excess of a 2% solution of acetic acid or a 1% solution of potassium hydroxide, and give the typical albumin reaction to the xanthoprotein test. Active glandular cells, especially those that produce ferments, are normally granular; but the granules in these cells do not respond to the foregoing tests and hence are not albuminous. Cells in the earlier stage of fatty degeneration are granular but the granules are not dissolved by solution of acetic acid or potassium hydroxide, and they are dissolved by ether or chloroform and are stained red with Sudan III. Therefore they are fat granules.

Cloudy swelling probably occurs more frequently than any other retrogressive change. It invariably affects parenchymatous cells in areas afflicted with acute inflammation and is usually associated with infective diseases.

Etiology.—The causes of cloudy swelling may be divided into two groups, Chemic and Thermic.

Chemic substances produce cloudy swelling either by influencing the action of cell enzymes, thus causing the separation (coagulation) of the cell albumins, or by combination with the albumins of the cell protoplasm thus forming new compounds (albuminate of mercury, etc.) that are of no value to the cell. Excessive quantities of albuminous substances may be assimilated by the cells, the unused portion becoming coagulated or rendered insoluble as it accumulates, thus producing cloudy swelling. The chemic substances that produce cloudy swelling are usually soluble and are in solution in the blood or lymph from which they readily diffuse into the cell body where they exert their action.

Of the chemic substances capable of producing cloudy swelling bacterial products are the most important. The diphtheria toxin is probably the most active of all bacterial products in the production of cloudy swelling. Other organic substances as leucamins and phenol are capable of producing this degeneration as well as many inorganic substances as arsenic, mercury, phosphorous and the mineral acids.

Thermic disturbances, especially high temperature, is probably a cause of cloudy swelling. Halliburton has demonstrated that certain high temperatures produce turbidity or granular degeneration of cells. From experimental evidence it is apparent that different groups of the albumins of the cell protoplasm are separated (coagulated) at different temperatures. The higher the temperature the more fixed the coagula and the more difficult they are of solution. From the present known facts, although the chemistry is not determined, it is evident that high

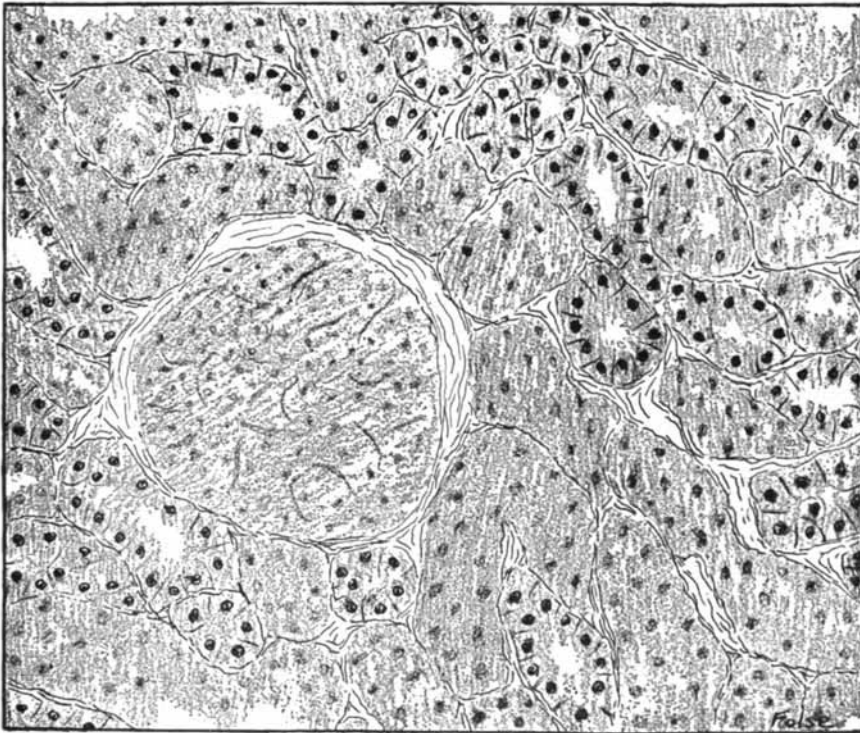


Fig. 111.—Cloudy Swelling, showing granular degeneration of kidney cells.

temperature is at least a predisposing if not an exciting cause of cloudy swelling.

Appearance.—*Macroscopic.*—An organ or part affected with cloudy swelling, has a parboiled appearance, it is lusterless and lighter in color, softer in consistency, and is slightly enlarged.

Microscopic.—An organ or part affected with cloudy swelling appear cloudy, because of the presence of many small albuminous granules, and the cells are slightly enlarged, hence the name cloudy swelling. The increased size of the cell results from coagulation, the coagula occupying more space than the non-coagulated protoplasm. If the tissues of an organ are examined with the high power microscope the cell may appear slightly swollen and its limiting membrane quite distinct; it may be considerably swollen and have an indistinct membrane; or, finally, it may have ruptured and the space it previously occupied may contain a mass of granular debris. The protoplasm of the cell body may contain small, irregular granules, the nucleus may be almost normal, slightly degenerated, or it may even be entirely disintegrated.

Tissues Affected.—Epithelium, muscular, nervous, and connective tissue are affected with cloudy swelling, the frequency being in the order mentioned. Cells of excretory organs are especially affected because of their eliminative function.

Effects.—The effects of cloudy swelling depend upon the structure involved, the extent of the involvement, and the age of the affected animal. Affected muscular tissue has a diminished contractile power. Renal tubules may be occluded because of the swollen tubular cells and the affected cells may also have a diminished functional capacity. The function of any structure is decreased and in extreme cases inhibited by cloudy swelling of its component cells.

Cloudy swelling is usually a repairable process, providing the cause is removed before the cells are destroyed.

FATTY CHANGES.

*PHYSIOLOGIC (Fatty Infiltration).**DEFINITION.**ETIOLOGY.*

Excess food.
Insufficient exercise.
Heredity.
Influence of disease.
Unsexing.
Lactation.
Venesection.

APPEARANCE.

Macroscopic—Greasy, pale color.
Microscopic—Droplets of fat between cells.

TISSUE AFFECTED.

Normal depositions.
Epithelium, muscle.

*EFFECTS.**PATHOLOGIC (Fatty Degeneration).**DEFINITION.**ETIOLOGY.*

Insufficient food.
Inability of cells to utilize food.
Excessive activity.

APPEARANCE.

Macroscopic—Greasy, pale, light.
Microscopic—Droplets of fat in cells.

TISSUE AFFECTED.

Epithelium.
Muscle.
Nerve.

EFFECTS.

Adipose tissue is not a specific tissue, but represents a modified connective tissue. The cells that later become fat cells, are originally flat or spindle shaped and usually occur in clusters or groups. There are certain locations, called fat depositories, where fat usually occurs. Normally the principal fat depositories are located in relation to the kidney capsule, subserosa (parietal, visceral and omental peritoneum), subcutem, intermuscular areolar tissue, and in the orbital fossa. A well fattened animal has accumulations of fat in all the fat depositories. In an emaciated animal limited quantities of fat occur only around the kidney in the omentum, and orbital fossa.

Normal adipose tissue varies in color and consistency in the different animals. In general it is white or yellow and appears lobulated when cut across. The consistency depends upon the melting point of the fat.

Olein is the principal kind of fat in the hog, stearin and palmitin in the ox, and stearin in the sheep. It has been demon-

strated, however, by Prof. Hopkins, of the University of Illinois, that the body fat is the same as the ingested fat. (Hogs were fed on cotton seed oil and the presence of the same kind of fat was demonstrated in the hog tissue.) It has also been found that butter fat in cow's milk is the same as ingested fat. Opinions are at variance in reference to the digestion and assimilation of fat. The fat splitting enzymes convert the fats into fatty acids and glycerine. The alkali present in the intestines unites with a part of the fatty acid, forming soap, the latter and the glycerine pass by osmosis into the intestinal epithelium or through the mucous membrane where the glycerine is substituted for the alkali, the alkali passing back into the intestinal lumen to form more soap (Hammersten). Some of the fat may be so finely emulsified that it passes directly into and through the intestinal epithelium, and some of it may be incorporated by leucocytes, and thus carried from the lumen of the intestine to the lacteals (Howell). Fat droplets are present in the circulating blood. The exact manner of the production of fat cells in normal adipose tissue has not been determined.

All normal animal tissues contain varying quantities of neutral fat. As much as 23 per cent of fat has been extracted from kidney tissue (Adami). The proportion of neutral fat in the same kind of tissue varies in the same animal under different conditions and in animals of different species under the same conditions. Thus the quantity of fat in the muscular tissue of an emaciated animal is less than in an animal in good flesh. The muscular tissue of the hog contains more fat than the muscular tissue of the ox, sheep, horse or dog. In fact the presence of fat droplets between the muscle cells is a distinguishing characteristic of porcine muscular tissue. There is no definite limit to the quantity of fat normally contained in the tissues of any animal.

Certain abnormal fatty changes occurring in the various tissues have been described as fatty infiltration and fatty degeneration. These changes, although originally thought to be entirely distinct, are closely related and may represent different stages of the same process. These fatty changes may be discussed as physiologic fatty changes (fatty infiltration), and pathologic fatty changes (fatty degeneration), although there is no good reason for the division of the subject other than to recognize the previous classification and prevent undue confusion.

Physiologic Fatty Changes.

(Fatty Infiltration.)

Physiologic fatty changes is a condition in which there is an excessive accumulation of fat, but the function of the affected part is not materially changed.

Etiology. *Excess Food.*—House dogs and cats and many family horses are usually fed to excess, resulting in the deposition of excessive quantities of fat in practically all tissues, thus producing general obesity. The "Strassburg goose" is force-fed with dough balls in excessive quantities until excessive obesity is produced, the liver especially becoming the seat of marked fatty accumulations. In fact all prime "butcher stuff" is affected with physiologic fatty changes or dietary obesity.

Insufficient Exercise.—Animals kept in tie stalls or in close quarters have a tendency to become excessively fat, especially if they are fed a full ration, because there is diminished oxidation on account of lack of exercise and the bulk of the consumed food is stored as fat.

Venesection.—Frequent bleeding diminishes the percentage of red blood corpuscles and thus indirectly diminished oxidation and favors fat accumulation.

Disease.—Some diseases appear to influence the physiologic deposition of fat. The early stages of tuberculosis in cattle and hogs and distomatosis in sheep is accompanied by physiologic fatty deposition. During convalescence from some diseases there is an increased deposition of fat.

Lactation.—The early period of lactation is accompanied by fatty accumulation especially in the liver. (Possibly the liver may act as a distributing center of fat.) The fatty accumulation in the liver is evident regardless of any variations in the composition of food stuff.

Heredity.—Some animals, especially hogs, except the Tamworths and Yorkshires, appear to have an inherent tendency to become excessively fat.

Castration.—Removal of the genital glands favors fat accumulation in the tissues. Castrated dogs and cats, especially if castrated when mature, become obese.

In general the exciting causes of physiologic fatty changes are excess of food or diminished oxidation, heredity being a predisposing factor.

Appearance.—*Macroscopic.*—Tissues affected with fatty infiltration are greasy or oily, more friable than normal, and paler in color, the color being uniform throughout or mottled. The quantity of blood in the fat varies, there being more, in general, in the fat of young animals. Muscular tissue in which there is a fatty accumulation contains areas or strata of fat and strata of muscular tissue. The deposition of fat may be so extensive in muscular tissue of hogs that there is little evidence of muscle. Subserous accumulations of fat may be localized, giving the appearance of masses of fat, or it may be accumulated diffusely as thick layers of fat. In dogs and cats the excess fat is usually deposited around the kidneys.

Microscopic.—In the early stages of physiologic fatty changes, small droplets of fat are observed between and within the cells. The intracellular fat gradually increases and assumes the space within the cell, the nucleus being crowded to the margin of the cell and may ultimately disappear.




Fig. 112.—**Fatty Infiltration, liver, hog, showing infiltration of globules from periphery of lobule toward its center.**

Tissue Affected.—All tissues are subject to fatty accumulations, excepting the normal depositories, the liver being most prone to the affection.

Effects.—The influence of physiologic fatty changes is dependent upon the extent of the condition and the duration of

the process. If the nuclei of the cells are not injured and the process is discontinued the infiltrated fat is disposed of and the part recovers. If non-regenerative cells, such as heart muscle, are destroyed, they will not be regenerated, even though the fat is reabsorbed. The destroyed heart muscle cells may be replaced with fibrous tissue.

Pathologic Fatty Changes.

(Fatty Degeneration.)

Pathologic fatty change, or fatty degeneration, is a condition in which the protoplasm of the affected cells diminishes because of an increase of the intracellular fat. Fat or some of its cleavage constituents is probably constantly present in varying quantities in all active cells.

Pathologic fatty changes are of frequent occurrence, being associated with diseases of malnutrition, and occurring in acute febrile diseases and many of the infective diseases. It is especially evident in chronic phosphorous poisoning and some other chemically induced diseases.

Pathologic fatty change is differentiated from cloudy swelling as follows: The droplets of fat are soluble in ether and chloroform and are not dissolved with dilute acetic acid or potassium hydroxide; while the granules in cloudy swelling are insoluble in ether and chloroform, but are soluble in dilute acetic acid or potassium hydroxide. Again the fat droplets are stained red by Sudan III, while the granules of cloudy swelling are not. Fatty degeneration is difficult to differentiate from fatty infiltration, and in some instances it is impossible to differentiate them; in fact, future investigation may confirm the identity of the two processes. In the early stages the fat droplets are usually intracellular in fatty degeneration, and intercellular in fatty infiltration.

Etiology.—In general, fatty degeneration is the result of the disturbance of cell metabolism. The production of energy, being intimately associated with the metabolism of fat, becomes a factor in the causation of fatty degeneration. Specifically, disturbed nutrition is the principal cause of fatty degeneration. Disturbed nutrition may be the result of, 1st, variation in the composition of the blood, 2nd, diminished quantity of blood, 3rd, diminished oxygen supply, and 4th, changed environments of the cells. Insufficient supply of cell nutriment is the principal in-

fluence resulting from circulatory disturbances or altered composition of blood. Diminished oxygen supply results in incomplete oxidation of the available intracellular fat which is then accumulated within the cell. Changed environments include the variation of the chemic reaction of a tissue, the tissue temperature, amount of fluid, etc. Disturbance of the environments influences the cell metabolism and may cause the union of cleavage products of fat that exist within the cell, or the infiltration and intracellular accumulation of fat may be favored. Changed environments may also render the cells unable to utilize the food brought to them.

The causes of cloudy swelling are also etiological factors in the production of fatty degeneration, in fact, fatty degeneration is frequently associated with cloudy swelling and the fatty degeneration is the result of disturbed metabolism. Disturbed metabolism is produced by insufficient or improper food, diminished supply of oxygen, or inability of the cells to utilize the food or oxygen supplied, the inability of utilization being a result of the damaging influence of chemic or thermic variation of the environments of the cells.

Appearance.—Macroscopic.—A tissue affected with fatty degeneration varies in appearance according to the extent of the process. In general, affected tissues are paler in color (change in color is frequently in patches which appear yellowish), lighter in weight (in extreme case, liver tissue affected with fatty degeneration, floats in water), greasy or oily in appearance, (a knife blade that had been used in sectioning a fatty tissue is usually smeared with drops of oil or fat), and usually swollen or enlarged in the early stages, succeeded by diminution in size as the fat is resorbed. Tissues affected with fatty degeneration are less elastic, and more friable.

Microscopic.—In the very early stages the cells contain small granules that are differentiated from the granules of cloudy swelling only by the chemic test referred to above or by special stains, as Sudan III. As the degeneration progresses, the minute fat droplets coalesce, forming drops sufficiently large to be recognized microscopically, as small, clear spots or holes in the cell protoplasm in sections of tissue fixed in fluids that are solvents for fats and as fat drops in fresh tissues. The affected cells are swollen to an extent which is proportional to the degree of the degeneration. Ultimately the cell membrane ruptures and the enclosed fat is liberated, thus producing a condition not

differentiable from fatty infiltration. The nucleus is usually not involved in the beginning, but as the degeneration progresses in the cytoplasm, the chromatin network disappears and the entire nuclear structure finally becomes disintegrated, producing the so-called granule cell. The degeneration may be continuous throughout a tissue or it may be more or less patchy. The extent of involvement of the cells in an affected area is usually unequal, some cells being only slightly affected, others containing considerable fat, and still others being entirely converted into fat.




Fig. 113.—Fatty Degeneration of the Liver, showing the early stage of the process around the central vein.

Tissue Affected—Glandular tissue, particularly the liver, is probably most prone to become affected with pathologic fatty changes, or fatty degeneration. Muscular tissue is quite subject to fatty degeneration, especially heart muscle. Epithelium other than glandular, nervous and connective tissues, are not exempt from this process. Tumors are occasionally observed to be affected with pathologic fatty changes. Necrotic tissue frequently becomes a fatty mass or an entire cadaver may be con-

verted into a fatty mass termed adipocere, which is no doubt the result of ferments liberated from the dead tissue.

Effects.—The conversion of the cell protoplasm into fat impairs the cell function. At least diminished cell action, as well as disturbed cell metabolism is evident in cells affected with pathologic fatty change. In cells slightly affected, the droplets are either oxidized or are extruded from the cell (absorbed when the cause is removed). Cells more extensively affected may be destroyed, leaving a meshwork of vessels and fibrous tissue. The area may later be filled with the new parenchymatous cells arising from the surrounding less affected zones, and, like those destroyed, it may persist as a mass of fibrous tissue, i. e., a scar. If regeneration occurs there must be an adequate blood supply.

The degenerated cells may become caseated as a result of the conversion of the fatty material into a cheese like mass. The usual cause of caseation of fatty debris is diminished or obstructed blood supply resulting in gradual absorption of the fluids, saponification of the fats and in some instances the formation of cholesterin. Caseated material derived from the fatty debris may later be liquified or calcified.

AMYLOID CHANGES.

DEFINITION.

ETIOLOGY.

APPEARANCE.

Macroscopic.

Microscopic.

TISSUE AFFECTED—*Subendothelium.*

EFFECTS.

Some masses may be found in the acini of the prostate gland, especially in old dogs and aged humans, that respond to the iodine test and are considered by some authorities as amyloid bodies. Physiologic amyloid formations have not been observed other than in the prostate gland and they probably have a pathologic origin. Thus a physiologic prototype of amyloid formation is unknown.

Amyloid substance (amylin) is an albuminoid, insoluble in water, alcohol, ether, chloroform, xylol, dilute acids or alkalies and is not acted upon by pepsin. When tissue containing amyloid substances is immersed in Lugol's solution the amyloid areas assume a mahogany brown color and the normal tissue is stained a yellowish brown. (To make this test wash the affected tissue thoroughly until all blood has been removed, apply a lib-

eral quantity of Lugol's solution for one or two minutes, wash the excess of the reagent off and the above color reaction will be observed). The test is equally applicable to macroscopic and microscopic sections. If the sections, macroscopic or microscopic, are immersed in dilute sulphuric acid, after the application of Lugol's solution, the amyloid area will assume a blue color, the normal tissue a brown color. The analine dyes usually stain amyloid substances some shade of red.

The source of amylin is not definitely known. It may be derived from the blood or from tissue cells. The formation of amylin may depend upon variations in the percentage of some chemic substance in the blood or tissue juices.

Amyloid formation is not common in the domestic animals. Occasionally a dog is observed that is affected with amyloid accumulations in the prostate gland. One case has been observed in a hog in which the liver was affected, and, excepting this, the carcass showed evidence of no other lesions.

Etiology.—The cause of amyloid change is not known, although it has been assumed by some pathologists to be associated with chronic suppurative conditions, as, tuberculosis, and other chronic debilitating diseases, as carcinomatosis. The tissues from several animals affected with chronic suppurative processes, as fistulous withers, poll evil, quittor, tuberculosis, glanders, caseous-lymphadenitis, as well as tissue from animals affected with tumors have been examined, but amyloid changes have not been found. Increased or diminished quantity of some of the salts of the blood may be found to be an etiologic factor in amyloid changes.

Appearance.—*Macroscopic.*—Affected tissues or organs are larger, paler, and firmer than normal. The amyloid areas are homogeneous and translucent in appearance. The entire organ or tissue appears homogeneous when the amyloeous material is diffuse.

Microscopic.—Amyloid substance is deposited in the framework beneath the endothelial cells lining the blood vessels. It appears as an annular homogeneous mass encircling the vessel. The amyloid substance may accumulate to such an extent that the vessel is obstructed. After the capillaries have been gorged beyond their resistance they rupture, thus allowing the amyloid substance to permeate the interstitial spaces where it appears microscopically as irregular homogeneous masses.

Tissue Affected.—The blood-vascular subendothelial connective tissue is the principal location of amyloid formation, although it may occur in lymph vessels and even the perimysium

and endomysium may be affected as well as the stroma of the mucous membranes. The liver, spleen, and kidney are the most frequent locations of the process, probably because of the large number of capillaries in those organs.

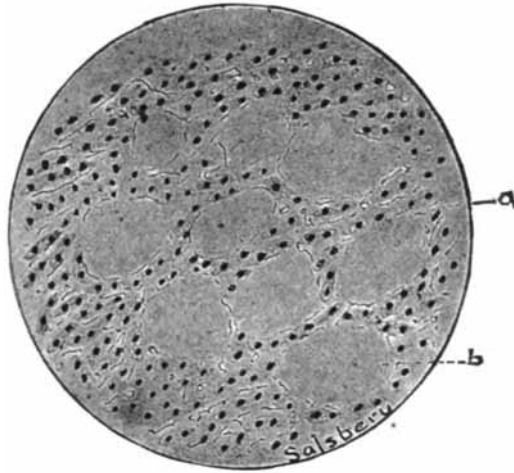


Fig. 114.—Amyloid Degeneration, Liver.
a. Liver cells. b. Amyloid material.

Effects.—The condition is so rare that it is not possible to generalize upon the effects of the process. The amylaceous material is insoluble in the body fluids and it is quite probable that if a part becomes affected, it remains so permanently.

HYALINE CHANGES.

DEFINITION.

ETIOLOGY.

APPEARANCE.

Macroscopic.

Microscopic.

TISSUE AFFECTED.

Vessels, Muscles.

EFFECTS.

This is a pathologic condition characterized by the conversion of the cell substance into a homogeneous material called hyaline. In the phenomena accompanying the physiologic changes of the corpus luteum of pregnancy, a hyaline substance is produced. The physiologic formation of hyalin, aside from that produced in the corpus luteum of pregnancy, has not been recorded.

The formation of hyalin is quite common in the muscular

portion of the blood vessels of tissues affected with chronic inflammation and in the blood vessels of sarcomata. It has also been observed in voluntary and heart muscle in certain diseased processes.

Hyalin, an albuminous substance very similar to amylin, does not respond to the iodine test, and is not acted upon by alcohol, ether, chloroform, acids, ammonia, or water. Acid stains, as eosin and acid fuchsin, have an affinity for hyalin and stain it quite intensely.

Etiology.—The specific cause of hyaline formation is not definitely known. Certain predisposing factors, however, are of interest. Wells found that lactic acid injected into voluntary muscle was succeeded by hyaline formation, and it may be assumed that the cause of hyaline changes in voluntary muscle is excess of sarcolactic acid. Some diseased processes, as chronic inflammation, tuberculosis, and sarcomatosis are accompanied by conditions that favor hyaline formation.

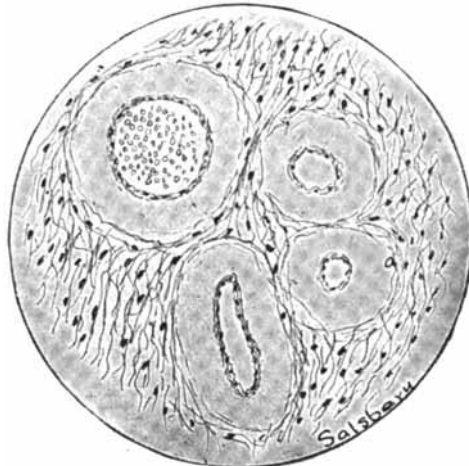

Fig. 115.—Hyaline Degeneration, Vessels.
a. Hyaline around arteries in maxilla of colt.

Appearance.—*Macroscopic.*—Rarely does this condition become sufficiently marked to be recognized with the unaided eye. The hyaline substance appears as a translucent, homogeneous, firm mass, intermingled with the normal tissue.

Microscopic.—The hyaline substance appears as glassy areas, and the adjacent tissue frequently becomes less distinct. Except for the affinity of hyaline substances for acid stains and its fail-

ure to react to iodine it is difficult to differentiate from amyloid change.

Tissues Affected.—Muscular tissue, involuntary muscle, especially of the blood vessels, voluntary muscle and heart muscle are subject to hyaline changes. Connective tissue is less frequently involved and epithelium rarely, if ever.

Effects.—When hyaline has been formed in small quantities and the cause is removed the hyaline substance is resorbed and the affected cells repaired. If the production of hyalin has replaced the protoplasm of large cell masses, especially of muscular cells, the area will probably not be repaired with muscular tissue, though it may be with fibrous tissue, provided the cause is removed.

MUCOID CHANGES.

Physiologic.

DEFINITION.

ETIOLOGY—*Physiologic, pathologic.*

APPEARANCE.

Macroscopic.

Microscopic.

TISSUE AFFECTED—*Connective, epithelium.*

EFFECTS.

The transformation of cell protoplasm into mucus is evident in the physiologic production of mucus in the surface epithelium of mucous membranes as well as in mucous glands. The physiologic conversion of protoplasm into mucus is the result of intracellular enzymes, or at least depends upon protoplasmic activity. As the mucus is produced the cell becomes enlarged and ultimately ruptures, discharging the mucus. The mucus may be formed only in the distal end of the cell or it may entirely replace the protoplasm of the cell. In the former the remaining protoplasm of the cell regenerates the portion destroyed. In the latter the adjacent cell multiplies, thus filling the gap.

Mucus is a viscid, glairy stringy nitrogenous fluid. The principal ingredient of mucus is mucin, a glucoproteid, although there may also be present pseudomucins. Mucin imbibes water, thus becoming swollen, and from this swollen mass there is precipitated a stringy material by addition of alcohol or dilute acetic acid. Pseudomucin forms a gelatinous mass when dissolved in water, but by the addition of alcohol to this gelatinous mass a stringy precipitate is formed which is redissolved in excess of water, differing in this respect from mucin.

Pathologic.

Pathologic mucoid formation affects cells and intercellular substance. Cellular pathologic mucoid change is identical to normal mucus formation except that it is in abnormal locations or is in excess in those locations in which mucus is normally produced. Intercellular mucoid formation is a condition resulting from the conversion of intercellular substances—fibres, matrix of cartilage and bone—into mucus. Pathologic mucoid changes occur rather frequently. It is evident in catarrhal inflammation, in cyst formations and as a retrogressive process in many tumors.

Etiology.—The cause of pathologic mucoid changes is not known. Excessive cellular mucoid formation accompanies mild inflammatory disturbances of mucous membranes—so called catarrh. The increased production of mucus in catarrhal inflammation may be the expression resulting from the exaggerated function of the mucous membrane induced by the excessive quantity of blood supplied.

Intercellular mucus formation may result from improper nutrition or injurious influences induced by chemic substances. It has long been thought, although it has never been proven, that some product is evolved when the thyroid gland is diseased that causes a mucus degeneration of all fibrous tissue in the body (myxoedema). Some sarcomata and carcinomata are affected with mucoid changes, probably the result of chemic substances elaborated by the tumor cells.

Appearance.—*Macroscopic.*—Mucus of pathologic origin is not differentiable from physiologic mucus. In pathologic conditions accompanied by mucus formation the mucus is frequently mixed with other substances, as blood, pus and food stuff. Thus the mixture assumes various appearances. A discharge composed of mucus and pus (muco-purulent) is common in practically all catarrhal inflammation, being the characteristic discharge of catarrhal pneumonia and is the usual discharge from the respiratory tract and conjunctiva, in dogs affected with distemper, in horses afflicted with "stock yard fever," etc.

The appearance of a tissue affected with pathologic mucus changes, regardless of whether the cells or intercellular substance is involved, depends upon the quantity of mucus produced. If there is a limited quantity of mucus and it is equally distributed throughout, the affected tissue will appear swollen and soft. If more extensive and diffuse the affected tissue will be soft, spongy, and slimy. If the entire structure has practically been converted into a mass of mucus, it will appear as a slimy,

stringy, pulpy substance from which varying quantities of mucus may be expressed.

The muroid changes may affect circumscribed local areas that appear moist and soft, spongy, or even cystic in contradistinction to the surrounding normal tissue.

Microscopic.—Mucus appears as a stringy substance containing varying quantities of detritus. Fixing agents coagulate mucin in which case it appears as a more or less homogeneous mass containing many fibrillae or threads of coagulated material.

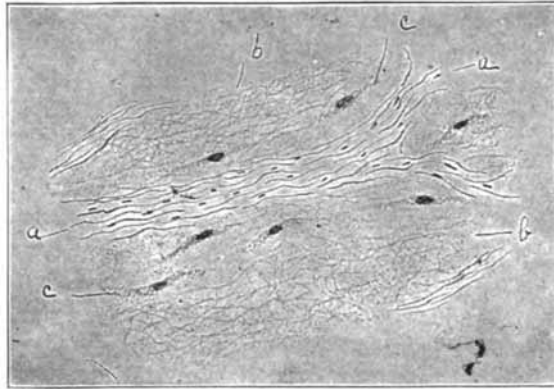


Fig. 116.—Mucoid Degeneration.

a. Fibrous tissue. c. Mucoid cells.
b. Mucous substance.

Microscopic appearance of a tissue affected with pathologic muroid changes is variable according to the extent of the process but in general the picture observed is the same as that of the normal tissue plus the mucus.

Tissue Affected.—Epithelium and the cells and intercellular substance of connective tissue as well as some tumors are subject to muroid changes.

Effects.—The effects depend upon the extent, duration, and regenerative ability of the affected tissue.

COLLOID CHANGES.

*DEFINITION.**ETIOLOGY—Unknown.**APPEARANCE.**Macroscopic.**Microscopic.**TISSUE AFFECTED.**Thyroid, prostate, tumors.**EFFECTS.*

The term "Colloid" has rather an indefinite meaning and by present day writers is used to indicate a variety of substances. "The word colloid is merely morphologically and macroscopically descriptive of certain products of cell activity or disintegration, which have nothing in common except the fact that they form a thick glue like or gelatinous, often brownish or yellowish substance" (Wells). One type of colloid substance is a physiologic product of the thyroid gland, it is in part a secretion of the thyroid cells and in part a conversion of those cells into colloid material. This product is normally absorbed as it is produced though it may accumulate in small quantities in the gland acini, especially in aged animals.

Chemically the physiologic thyroid colloid is composed of iodo-thyreoglobulin (a compound of globulin and thyroidin). Thyroid colloid is glue like in consistency and varies in color from brown to yellow. Colloid and mucous are closely related. Colloid does not increase in bulk when it is suspended in water, neither is it precipitated by alcohol or acetic acid—two tests that are usually sufficient for differentiation of mucus and colloid. Pseudo-mucin is more difficult to differentiate from colloid. The latter, however, contains iodine and the former does not.

Pathologic colloid changes are conditions resulting from the excessive production and retention of collagenous material. The disturbance induced by excessive colloid accumulation is usually not serious although it may cause fatal termination. This condition occurs more frequently in old dogs than in other animals. Sheep occasionally show lesions of this condition, in some instances the entire flock becoming affected. Pathologic colloid accumulation is a constant lesion in the thyroid gland of animals suffering from exophthalmic goitre. Colloid changes have been observed in cattle, sheep, horses, mules and one case has been recently noted in a calf.

Etiology.—The specific exciting cause of pathologic colloid changes is not known but undue exposure to inclement weather is a predisposing cause of considerable moment. Exposure, in some instances, appears to become an exciting cause of thyroid

colloid accumulation. A flock of 128 healthy, yearling sheep shipped from south central New Mexico to the Kansas City stock yards, were all found to have enlarged thyroid glands at the time of slaughter, which was about 24 hours after their arrival at the stock yards. The thyroid glands were found on microscopic examination to be affected with pathologic colloid accumulation. This occurred in April, the sheep, having been sheared just previous to shipment, and the weather having been very inclement during the entire time that they were in transit. Other entire flocks of sheep that have been unduly exposed have been affected in a like manner.

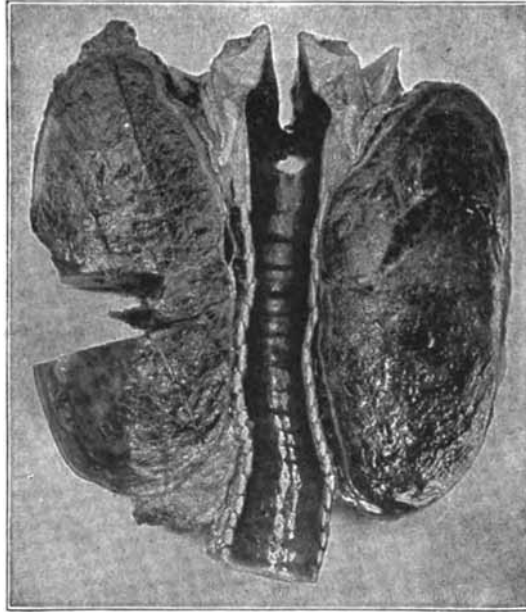


Fig. 117.—Photograph of a thyroid gland affected with Colloid Degeneration.

Endemic goitre in the human is indicative of an infectious cause though the individual cases in non-affected areas dispels the infection theory.

The absence or diminished quantity of iodine in the food, water or air, may be a causative factor in the production of goitre and other colloid accumulations in the thyroid glands.

Appearance.—*Macroscopic.*—Colloid most frequently occurs in masses, varying in size from mere microscopic points to bodies as large as a lead pencil rubber or even cyst like bod-

ies as large as a black walnut. More rarely the colloid material may have infiltrated the tissue spaces and become diffuse. Colloid varies in consistency from a watery to a jelly like mass, is usually of a clear amber color, although it may be translucent or of a deep mahogany tint.

An affected tissue contains variable sized areas of hyaline, rather firm, amber or mahogany colored masses deposited irregularly throughout the entire structure.

Microscopic.—The cells are noted to contain small droplets of colloid material which is constantly produced and passed out of the cells and accumulated in the acini, tubules, or intercellular spaces. Other entire cells are converted into a colloid

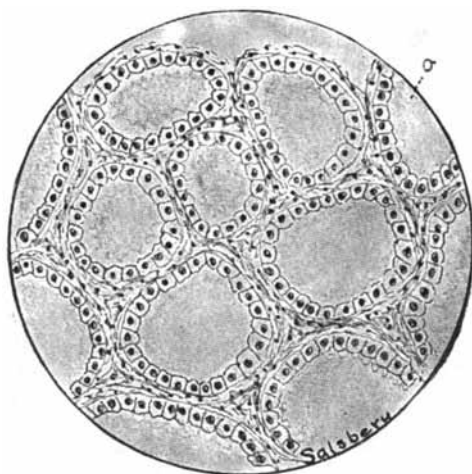


FIG. 118.—Colloid Degeneration, Thyroid Gland.
a. Colloid material completely filling the acini of gland.

mass. The conversion of a large number of cells into colloid material in one vicinity produces colloid masses or the so-called colloid cysts. Colloid substance is homogeneous or slightly granular and is stained, by acid stains. It assumes an orange color when stained according to Van Gieson's method.

Tissue Affected.—Epithelium is probably the only tissue in which colloid formation occurs. The thyroid gland is most commonly affected. There is a degenerative change occurring in carcinomata that is similar to the colloid formation although it may be pseudomucin formation. McFarland states that colloid casts occur in the uriniferous tubules, in kidneys affected with chronic inflammation. Ziegler regards the prostatic concretions, of the human, that do not react to iodine, as colloid.

Effects.—The effects of colloid accumulation depend upon the extent of it. The exact function of the thyroid gland has not been determined but it is quite certain that the iodine compound, iodothyrein or thyroiodin is the active principle of the thyroid secretion. It is not known whether the thyroid secretion has some action upon cell metabolism or neutralizes various poisonous substances that result from metabolism or poisons introduced into the body from without. The colloid accumulations in goitre contain less iodine per given volume than the normal secretion, but the total quantity of iodine is materially increased resulting in circulatory disturbances, as rapid weak pulse, increased metabolic activity especially of proteids, increased secretions, irritability, etc. Diminished iodine production, as observed in myxoedema, is not common in colloid accumulation.

SEROUS INFILTRATION.

DEFINITION.
ETIOLOGY—(Oedema).
APPEARANCE.
Macroscopic.
Microscopic.
TISSUE AFFECTED.
EFFECTS.

Serous infiltration is a condition in which excessive quantities of lymph or serous fluid infiltrates the cells.

In the anatomico-physiologic discussion of the cell, the nutrients were said to be obtained by specific selective action of the cells and by osmosis. Osmosis is probably the most important mode of passage of extracellular substances into the cell.

In hydremia or other conditions in which cells are bathed by excessive quantities of fluid, there is a tendency for them to become hydropic.

Serous fluid that enters the cells in serous infiltration is thin, watery and contains small quantities of proteids and salts.

Etiology.—The cause of serous infiltration is an excess of serous fluids in the tissues. Serous infiltration is, therefore, an accompanying condition of oedema and the causes of oedema would likewise be the primary cause of serous infiltration. A second cause may be the impairment of the cells in which they are stimulated to imbibe more fluid.

Appearance.—*Macroscopis.*—Because of the simultaneous occurrence of oedema and cellular serous infiltration and in view of the fact that oedema is so conspicuous, the serous infiltration is not recognizable in gross examination.

Microscopic.—When examined in the fresh state the cells are enlarged, the extent of which depends upon the quantity of fluid imbibed. The infiltrated fluid accumulated in the cells appears as clear spaces or vacuoles. The vacuoles occur either in the cyto-plasm or the nucleus and in extreme cases, they occupy the entire cell and may even cause its rupture.

Tissues Affected.—Practically all tissues are subject to serous infiltration. Those tissues in which oedema occurs are most frequently affected. Epithelium is quite frequently involved in serous infiltration because this tissue forms the surface of those structures affected with oedema.

Effects.—The effects depend upon the extent and duration of the condition. Some vegetable cells are capable of imbibing fluid to a sufficient extent that they increase their size one hundred times.

Animal cells cannot imbibe fluids to such an extent as vegetable cells without being rent asunder. After the cells have been subjected to serous infiltration for sometime, the nuclear chromatin appears to dissolve and diffuse through the cell body. This necessitates an impairment of the cell activities.

GLYCOGENIC INFILTRATION.

DEFINITION.

ETIOLOGY—(*Disturbed carbohydrate metabolism*).

APPEARANCE.

Macroscopic.

Microscopic.

TISSUE AFFECTED.

EFFECTS.

This is a condition characterized by the infiltration of excessive quantities of glycogen into cells that normally contain a limited amount of it or the infiltration of glycogen into cells normally glycogen free.

The source of glycogen is not definitely known. According to some physiologists, glycogen may be formed from either carbohydrates or proteids. The digested carbohydrates are probably stored up in the form of glycogen, at least glycogen is readily converted into dextrose whenever carbohydrates are needed. Glycogen can be demonstrated in the normal liver cells, kidney cells, and in muscle cells, although it occurs in limited quantities.

Glycogen is soluble in water and insoluble in alcohol, chloroform and ether. Its presence in tissue may be demonstrated by smearing the tissue on a slide and allowing it to dry inverted,

over crystals of iodine. The glycogen appears as brownish areas in the cells. It may also be demonstrated by immersing in a mixture of four parts of alcohol and one part of tincture of iodine, sections that have been hardened in absolute alcohol, the glycogen assuming a port wine color.

Pathologic glycogenic infiltration occurs in pus cells of suppurating processes. The blood cells, especially leucocytes, contain some glycogen in those animals affected with septic infection or sapremia. Thus horses afflicted with sapremia induced by puncture wounds of the foot show glycogenic infiltration, of the blood cells. In diabetes mellitus the liver and kidney cells are infiltrated with excessive quantities of glycogen.

Etiology.—Disturbed carbohydrate metabolism is inseparably associated with glycogenic infiltration although the specific relation of disturbed carbohydrate metabolism and glycogenic infiltration is not known. Glycogenic infiltration has some association also with certain infectious and inflammatory disturbances as well as tumor formations.

Appearance.—*Macroscopic.*—Glycogenic infiltration does not produce lesions sufficiently characteristic to be recognized without the aid of a microscope.

Microscopic.—The affected cells contain transparent colorless areas near the nucleus. If the specimen has been hardened in absolute alcohol, the areas of glycogen may be stained port wine color by four parts of alcohol and one part tincture of iodine. The areas are variable in size depending upon the extent of the condition. In extreme cases the glycogen may be observed in the intercellular spaces.

Tissues Affected.—Liver, kidney, muscle, and blood cells are most subject to glycogenic infiltration, the frequency in the order named.

Effects.—The glycogen is readily reabsorbed provided the cause be removed. The condition being associated with other pathologic conditions, their removal becomes essential before the glycogenic infiltration can be overcome.

URATIC INFILTRATION.

*GENERAL DISCUSSION.**DEFINITION.**ETIOLOGY—Deficient uric acid secretion.**APPEARANCE.**Macroscopic.**Microscopic—Needle like crystals.**TISSUE AFFECTED—Articulations.**EFFECTS.*

Uric acid is formed by the kidneys from urea and passes out normally with the urine. If not promptly eliminated, it combines with sodium carbonate of the blood to form sodium urate (quadriurate and biurate). The quadriurates are unstable but the biurates are quite stable. Uric acid and urates do not normally exist as such in the blood of birds or mammals. The urinary excrement of birds is composed of urates but no urea. In birds the ureter terminates in the cloacum; the kidney excretion, which is almost solid in consistency, is thus mixed with the feces before it is eliminated from the body. This anatomic arrangement probably favors the resorption of uric acid. At any rate uratic infiltration is more common in birds than in any other domestic animal.

Sodium urate is the usual compound found in uratic infiltrations and when examined microscopically appears as a feltwork of radiating clusters of needle like crystals. If urate of sodium be treated with a few drops of nitric acid, and then evaporated to dryness, and to the amorphous residue a few drops of ammonium hydrate be applied, the entire mass assumes a purple-red color, or if potassium hydroxide be applied, the mass becomes bluish-purple.

Etiology.—Uric infiltration is due to deficient excretion of uric acid by the kidneys. It may be caused by ligation of the ureters or by any obstruction to these ducts. An exclusive meat or other nitrogenous diet, sometimes produces uratic infiltration in fowls. Old age is a predisposing factor.

Appearance.—*Macroscopic.*—The phalangeal, metatarsal and tarsal joints are most frequently affected in fowls. In the beginning the condition is evidenced by a soft, painful, diffuse swelling becoming more circumscribed as it becomes larger. The skin over the affected area becomes thickened and scales off as the swelling increases in size. The nodular swellings ultimately rupture, the contents being buff colored and crumbling as it is discharged. Sometimes masses of the urates accumulate as small stones (tophi) under tendons, etc. The articular surfaces are frequently eroded.

Microscopic.—The needle like crystals of sodium urate, in addition to more or less detritus from necrosis of the tissue, is characteristic of sections or smears of tissues affected with uratic infiltration.

Tissue Affected.—Articulations are the usual location of uratic infiltration, especially those in the metatarsal region. The skin and visceral organs may be affected.

Effects.—The accumulation of the urate crystals in the articulation, produces erosion of the articular surfaces, and thus interferes with movement. Tophi beneath tendons also produce disturbance of mobility.

KERATOSIS.

DEFINITION.

GENERAL DISCUSSION.

ETIOLOGY.

Dessication of surface epithelium.

Excess of intercellular cement.

APPEARANCE.

Macroscopic—Horny growths.

Microscopic.

TISSUE AFFECTED—Epithelium.

EFFECTS.

Epithelium becomes cornified thus forming the hard horny hoofs, horns and claws. The conversion of epithelium into horn-like substance (characteristic of the hoof) consists of a dehydration of the cells and the production of a glue like material that cements the dessicated cells together. The ergots and chestnuts in the skin of the horse are produced by the accumulation of dessicated cells cemented together.

The cornified epithelium that characterizes keratosis varies from dried scales to dense horn tissue.

Pathologic cornification is of rather common occurrence in the domestic animals. The skin covering the carpus of oxen frequently becomes materially thickened and cornified, one case having been observed in which the cornified mass accumulated until a projecting horn like structure some ten inches long and six inches in diameter at its base, was present. As a general condition it is observed in the skin of animals affected with ichthyosis.

Etiology.—Irritation appears to be a causative agent in keratosis. The condition may be a sequel of inflammation and sometimes occurs in scars. Whatever increases dessication of

epithelium and stimulates the formation of excessive quantities of cellular cement favors keratosis.

Appearance.—*Macroscopic.*—Keratotic accumulations appear like so much irregularly formed horn tissue. The resistance of the cornified epithelium varies according to the completeness of cornification.

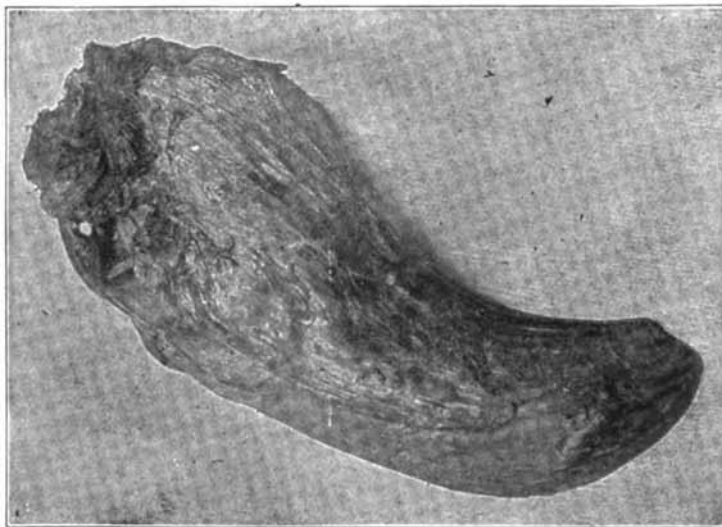


Fig. 119.—Photograph of a **Keratotic**, horn-like growth removed from region of withers of an ox.

Microscopic.—The cornified epithelium usually appears as a mass of debris, although in some instances there may still be evidence of cellular elements. The epithelial pearls of epitheliomata probably represent a type of keratosis,—the pearls appearing as whirls of scale like elements suggesting the gross appearance of a section of an onion.

Tissue Affected.—Epithelium is particularly affected. Some tumors are affected, especially epitheliomata.

Effects.—The area involved is inconvenienced. If the entire skin is involved there may be secondary constitutional lesions.

OSSIFICATION.

*PHYSIOLOGIC.**PATHOLOGIC.**ETIOLOGY.**Irritation.**Improper nutrition.**APPEARANCE.**Macroscopic—Osseous masses.**Microscopic—Osseous plates.**TISSUE AFFECTED.**Muscle.**Arteries.**Tumors.**EFFECTS.*

Ossification, as in the formation of bone, is a normal process. The process consists in the formation of fibrous lamellae that are later calcified. Osseous bodies are sometimes formed in such structures as the falx cerebri and tentorium cerebelli. These osseous formations assume the shape of the original structures, and are called osteophytes.

Pathologic ossification consists in the formation of a bone like substance in abnormal locations, as muscles, arteries, tumors, etc.

Etiology.—Ossification probably results from chronic irritation, improper circulation, or impoverished nutrition.

Appearance.—*Macroscopic.*—Ossified muscle appears as a porous osseous mass. In an autopsy of a horse the flexor brachii muscle, was found to be a porous osseous mass, and appeared like cancellated bone. Muscle ossification is usually designated myositis ossificans. An ossified falx cerebral or tentorium cerebellar osteophyte appears as irregular bony masses.

Microscopic.—The porous osseous tissue formed in pathologic ossification is found on microscopic examination to consist of osseous plates surrounding irregular cavities.

Tissue affected.—Muscle, arteries, connective tissue and tumors.

Effects.—Ossification occurs only when the normal structures have been practically destroyed. It represents a condition that is not reparable.

For differentiation of this condition and osteomata see discussion of the latter.

CALCAREOUS INFILTRATION.

*DEFINITION.**ETIOLOGY.**Impaired circulation.**Rickets.**Intoxication, Mercury, etc.**VARIETIES.**Tissue Spaces—Calculi.**Tissue.**TISSUE AFFECTED.**EFFECTS.*

Calcareous infiltration is a condition in which lime salts are deposited in abnormal locations or excessive quantities are deposited in those tissues in which calcareous depositions normally occur.

In the formation of osseous tissue, certain definite quantities of lime salts impregnate the softer formative tissue, thus producing typical bone. Considerable quantities of lime salts normally occur in the blood and lymph of the various animals. The urine of the horse, donkey, and mule frequently contains such large amounts of calcium phosphate that it is quite turbid when excreted. Excessive quantities of lime salt in solution predispose to calcareous infiltration as well as to calculus formation.

The lime salt most frequently found in tissues affected with calcareous infiltration is the carbonate, though other salts of lime may be present as the phosphate and rarely, the sulphate. These salts are all insoluble in water, alcohol, ether and chloroform, as well as most other solvents. The application of dilute acids usually cause excessive effervescence because of the liberation of carbon-dioxide.

Pathologic calcareous infiltration sometimes occurs in dense scar or cicatricial tissue as in extreme cases of poll evil, fistulous withers or quittors; in necrotic areas as tubercles of tuberculosis in cattle and hogs; in necrotic areas of arteries affected with atheromatous degeneration; in inspissated pus; in the supporting framework of the lungs producing pneumo-koniosis; in the kidney; and in other organs in chronic bichloride of mercury poisoning; in parasitic cysts, as the trichina cysts in hogs, and psorosperm cysts; and in dead foetuses.

Etiology.—*Imperfect circulation.*—Tubercular lesions (tubercles) are nonvascular and invariably become calcified sooner or later. Although tubercles are nonvascular, there is more or less enzymotic action taking place resulting in the liberation of carbon dioxide; there are variable quantities of fluid containing lime

salts in solution filtering into the tubercles; the liberated carbon-dioxide combines with the soluble lime salts forming insoluble calcium carbonate which is deposited in the tissue thus producing calcification. Enzymotic action is also present in local areas of tissue, other than tubercular, that have recently become necrotic, as inspissated pus, thrombi, infarcts, necrotic areas in arteries, and there is also sufficient soluble lime salts present to combine with the carbon-dioxide liberated by the enzymes to form insoluble calcium carbonate, thus necrotic tissue becomes calcareous.

Dense fibrous masses are frequently poorly nourished because of the obliterated vessels and occasionally become calcareous. Thus it is not rare to find calcareous centers in the dense fibrous tissue of fistulous withers.

Improper Food.—Food or water containing excessive quantities of certain lime salts predispose to calculus formation and in some instances to the deposition of lime salts in tissues as the kidney and lung.

Inhalation of air containing large quantities of lime or clay dust in suspension, results in their deposition in the alveoli of the lung, and infiltration into the framework of the lung producing the condition known as chalicosis. Horses and mules worked in and around cement plants, stone crushers, rock quarries, etc., are affected with pulmonary chalicosis and are more subject to pulmonary diseases than animals not so affected.

There are probably some **chemic substances**, resident in the body which when increased or diminished favor the deposition of lime salts. It may be that the chemic reactions of a tissue is a factor of considerable moment in calcareous infiltration.

Appearance.—*Macroscopic.*—Tissue affected with calcareous infiltration is hard, granular and gritty. When palpated, it is quite resistant and may be massive, but is more likely to be composed of small calcareous masses held together by variable quantities of soft tissue. It is gritty when incised or sawed and in some instances the tissue is so densely infiltrated that it is impossible to either cut it with a knife or saw, a chisel being required to break it asunder. Calcareous tissues are heavier than normal tissues. Tissue may be equally affected throughout or the calcareous material may be concentrated in small areas arranged concentrically around a central mass or in lines radiating from a central point. The calcareous material may appear in spherical masses as in the tubercular lesions or in scales as in arteries affected with athermatous degeneration. The air cells and bronchioles in the lungs of horses affected with chalicosis contain

incrustation of scales of lime and the framework of the lung may be infiltrated with small gritty calcareous masses.

Microscopic.—The calcareous material may be amorphous or crystalline and it may occur in the cells or between the cells. Cellular calcareous infiltration normally occurs in the cells of the pineal body and pathologically in kidney cells, nerve cells, etc. The calcareous granules or crystals are usually stained dark with hematoxylin and give the general impression that chromatolysis (fragmentation of the nucleus) had occurred.



Fig. 120.—Atheromatous Degeneration, Aorta.
a. Calcareous deposit in the tunica media.

Calcareous material infiltrated between the cells may be amorphous or crystalline and assumes the same stains and appears similar to the intracellular infiltrated lime salts. The calcareous material is soluble in dilute acids, except calcium sulphate, with more or less effervescence.

Tissue Affected.—Necrotic tissues are most subject to calcareous infiltration. Blood vessels, lung tissue, kidney tissue, dense fibrous tissue, are also subject to calcareous infiltration.

Effects.—Calcareous infiltration is a means of converting necrotic tissue into a noninjurious mass. Calcified tissue is probably never regenerated because calcareous deposits are not absorbed.

CACULI.

DEFINITION.
ETIOLOGY.
STRUCTURE.
SHAPE.
SIZE.
NUMBER.
COLOR.
COMPOSITION.
VARIETIES.
Urinary.
Salivary.
Gastric.
Intestinal.
Biliary.
Lacteal.
Venous.
Arterial.

Calculi are accumulation in the body cavities, of mineral matter precipitated from the body fluids, or they may be mineral incrustations upon foreign substances in the body cavities. The mineral deposits formed within the tissues of the animal body, as calcified tubercles, etc., are calcareous infiltration or tissue petrification. Calculi, however, may and frequently do, become attached to the tissue, surrounding them (phleboliths), and a calcified tissue may become separated from the surrounding structures (calcified necrotic tissue in fistula). Hence the two conditions, calculus formation and calcification, approximate each other closely and at times are not separable.

Etiology.—The causes of calculus formation are not thoroughly understood. The most probable cause is the supersaturation of the body fluids with salines. The fluids may become super-saturated either by an excessive production of the salines or diminished excretion of them. The lack of oxygen or an excess of carbon dioxide may cause the precipitation in body fluids, especially of calcium and magnesium carbonates. Fermentation of various juices may result in precipitation of a variety of compounds. But why the precipitate should accumulate as a calculus is unexplained. It is a phenomenon not understood. There are many predisposing causes that aid in the formation of calculi. The retention or delay in the excretion of fluids, especially if they undergo any chemical change, are principal factors in calcular formation. Intoxication from mercury predisposes to the formation of urinary calculi. The presence of any foreign body, as particles of sand, desquamated cells, coagulated albumen, parasites, etc., upon which a precipitate may accumulate, is a predisposing cause. According to Ziegler all calculi have an

organic nucleus. But it seems possible and quite probable that particles of inorganic matter are deposited upon an inorganic nucleus in the formation of calculi.

Structure.—The structure of calculi varies. Homogeneous calculi are composed of layer upon layer, of the same material and have the same appearance throughout. Heterogeneous calculi are laminated, i. e., they are composed of layers of different material and appear different in the succeeding layers. Calculi vary from finely granular masses (appearing as though many grains of sand had been fused into a mass) to lobulated masses (mulberry calculi); or they appear smooth as though they were molten mineral run into forms.

Shape.—Calculi assume all conceivable shapes. Cystic calculi vary in form from spheres to jack straws, and even coral like bodies or stalactite calculi have been observed. Their form may be determined by their location. Thus renal calculi may assume the shape of renal tubules, renal pelvic calculi the shape of the renal pelvis. Intestinal calculi are usually more or less spherical in shape. Salivary calculi are ovoid. Calculi may be faceted when occurring in large numbers.

Size.—The size of calculi varies from the finest sand-like grains to enormous accumulations. A 228-gram (7 oz.) cystic calculus was removed from a Jack, by Dr. McCassey, Concordia, Kansas. A 260-gram (8 oz.) cystic calculus was removed from a five-year-old Jack at the Missouri Valley Veterinary Association clinic in February, 1907. Dr. Z. C. Boyd, in 1906, removed from Steno's duct, in a horse, a salivary calculus weighing 125 grams (4 oz.).

Number.—The number of calculi occurring in one animal is quite variable. There has been a case reported in which there were over 300 cystic calculi in one dog, although that is an unusual number.

Color.—The color of calculi is determined by their composition. Thus biliary calculi are highly colored because of the bile pigment, bilirubin and biliverdin, that they contain. Enteroliths are usually colored from the intestinal contents. Arterioliths and phleboliths are colored with hemoglobin or some of its derivatives. Urinary calculi may be gray, brown, yellow, or even red, depending upon their composition. Salivary calculi may be chalk white or tinged with various colors.

Composition.—A variety of chemical compounds are found in the various calculi. Urinary calculi may contain cystin, xanthin, urates, oxalates, carbonates, phosphates, calcium, magnesium, etc. Cystin and xanthin urinary calculi are quite rare.

Urates are common in renal tubular calculi, also in cystic calculi of dogs and cats. Carbonates predominate in cystic calculi of the horse and ox. Ammonium-magnesium-phosphate is the principal compound in cystic calculi of the sheep and hog. Urethral calculi are of the same composition as cystic calculi of the

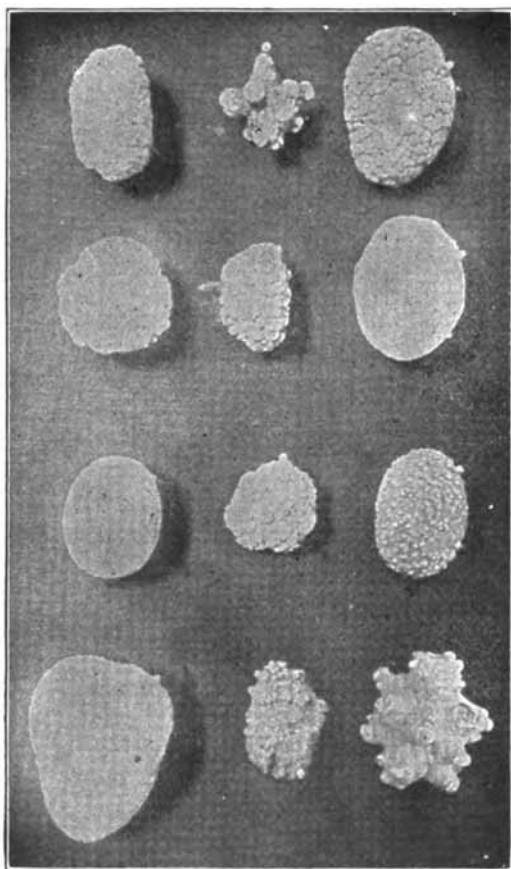


Fig. 121.—Group of Calculi, showing a variety of shape.

same animal. Preputial calculi are usually composed of carbonates in the horse and of phosphates in the ox and sheep. Biliary calculi may be composed of carbonates or phosphates, but are more frequently composed of calcium biliverdin. Enteroliths may contain a large nucleus of fecal matter or hair which becomes permeated and incrustated with calcium or magnesium carbonates, phosphates, sulphates, or oxalates. Salivary calculi,

arterioliths, and phleboliths are usually composed of the carbonates and phosphates of calcium and magnesium. Lacteal calculi are composed chiefly of phosphates.

Varieties.

Urinary Calculi are of frequent occurrence and may be conveniently classified according to the location in which they occur.

1. Renal tubular calculi are most common in dogs and cats, but may occur in horses, cattle and hogs. After formation they frequently pass into the pelvis of the kidney and the urine may wash them down through the ureter into the bladder and some-

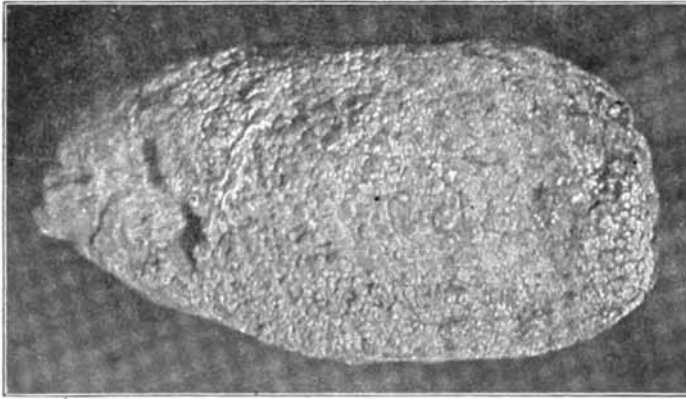


Fig. 122.—Photograph of a 7 ounce Cystic Calculus successfully removed from the bladder of a Jack.

times on out of the animal body. They may obstruct the tubule causing retention of urine with distension of the tubule and frequently cyst formation.

2. Renal pelvic calculi are not rare, the pelvis of the kidney sometimes being completely filled with a calculus. This variety has been observed in the hog, dog, cat, horse, and sheep, the frequency in the different animals being in the order named. A 7-gram ($\frac{1}{4}$ oz.) renal pelvic calculus was obtained in 1906 from a horse used for dissection purposes at the Kansas City Veterinary College. G. H. Woolridge, of Dublin, describes a case of calculus formation in the renal pelvis of a horse (*Veterinary Journal* for June, 1907) in which the entire kidney was practically replaced by the calculus. The results of calculi in the renal pelvis depend upon their extent. Complete obstruction necessarily results in the retention of urine followed either by its resorption (producing uremia) or its accumulation (form-



ing a cystic kidney). The former condition is common in dogs, the latter in hogs.

3. Ureter calculi have been observed but are rare.

4. Cystic or vesical calculi are the most common of all urinary calculi. Dogs and cats are quite subject to them, occurring more frequently in the older animals, but the puppy and kitten are not exempt. Bitches and castrated male cats are especially subject to cystic calculi. Jacks are frequently affected with cystic calculi, horses, goats, sheep and cattle less frequently. A cystic calculus 18 x 20 cm. (7 x 8 inches) was successfully removed from a 2-year-old colt by Dr. E. S. Fry, of




Fig. 123.—Urinary Calculi
1. Preputial calculus. 2. Renal pelvic calculi.

Naperville, Ill. Cystic calculi may cause no inconvenience or they may produce sufficient irritation to establish a severe cystitis. They may obstruct the urethral opening resulting in retention of urine and rupture of the bladder. Frequently they become imbedded in the walls of the bladder, and may cause dilatation or pouching of its walls. Sometimes the calculi pass out of the bladder and become lodged in the urethra, resulting in retention of urine, difficult micturition, and usually urethritis.

5. Urethral calculi are common in old dogs, also in the bull and ram, and have been observed in the horse. They occur in the urethra, in the beginning of the gutter of the os penis in the dog, usually in the first curve of the penis in the bull, just posterior to the meatus urinaris in the ram and at the ischial arch



in the horse. They usually cause difficulty in micturating and may completely obstruct the urethra with the same results that are produced by occluding the urethral opening of the bladder. Urethral calculi may produce erosions of the urethra and surrounding tissues and thus, produce an artificial urinary canal through which the urine will be discharged, this is probably more common in male bovines, than in other animals. About 200 urethral calculi were observed in the urethra of one steer by Dr. B. F. Kaupp.

6. Preputial calculi sometimes occur in geldings, although these are more frequently accumulations of the secretion from the adjacent sebaceous glands. W. Williams reported cases in which there was formation of stalactite bodies in the prepuce of oxen and sheep that had been fed food material containing a large per cent of phosphates. A preputial calculus weighing 11 grams ($\frac{1}{3}$ oz.) and another weighing 10 grams were obtained from a hog by a veterinary inspector.

Salivary calculi occur most frequently in the horse, although they do occur in the ass, ox and sheep. Their formation depends upon the ingested water containing a large quantity of carbonates of potassium, sodium and magnesium and the presence of calcium salts in the saliva. (Dr. J. M. Lawrence, Veterinarian U. S. Army, Fort Wingate, N. M., operated upon two horses, removing from Steno's duct in each a salivary calculus. In the center of one of these calculi an oat grain (nucleus) was




Fig. 124.—Photograph of a Salivary Calculus removed from Steno's Duct, horse.

found upon which the deposit had taken place. This calculus weighed 19 grams ($\frac{2}{3}$ oz.) The result of salivary calculi is to obstruct the outflow of saliva, the retention of which in the smaller ducts may cause inflammatory, degenerative or atrophic changes in the gland, and if the calculi are not removed the destruction of the gland or the rupture of the duct and a salivary fistula. Tartar on dogs' teeth has an origin similar to that of salivary calculi.

Gastric Calculi (gastroliths) occur in the paunches or reticula of cattle, sheep and goats. They are exceptionally rare in the horse and hog, and probably never occur in dogs and cats.

Intestinal Calculi or enteroliths are found in the large intestine of the horse, especially those fed upon bran. These calculi are composed primarily of ammonio-magnesium phosphate, the magnesium phosphate being dissolved out of the bran by the acid of the gastric juice and uniting with nascent ammonia forming an almost insoluble phosphate. Enteroliths may be of enormous size, in some cases, weighing as much as ten kilograms (22 lbs.). These calculi are likely to cause erosions of the mucous




Fig. 125.—Photograph of an **Intestinal Calculus** having a circumference of 12 inches and weighing 3 pounds.

membrane as well as obstruction of the lumen of the intestine. Linch, of Albany, N. Y., reported a case in the Review, 1906, in which a calculus weighing 3.4 kilograms (7½ lbs.) was found. Gage reported a case in which a calculus weighing .9 kilograms produced fatal results. Hodgkins and Son of Hanley, England, recently obtained three enteroliths, each weighing 1.6 kilograms (3½ lbs.) from the intestine of a horse.

Biliary Calculi (Choleliths) are not rare in the domestic animals. They vary from the size of a pea to a baseball, are tinted yellow, brown, red, green, or may be chalk white in color. Frequently they occur in large numbers, are variable in shape, and structure. They are usually composed of biliary pigments in

combination with calcium, although carbonates and phosphates are common ingredients. Biliary calculi may form in the biliary collecting tubules of the liver in the bile duct or in the gall bladder. The results of their presence depend upon their location and size. If they are small and cause no obstruction there will be no inconvenience from them. If they are of a size that they can be forced through the bile ducts they will produce severe colicky pains at the time of passage. They may be sufficiently large to obstruct the bile duct of some principal collecting tubule and produce a stagnation and resorption of bile, resulting in

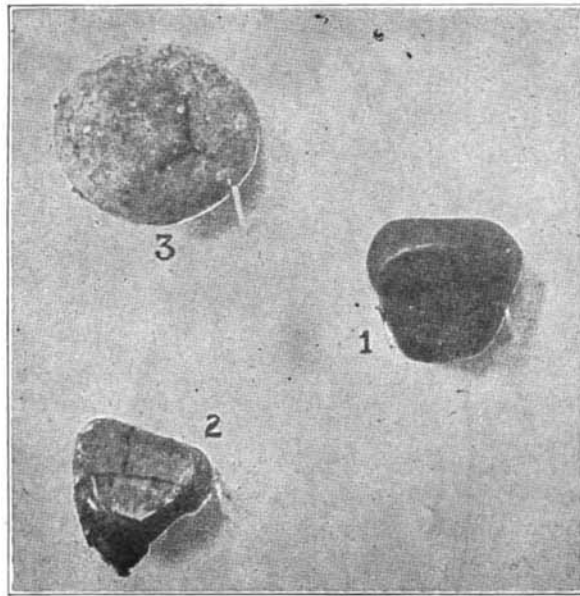


Fig. 126.—Biliary Calculi, Ox.
 1. Showing Facets. 3. Showing Crevice.
 2. Showing Facets and Lamination.

various disturbances because of the presence of the bile in the blood.

Lactal Calculi (galactoliths) may be formed in the galactophorus sinuses, particularly of the ox. They are usually composed of calcium phosphate.

Phleboliths or calculi in veins have been observed by Spooner in abdominal veins and by Simmonds in the jugular vein. They are probably the result of calcification of thrombi which have later become detached from the vessel walls and are true calculi. They produce an obstruction in the vessels in which

they occur. They may be of slight significance or may cause a fatal termination, depending upon the importance of the vessel and extent of the collateral circulation or anastomoses. These calculi are usually composed of calcium compounds.

Arterioliths are calculi formed in arteries. Their cause, formation, composition and termination being practically the same as that of phleboliths.

Lithopedia are calcified foetuses. In extra-uterine foetation the foetus occasionally lives only for a short time. Dead extrauterine foetuses frequently become impregnated with lime salts, producing the so-called lithopedia. Lithopedia may also occur within the uterus. This class of calculi is quite common in swine and some cases have been observed in cattle and sheep.

CONCREMENTS.

DEFINITION.

ETIOLOGY.

VARIETIES.

- Hair balls.*
- Fecal matter.*
- Bile.*
- Pus.*
- Milk.*
- Cerumen.*

Concrements are accumulations of organic material in the cavities of hollow organs. Their effects are practically the same as the effects of calculi. Their formation depends upon the collection and massing together of organic substances derived either from the body in which the concrements occur or from some extraneous source. They may be homogeneous or heterogeneous in structure; oval, spherical, or angular and faceted in shape, variable in size, color and number, (873 oat hair concrements were found in the great colon of a horse by C. Roberts, M. R. C. V. S.). They may be composed of hair, mucus, fecal matter, casein, inspissated pus or bile, ingesta of various kinds, etc.

Hair Balls (Egagaropiles) are accumulations of hair into masses. They occur most frequently in animals that lick themselves as the ox and deer. Other animals are affected as the hog, dog and cat, also man, especially barbers, hair-sorters, hair-dressers, etc. Dr. A. Trickett observed a Persian cat that vomited a mass of hair $\frac{3}{4}$ -inch in diameter and 3 inches long. Egagaropiles vary in size from a pigeon's egg to a basket ball. They are in some cases simply masses of hair in others they are impregnated and incrustated with mineral substances, giving them

the appearance of calculi. Hair balls incrustated with mineral salts taken from the deer by someone's grandfather or great-grandfather is the ordinary "mad-stone" in use at the present time. Recently a hair ball (bristles) completely filling the stomach was obtained from a hog slaughtered in a packing house. Hair balls are usually found in the abomasum or large intestines of the ox and in the stomach or large intestine of the hog. The presence of a hair ball produces the same effects that would be produced by any other indigestible body of the same size in the same location.

Fecal Concrements.—The intestinal contents may accumulate into compact masses. These concrements interfere with the

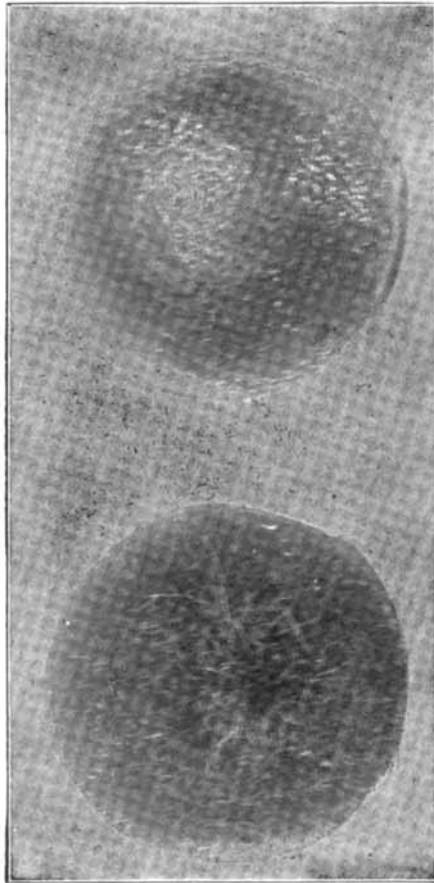


Fig. 127.—Hair Balls.
(Egagropilae.)

movement of food-stuff through the canal and may completely obstruct it. Appendicitis in the human is frequently a result of a fecal concrement in the vermiform appendix. These concretions occur most frequently in the horse, dog and cat. They are usually composed of cellulose in the horse, of bones and bone fragments in the dog and cat. The large intestine is the usual location of them in the horse and the small intestine in the dog or cat. Maxwell reported a case in which alfalfa accumulated in the large intestine of a horse, the concretions being from 17½ to 22½ cm. (7 to 9 inches) in diameter. The fine hair of clover or oats frequently accumulates and forms concretions. The results of fecal concretions depend upon either mechanical interference in the passage of intestinal contents, erosion of the intestinal mucous membrane or perforation of the intestinal wall, or a combination of two or more of the above.

Inspissated Bile.—If the outflow of bile is obstructed it will become condensed or inspissated to a degree depending upon the length of time of obstruction. Inspissation of bile frequently occurs. The animals most frequently affected are the ox and hog. An ox liver, containing several concretions composed of inspissated bile in the interlobular ducts, was recently presented to the Kansas City Veterinary College museum. Bile in this condition may form masses which in general appearance resemble biliary calculi. It is sometimes impossible to differentiate biliary calculi from inspissated bile, and, in fact calculi are

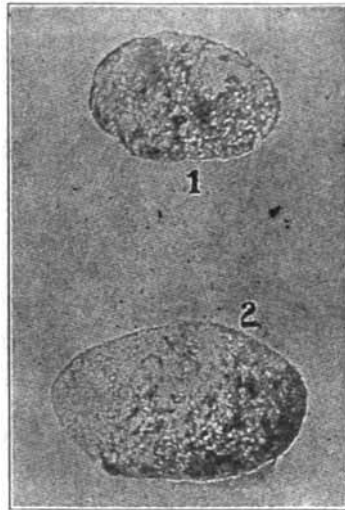


Fig. 128.

1. **Inspissated pus** from long abscess. 2. **Inspissated pus**, guttural pouch, horse.

frequently of secondary origin, the thickened bile forming the nucleus. The results of inspissated bile depend first upon the resorption of bile into the system and, second, upon the absence of bile in the intestine.

Inspissated Pus.—Empyema sometimes terminates, when there is no surgical interference, in resorption of the liquor puris, after which the solid constituents frequently mass together, forming concrements. These concrements may form in any cavity in which the suppuration is slow going or chronic, provided the movement of the part is limited. Their formation has been noted in the guttural pouch. After formation they may become calcified. They are of little importance except as pathologic phenomena.

Lacteal concrements result from the coagulation of the casein of milk and its accumulation in the galactophorous sinuses. These concrements occur in the cow and can usually be expelled through the lacteal duct by manipulation.

Ceruminous concrements occur in animals in which the hair or wool extends far into the external auditory meatus. They are composed of cerumen and are the result of an excessive production or limited excretion of it. They may form into sufficient masses to completely occlude the external auditory canal and thus interfere with hearing. Concrements have been found in the bronchial tubes. Their formation depends upon the accumulation and condensation of mucus or purulent fluid. They may obstruct bronchioles and produce atelectasis.

Prostatic concrements frequently occur in old dogs. They are present in many of the enlarged prostate glands. They consist of masses of accumulated colloid-like material. The results depend upon the pressure that they may exert. Thus there may be an obstruction to the outflow of urine.

PIGMENTARY CHANGES.

Physiologic pigmentation is variable. The color and extent of pigment varies in different animals and in the same animal under different conditions. All physiologic pigmentation is the result of deposition of hemoglobin or some of its derivatives.

The skin of animals is usually extensively pigmented, with the exception of albinos and some white skinned animals not albinos. The production of the cutaneous pigment is not well understood but probably results from metabolic activity of the deeper layers of epidermal cells. Because of the intense cutan-

eous pigmentation of animals, erythema, hemangiomas and other pathologic processes are not as evident as like conditions in the human. The excessive cutaneous pigmentation protects the skin from the injurious influences of sunlight.

Hair, wool, fleece, fur and feathers are variously colored, the color depending upon the soluble pigment in the cortical portion of the cutaneous appendages. The color of the skin is usually an index to the color of the hair or similar epidermal appendages. The color of hoofs, horns, and claws is probably dependent upon cutaneous pigment.

Voluntary muscle tissue is pigmented with varying quantities of hemoglobin, excepting the so-called white meat of fowls (the sternal muscles and muscles of the pectoral arch). The pigmentation of the voluntary muscles varies in the different animals. The equine muscles are the most intensely red, the intensity of pigmentation in the muscles of other animals being in the following order: bovines, ovines, porcines, canines, felines. The flesh of duck and quail and the dark meat of other fowls is darker even than equine muscle. Heart muscle is very dark in color because of the excessive quantities of pigment. Gizzard muscle is intensely pigmented. Involuntary muscle of all animals is very light in color, because of the limited quantity of pigment contained. The significance of the pigmentation of muscle is not known, possibly the hemoglobin of the muscle cell has some important metabolic function.

The mucous membrane, particularly of the mouth, is frequently pigmented. The buccal mucous membrane of the sheep and dog is often black. The uterine mucous membrane of the bitch is occasionally quite black as a result of pigmentation derived from the uterine glands; and no doubt is indirectly a derivative of hemoglobin.

Bones, especially the internal portion of the articular extremities, are frequently pigmented from the red marrow that occupies the spaces in the cancellous bone.

The liver and spleen are naturally deeply pigmented because of the excess of free hemoglobin in those organs. The kidney also appears pigmented, probably because of the excess quantity of blood contained in it. The choroid tunic of the eye is deeply pigmented with a substance not unlike melanin, the purpose of which is to absorb rays of light.

EXCESSIVE PIGMENTATION.

(Hyperchromatosis.)

DEFINITION.**ETIOLOGY OR SOURCE.***Hematogenous.**Hemoglobin.**Hemosiderin.**Hematoidin.**Hepatogenous.**Bilirubin.**Biliveridin.**Cellular.**Suprarenal—Addison's disease.**Tumor—Melanin.**Pregnancy.**Freckles.**Extraneous.**Pneumonokoniosis.**Anthraxis—Carbon.**Siderosis—Iron.**Chalicosis—Lime.**Kalinosis—Clay.**Argyriasis—Silver.***TATTOO.****EFFECTS.**

Excessive pigmentation, also known as pigmentary infiltration, is a pathologic condition characterized by the presence of an excess of pigment in the tissues. Pathologic pigmentation is quite common. Icterus, melanosis, and anthracosis are types of pathologic pigmentation. This condition may be congenital as melanosis maculosa of calves, or it may be acquired as in icterus.

Etiology.—In pathologic pigmentation the coloring matter may be derived from internal sources, as *blood, bile and cells*, or from external sources as *coal dust, silver, lead* and various pigments.

BLOOD.—Pigmentation as a result of deposition of hemoglobin of the blood is designated hematogenous pigmentation. Hemoglobin is the principal hematogenous pigment, although hemosiderin and hematoidin, both derivatives of hemoglobin, are of some importance.

Hemoglobin is the normal coloring matter of the red blood cells and muscle. It constitutes about 90 per cent of the solids of red blood cells. It is a compound proteid and exists only in combination with lechithin. Hemoglobin splits up readily into

globin and hemochromogen, the latter combines with oxygen to form hematin.

Hemoglobin is liberated from the red blood cells in all conditions in which there is rapid destruction of these cells, as in tick fever, anthrax, hemorrhagic septicemia, toxic doses of chlorate of potassium, lead poisoning, etc. A portion of the liberated pigment is eliminated by the liver and kidneys, thus excessive quantities of bile and bloody urine (hemoglobinuria) are a feature of tick fever, lead poisoning, etc. The liberated hemoglobin not eliminated from the body is deposited, especially in the vessel walls, but ultimately diffuses into the lymph and infiltrates practically all tissues. Post-mortem staining is the result of hemoglobin deposition into the dependent tissues. Hemoglobin is also liberated from muscle tissue in azoturia and other diseased conditions of muscle. The hemoglobin liberated from muscular tissue is disposed of in the same way as that derived from red

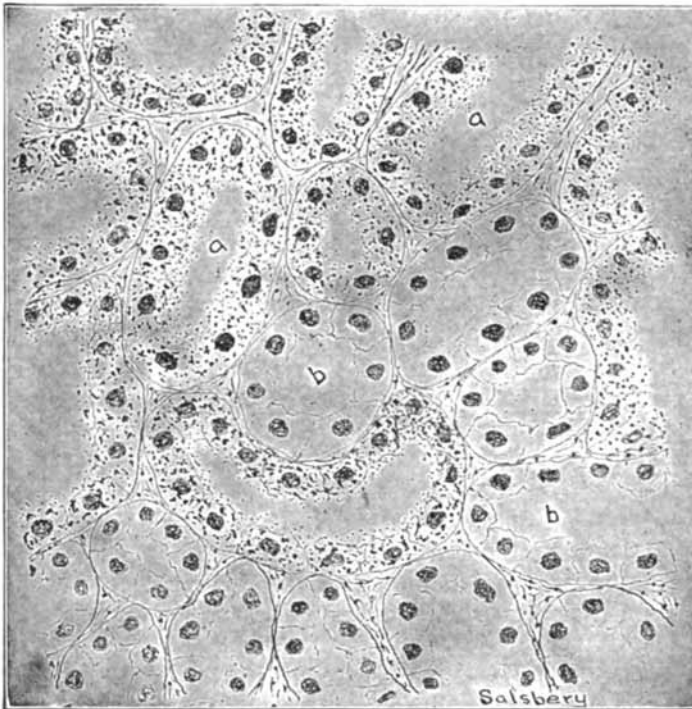


Fig. 129.—Haemosiderin Pigmentation.

- a. Tubules containing deposits of haemosiderin in the cells
 b. Normal kidney tubules.

blood cells. Hemoglobin pigmentation, the results of bruising, is common in the superficial tissues of animals slaughtered immediately after shipping.

Hemosiderin is a derivative of hemoglobin. It is yellowish brown in color, is insoluble in water, alcohol, ether, chloroform, dilute acids and alkalis. It contains iron and gives the typical iron reaction with potassium ferrocyanid. Hemosiderin is the common pigment observed in tissues that have been previously stained with hemoglobin. Extravasated blood observed in petechiae and hematmata appear as typical hemoglobin pigmentation for a few days, after which the hemoglobin is converted into hemosiderin and the affected parts become a yellowish brown. Hemosiderin pigmentation is observed in tissues of animals that have been bruised three or four days prior to slaughter. It is also observed in post-mortem examinations of animals that have been affected with diseases accompanied by hemorrhages for a period of three to five days, as purpura hemorrhagica, acute tick fever, anthrax, etc. Hemosiderin pigmentation is of common occurrence in tumors.

Hematoidin is an iron free pigment, probably derived from hemosiderin. It is soluble in chloroform, but is insoluble in water, alcohol and ether. It occurs in rhombic crystals and is occasionally observed in old hemorrhagic foci.

Blood pigments, hemoglobin, hemosiderin, and hematoidin are deposited in the cells and intercellular substances. The pigments are removed by solution and resorption of the dissolved pigment or by leucocytes which incorporate the insoluble pigment granules and carry them out.

Blood pigmentation has little effect upon the tissue in which deposition occurs, but the flesh of food producing animals is usually condemned when pigmented because of its unsightly appearance.

The deposition of a brownish or blackish pigment in bones (ochronosis) is occasionally observed in the carcasses of cattle which were apparently in good health. The cause of this pigmentation is unknown. It probably does not injure the tissues or the meat for food, but such meats are usually condemned because of their unsightly appearance. Another brownish pigmentation of muscular tissue (xanthosis) is associated with muscular atrophy or disease of the suprarenal bodies. This condition is of no consequence except public sentiment prevents the sale of such meat.

BILE pigmentation results from the resorption of bile and its

deposition in the tissue. Bile pigmentation is designated hepato-genous pigmentation and the condition produced is commonly known as icterus or jaundice. Obstruction of the bile duct or any of its radicles by pressure, duodenitis, calculi, etc., will result in retention of the generated bile which is later resorbed into the blood. Destruction of considerable numbers of liver cells or diminution of their function may possibly result in the retention in the blood of those products that are normally converted into bile, and thus produce a hematogenous icterus. Excessive production of bile, as in acute tick fever, is frequently accompanied by resorption of some of the bile and its deposition throughout the body, thus producing a generalized icterus.

Bile staining is most evident in the conjunctiva and ocular sclera of the living animal where it produces a lemon or greenish yellow discolorization. If resorption of bile is very extensive it may appear in the urine. In carcasses, biliary pigmentation is most evident in the adipose tissue, especially the subcutaneous fat, although it is usually well marked in the subserous fat and may be detected in the lymph nodes, spleen, kidney and muscular structures.

The bile may be deposited in the cells or between the cells as greenish-yellow amorphous granules. The granules are readily soluble in alcohol, hence they are best detected in frozen sections.

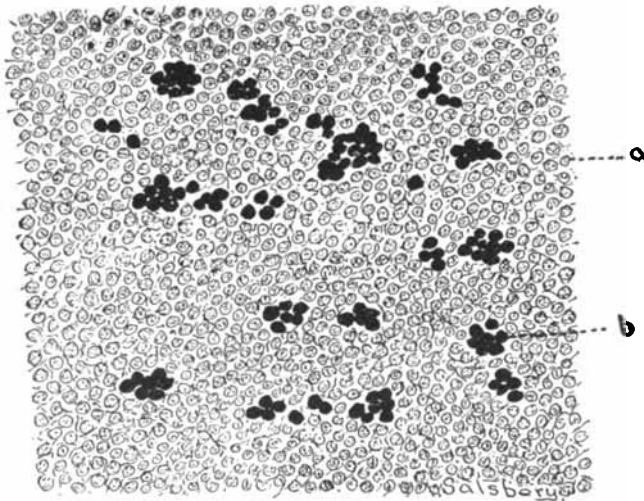


Fig. 130.—Icterus affecting lymphatic tissue.
 a. Normal tissue. b. Deposit of bile pigment.

The effects of resorption of bile are variable. The tissues are discolored; there may be pruritus, as the bile appears to act as an irritant on nerve endings; putrefactive changes may occur in the intestine, and the heart may be depressed. Other inconstant symptoms may appear, especially if the quantity of resorbed bile is large.

CELLS.—Aside from hematogenous and hepatogenous pigmentation the products of certain body cells become a factor in hyperchromatosis.

The principal pigment produced by cellular activity is melanin. Melanosis maculosa is a congenital, cutaneous, pathologic pigmentation of calves resulting from the excessive production of melanin by cutaneous cells in certain areas.

Melanotic deposits are of common occurrence in the various glandular tissues, especially the liver, kidney, and suprarenal glands. The deposits in the glandular tissue may occur in the cells or intercellular spaces, and may appear as irregular yellowish-brown or black masses. Melanin may occur in the form of fine granules or be flocculent. Black kidneys are occasionally observed, in abattoirs, especially in hogs. These usually result from deposition of delicate, flocculent masses of melanin in the kidney cells.

Melanosis is of most frequent occurrence in white animals, although it has been observed in Aberdeen angus cattle, red short horns, black and bay horses, and black and red hogs.

Melanotic tumors are pigmented with melanin. The melanin may be a product of the tumor cells or of the adjacent tissue cells. The principal melanotic tumors are the melano-sarcomata, although there may be a benign melanotic tumor called a melanoma.

In a disease of the suprarenal capsule in the human (Addison's disease) there is a peculiar bronzing of the skin. This condition has not been noted in the domestic animal, probably because of the dense pigmentation of the skin. It is thought to be a form of melanosis.

A pigmentation has been noted in atrophic tissues, especially atrophied muscles. The pigment of atrophic muscles may be the result of disturbed cell metabolism or it may result from concentration of the pigment, because of the diminution in the size of the cells. Brown atrophy of the heart is a condition in which pigmentation is prominent.

Freckles are pigmented areas of the skin in the human, the result of cutaneous cellular action. Because of the intense pig-

mentation of the skin in domestic animals, freckles are not easily observed, except in white animals.

Pregnancy in the human is frequently accompanied by localized pigmented cutaneous areas. Such areas have not been recorded in domestic animals.

Aside from the blood, bile and cellular activities, pigments may be introduced into the body from without.

The most common external substance that produces pigmentation is carbon. The most extensive pigmentation by carbon is in the lung, producing the condition known as anthracosis. Anthracosis is a common condition in the lungs of animals used in and around coal mines, in cities in which there is large quantities of coal smoke, in cats and other pet animals confined in coal bins, engine houses, etc. The inhaled carbon is largely excreted in the mucus discharged from the respiratory tract, although some of it is deposited in the epithelium of the air cells, and ultimately may be found in the interstitial tissue of the lung. Anthracosis apparently produces little harm unless it is excessive, when it predisposes to inflammatory disturbances. When examined in gross the lungs vary in color from a gray to a deep black. Microscopically small particles of carbon may be observed in the cells and intercellular substances of the lung tissue.

Argyriasis is a condition in which silver is deposited in a tissue. After the silver is deposited it is combined with sulphur, thus forming silver sulphid, which is brownish black and imparts a similar color to the tissue. Argyriasis is not common in animals except those used in and around silver smelters or as a result of the application of some silver preparation to the tissues.

Siderosis is a condition in which iron is deposited in a tissue. Iron, like silver, usually combines with sulphur, forming the sulphid, which is brown or black in color. Siderosis is not common in domestic animals, except in the intestinal epithelium of animals that have been medicated with iron preparations.

Hydrargirosis is a condition resulting from the deposition of mercury in a tissue. This condition is present in the intestinal mucosa after medication with calomel or other mercury preparations. The mercury sulphid, which is brown or black in color, is the usual pigment in hydrargirosis.

Plumbosis is a term applied to pigmentation with lead. This form of pigmentation may be evident in the intestine in chronic lead poisoning. It appears as a bluish black pigment.

Tattooing is the introduction of insoluble pigments into tissues. In tattooing, the tissues are first punctured or injured, after which some insoluble pigment is introduced into the wounds.

Some of the pigment is carried out by leucocytes and some of it is entangled in the cicatrix of the healing wound, where it remains permanently. Tattooing is a very valuable means of marking stock, as it gives a positive means of identification. Registered cattle, horses, sheep, hogs, dogs, etc., are tattooed in the ear, and fowls on the legs. The wound is made with an instrument similar to a hog ringer, in which slugs containing needle points arranged in the form of figures or letters are used. This instrument is used to punch holes into the inner surface of the external ear, immediately after which carbon is rubbed into the wound. When the wounds are healed, the tattoo may be easily observed.

Effects.—Excessive pigmentation of a tissue or tissues is of little pathologic significance. Pigmented tissues are probably not hindered in their physiologic activities, excepting in so far as the cause of the pigmentation is an etiologic factor in the disturbance of the functioning of a part. Icteric pigmentation is of consequence because of the action of the bile upon nerve cells.

Pigmentation, especially when excessive, is a basis for the condemnation of meat and meat products because of public sentiment.

ABSENCE OF, OR DIMINISHED PIGMENTATION.

(Hypochromatosis.)

Visible pigmentation may be less than normal, and in some instances there is a complete absence of pigment. Areas containing less pigment than normal and depigmented areas are permanently white in color, as they are not affected with sunlight or any other conditions that tend to produce pigmentation. This condition may be of antenatal or postnatal origin.

Etiology.—Antenatal absence of, or diminished pigmentation may be inherited or it may be caused by disturbances of the embryonic cells that produce normal pigmentation. Postnatal absence of, or diminished pigmentation is usually the result of disease in which areas of tissue have been destroyed and later substituted by cicatricial tissue.

The total absence of pigment (achromatosis) is not of common occurrence, being most frequent in rabbits, birds and rats (albinos). An albino is an animal devoid of cutaneous and choroid pigment, the condition being inherited or congenital. The animals thus have white skin and usually white hair and their eyes are pink or red because of the absence of choroid pigment,

the blood being observed through the transparent ocular structure. The so-called "Wall-eyed" horses have little if any pigment in the choroid tunic, and frequently they have depigmented localized cutaneous areas.

Depigmentation is probably never generalized. Permanent localized depigmentation, leucoderma or vitiligo, is a characteristic symptom affecting the external genitals of horses afflicted with dourine. It is also observed in cicatrices resulting from burns or extensive operative procedure. Surgeons usually make incisions in an oblique direction in order that the hair in the adjacent skin may cover the scar. Scars are usually devoid of hair, and when hair is present it may lack pigment. The application of some medicaments on the skin of some animals causes the hair to lose its pigment.

Temporary depigmentation is evident after an attack of coital exanthema, vaginitis accompanied by an ichorous discharge, and by many other conditions characterized by erosion or necrosis of cutaneous tissue.

Effects.—The absence of pigment is of no serious consequence except in some animals. Hogs that are white skinned cannot be raised in some localities because of the effects of the sunlight. Depigmentation of the choroid is also of some consequence, because the eye is exposed to the effects of excessive light.

CHAPTER IX. NECROSIS AND DEATH.

NECROSIS.

DEFINITION.

ETIOLOGY.

Suspended nutrition.

Thermic.

Burning.

Freezing.

Chemic.

VARIETIES.

According to cause.

Inanition.

Thermic.

Chemic.

According to character of necrotic tissue.

Coagulation.

Colliquation.

Caseation.

Gangrene.

Mummification.

Miscellaneous.

Senile.

Fatty.

Focal.

Jack-sores.

TISSUES AFFECTED.

DISPOSITION OF NECROTIC TISSUE.

Absorption.

Exfoliation.

Encapsulation.

Sequestration.

EFFECTS.

Necrosis is local death. It is death of a part of the living body. The term necrosis is applicable to the death of any kind of tissue, glandular, muscular, osseous, etc. Necrosis is usually a rapid process, that is, it is sudden death of a part. Death of a cell or a group of cells that have been previously affected with degeneration, i. e., a slow or lingering death, is termed necrobiosis. Caries is a term used to designate necrosis of dentinal or osseous tissue.

Cells are constantly worn out and destroyed in physiologic active tissues. The physiologic destruction of cells is not usually thought of as necrosis although the cause and manner of death may be similar, and there may be no difference in the appearance of cells destroyed by physiologic and pathologic processes.

The term necrosis is applicable to the pathologic death of a single cell, although such a limited necrosis is rarely recognized. Clinically necrosis is usually not noted except when the area is sufficiently large to observe with the unaided eye.

All tissues of all animals are subject to necrosis, and it may occur upon a surface or in subsurface structures. Bursattae is a disease characterized by necrosis of the skin. Necrotic stomatitis, a disease in puppies, calves and pigs, is accompanied by necrosis of the buccal mucous membrane. Tuberculosis, glanders, actinomycosis, and caseous-lymph-adenitis are diseases in which there is surface or subsurface tissue necrosis.

Etiology.—Necrosis may be primary but it is more frequently secondary. Secondary necrosis is a sequel or result of some other pathologic process, as hemorrhage, oedema, thrombosis, anemia, hyperemia, inflammation, degeneration, infiltration and infection.

Primary necrosis is the result of; (1) obstructed nutrition; (2) chemic substances; (3) temperature variations.

Obstructed nutrition.—A tissue or part, from which nutrition is entirely obstructed, will die after all the available nutrients have been consumed.

Nutrition may be obstructed from a part by some mechanical means. An occasional result of mechanically obstructed nutrition is observed in dogs in which a rubber band has been placed upon a leg, an ear, the tongue, or the tail, the circulation being thus obstructed the part distal to the rubber band soon becomes necrotic. The improper adjustment of bandages, especially when used to support fractures, is frequently a cause of necrosis.

Tumors, cysts, abscesses and other pathologic enlargements may exert sufficient pressure to obstruct circulation and produce necrosis. Fractures and herniae may mechanically occlude blood vessels and result in necrosis. The seriousness of omental hernia or, in fact, any hernia, is due to the fact that the vessels supplying the hernied structures are occluded, resulting in necrosis and the absorption of the products of the necrotic tissue.

The plugging of a terminal vessel by a thrombus or an embolus (infarction) produces necrosis if collateral circulation is not established. Thrombo-embolic colic is a condition usually caused primarily by the larvae of the *Strongylus armatus* entering and producing a parietal thrombus in the anterior mesenteric artery, fragments of the thrombus become detached, pass down to and occlude the terminal mesenteric arteries, resulting in ischemia of the walls of the intestine, and if the circulation is not soon established the ischemic area becomes necrotic.

A part or organ separated from the remainder of the body undergoes necrosis sooner or later, the time depending upon the condition of the tissue and the temperature in which the separated portion is kept. Maceration and bruising produces necrosis to a varying degree, depending upon the extent of the injury.

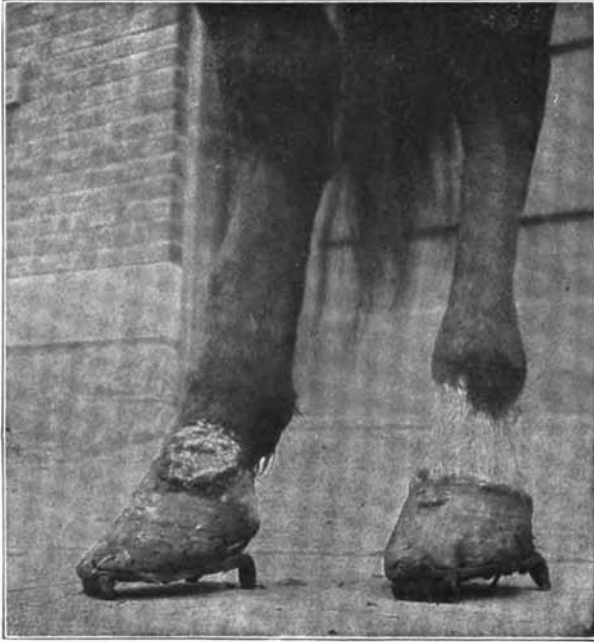

Fig. 131.—Photograph showing **Necrosis** above the foot of a horse.

Chemic substances.—Certain chemic substances as phenol, arsenic, mercury bichloride, strong solutions of the caustic alkalis and mineral acids, as well as the products of a large number of bacteria, are tissue destroyers. Phenol abstracts water from all cells to a sufficient extent to destroy their vitality, and it produces a rapid disintegration of red blood cells. Arsenious trioxide is frequently applied on tumors because of its erosive action. Bichloride of mercury combines with the cell albumins, forming albuminate of mercury, thus inhibiting the cell action, and when all of the cell albumin is combined the cell is destroyed. The caustic alkalis and mineral acids coagulate the cell albumin or abstract the cell water, thus destroying them. The *Bacillus necrophorus* produces chemic substances that cause coagulation of the cell protoplasm (coagulation necrosis).

De Schweinitz has described a chemic substance produced by the Tubercle bacillus, as necrotic acid, which is thought to produce necrosis in tubercular lesions. The toxin of the diphtheria bacillus produces focal necrosis in practically all tissue in an individual afflicted with diphtheria. The products of pyogenic bacteria produce marked tissue destruction.

Chemic substances produce necrosis by coagulation of the

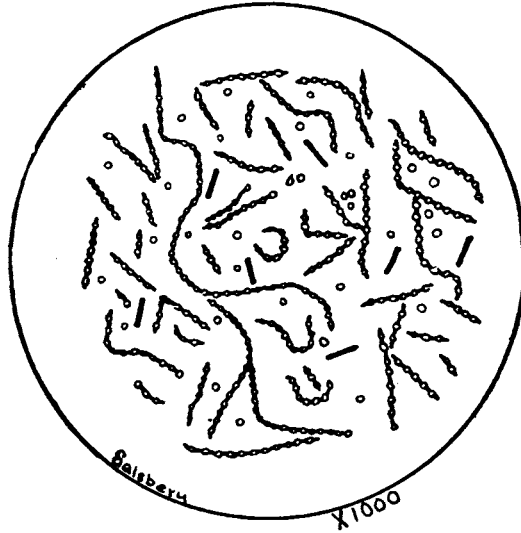


Fig. 132.—*Bacillus Necrophorus*—Pleomorphic form.

albumin by dehydration or by the formation of new cell compounds, thus inducing metabolic disturbance and cell death.

Temperature variations.—All active cells have a maximum and a minimum temperature. Thermic variations beyond these means are injurious and destructive if the variation is extensive. The high temperature causes coagulation of the cell protoplasm (cloudy swelling), which, if extensive, destroys the cells. Necrosis resulting from burning is of common occurrence. Low temperature is not as rapidly destructive as high temperature. Freezing produces necrosis of the tissues of warm blooded animals, probably because of cell disintegration induced by the formation of ice in the cells.

Types or Varieties of Necrosis.—Several factors may be used as the basis for the classification of necrosis.

Etiology.—According to the cause, necrosis may be: a. In-
anition necrosis, b. Thermic necrosis, c. Chemic necrosis.

Inanition necrosis is that type resulting from obstructed nutrition. As an example of this type may be mentioned the necrosis of the scrotum and its contents in rams induced by placing a rubber band moderately taut around its upper portion.



FIG. 133.—Photograph of the Ergot of Rye.

This is a method frequently resorted to in the castration of old rams. Bed sores observed in the superficial structures in animals afflicted with diseases that cause them to constantly assume the decubital position, are the result of obstructed nutrition induced by pressure upon the nutrient vessels or thrombic formation secondary to bruising.

Thermic necrosis results from exposure to extreme temperatures. Thus necrosis of cutaneous tissues is of common occurrence in animals as a result of conflagrations or undue exposure

to the solar heat rays or thermo-cautery. Necrosis induced by freezing is very common in calves, pigs, and chickens, in the temperate and frigid zones.

Chemic necrosis is represented by the extensive destruction of the buccal, oesophageal, gastric, and intestinal tissues induced by the ingestion of lye. Corrosive sublimate and arsenious trioxide destroy the mucous membrane and frequently the deeper tissues of the alimentary tract in animals poisoned with these agents.

Location.—Necrosis may be surface or subsurface. Surface



Fig. 134.—Ergot Poisoning in Cattle. Photograph by Dr. W. T. Spencer.
1. Sloughing above the feet. 2. Sloughing of the ends of the tails.

necrosis may be of the skin, mucous or serous membranes. Sub-surface necrosis may be of any tissue, muscle, bone, glandular, etc.

Nature or condition of the necrotic tissue.

1. Coagulation necrosis.—This type of necrosis is characterized by the coagulation of the necrotic tissue. It is the result of the presence of some enzym that produces the formation of fibrin or some allied substance. Coagulation necrosis is evident in the coagulation of blood and inflammatory exudates. The exudate in fibrinous inflammation (croupous and diphtheritic) usually becomes firmly coagulated. On the other hand, coagulation is rarely observed in collections of lymph, as in ascites, etc. The necrotic tissue in anemic infarcts, especially in the kidney, is sometimes coagulated.

2. Colliquation necrosis.—The condition resulting from solu-

tion of a substance or surface area of necrotic tissue is colliquation. Solution of the necrotic tissue is the result of enzymes that dissolve or digest the dead tissue. Suppurative processes (as abscess formation, etc.), are examples of this type of necrosis. Liquefaction of anemic infarcts, inflammatory exudates and thrombi, with or without the formation of cysts, is colliquation necrosis. In the brain of horses that have died of the so-called blind staggers areas are found containing liquefied nerve tissue.

3. Caseation necrosis.—When the fluid is absorbed from liquefied necrotic tissue, the remaining solids may become cheese-like, thus producing the condition known as caseation. Caseation may be primary, but it is more frequently secondary to liquefying necrosis. Caseous material is granular, soft or crumbly in consistency. Caseation is characteristic of the typical lesion of caseous-lymph-adenitis in sheep and goats. Liquefaction precedes caseation in this disease. Tubercular lesions, especially in the bovine, is characterized by caseation, although they later become calcified. Necrotic centers of a caseous nature are observed in the lesions of bursattae.

4. Mummifying necrosis (mummification, dry gangrene).—Necrotic tissues superficially located may become desiccated, thus producing the condition known as mummifying necrosis. This type of necrosis occurs upon a surface that is freely exposed to air and of tissues in which there is little moisture. The ear, tail and hoof lesions, characteristic of ergotism, are the most typical examples of mummifying necrosis. In ergotism, the lesions are produced by constriction of the arterioles. This in turn increases blood pressure, and, consequently, the work of the heart. This ultimately results in the diminution or complete absence of blood from the extremities, and the latter sooner or later become necrotic. The necrotic tissue, as ears, tails, etc., in animals affected with ergotism become mummified because blood is practically shut off from the affected parts and the contained moisture soon evaporates, for they are freely exposed to the air on two or more surfaces. Frozen tissues may become mummified. The umbilical cord in new born animals undergoes mummification.

5. Gangrene.—By the laity, the term "gangrene" is used to designate any type of necrosis, and by some medical men it is used to signify death of soft tissue en masse. Gangrene is that type of necrosis characterized by putrefaction of the necrotic tissue. Gangrene invariably occurs in tissues in which there is a good supply of moisture, as in a tissue affected with venous con-

gestion, and usually occurs upon a surface because infection is more likely to occur there. Parenchymatous mammitis of the bovine is frequently succeeded by necrosis and putrefaction of the necrotic tissue (gangrene). Gangrenous pneumonia is not uncommon and may be the result of embolic metastasis of organisms from septic metritis, etc., or it may be induced by medicaments introduced into the lung.

Miscellaneous.

1. Senile Necrosis.—This is a type of necrosis occurring in old age. It is not uncommon in old dogs and aged horses, and is usually the result of inelasticity of the arteries and an insufficient supply of nutrition.

2. Fatty Necrosis.—This is a condition characterized by the

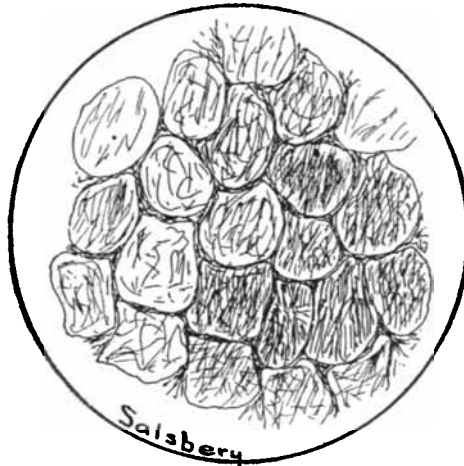


Fig. 135.—Multiple Fatty Necrosis.
Fat cells undergoing disintegration, because of Saponification.

conversion of fat into fatty acid and glycerine, that is, saponification of fat. The name fatty necrosis is a misnomer, as the condition is not necrosis. It should be called saponification of fat. In fact, a fully developed fat cell represents that amount of stored, available food, and there is in reality no vitality in the cell, and necrosis in dead tissue is not conceivable. Again, the real existing condition is saponification of the fat, not necrosis. The probable cause of fatty necrosis is resorption of steapsin induced by pancreatic disturbances, although steapsin may be absorbed from the intestine. Some four or five cases have been observed in the dog, several cases in the sheep, and one horse was examined that was affected with fatty necrosis. In each of the above cases

there was evidence of pancreatic lesions, as inflammation, hemorrhage and atrophy was noted in one case. Recently it has been suggested that this condition is caused by disturbances of the islands of Langerhan.

The areas affected are at first soft and spongy, but later become more or less calcareous as a result of combination of lime salts with the free fatty acid.

Fatty necrosis usually involves the omental fat, and especially that in close proximity to the pancreas, though all fatty tissue is subject to this condition.

In gross appearance the involved portions are dull, lusterless, opaque, slightly raised, usually circumscribed areas, of a yellowish white color. If the lesions are advanced, calcareous granules may be observed by palpation. In microscopic section the cells of the affected areas may contain needle-like crystals, or the cell substance may appear as a granular mass.

3. Focal necrosis.—In certain infective diseases it has been noted that small foci of the various parenchymatous tissues un-




Fig. 136.—A necrotic tubercle; lung. x250. Showing necrotic center surrounded by small round cells, epithelioid cells, and leucocytes.

dergo necrosis. In many instances, this occurs in the absence of any circulatory disturbance, indicating that the exciting cause, chemic substance, is carried by the blood and appears to have a selective action for certain tissue. This type of necrosis is common in diphtheria and typhoid fever in the human and in hog cholera, glanders, generalized tuberculosis and probably some other infective and chemically induced diseases of the lower animals.

The areas affected are frequently not sufficiently large to observe with the unaided eye. Microscopic sections show the cells in various stages of necrosis. The nucleus may be apparently normal or entirely disintegrated, the cell body may be granular or hyaline, it may be intact or appear fragmented. Leucocytic invasion of the necrotic area is of frequent occurrence, and may at first give the impression of an infected focus. Necrotic tissue in focal necrosis may be absorbed and the destroyed tissue regenerated; it may become liquefied, thus forming a cyst; it may become infected and be succeeded by abscess formation, or it may be substituted with scar tissue.

4. Jack-Sores.—This is a name applied to a very prevalent condition in jacks in which there is necrosis of the skin and subcutaneous tissue. Perhaps jack-sores should not be classed as a separate or distinct type of necrosis, but it is so common that it merits a special mention. The skin and subcutaneous structures of the legs, venter surface of the abdomen and thorax, and maxillary region are most frequently affected. The necrotic areas may be very extensive, in some instances involving the entire metatarsal or metacarpal region.

The etiology of "Jack-Sores" is not known, but no doubt it is the result of malnutrition and probably an irregular, indefinite lymphatic circulation is the primary cause.

Tissue Affected.—No tissue is exempt from necrosis. The tissue affected depends upon the cause, the animal and geographical location.

Disposition of Necrotic Tissue.—Necrotic tissue or products derived from it are more or less irritating and may produce an inflammation in the living tissue around the necrotic mass. The perinecrotic inflammation insures an increased number of leucocytes around and in the necrotic area. The necrotic tissue, leucocytes and other living cells may produce enzymes that will ultimately dissolve the necrotic tissue. There may be a contraction of the necrotic tissue and later it may separate from the surrounding normal tissue. The reaction of the adjacent living tissue may be limited and cause the production

around the necrotic area of a fibrous or osseous capsule, or even cause a fibrous formation throughout the entire necrotic mass. From the foregoing it is apparent that necrotic tissue may be disposed of as follows: 1. Absorption. 2. Exfoliation. 3. Encapsulation. 4. Sequestration.

Absorption.—The necrotic mass is more readily absorbed when it is in a liquid state (colliquation), although leucocytes, and various other cells may produce enzymes that are capable of dissolving coagulated necrotic tissue. Absorption of fluid necrotic tissue is in part accomplished by means of the lymphatic tissues, and in part by means of leucocytes that incorporate and convey fragments of necrotic cells to the various organs that dispose of waste materials. Necrotic infarcts are occasionally entirely absorbed.

Exfoliation.—Necrotic surface tissue is frequently disposed of by separation of the dead from the living tissue as a result of inflammation or contraction of the necrotic mass. The separated necrotic mass is the sphacelus. The process of separation and sloughing is exfoliation. Exfoliation is the usual disposition of necrotic extremities induced by freezing and by ergot poisoning.

Encapsulation.—The irritation produced by subsurface necrotic tissue may be insufficient to cause an acute inflammation, but it may stimulate fibrous hyperplasia. Thus a fibrous capsule or wall is built around the necrotic mass, i. e., it becomes encapsulated. In some instances the encapsulated necrotic tissue later becomes calcified, or it may become liquefied, the capsule retaining the liquid, thus a cyst is formed.

Fibroblasts may extend into the necrotic area and form fibrous tissue throughout the entire mass, thus there would be a mass of cicatrizing fibrous tissue permeating the necrotic mass.

Sequestration.—This is a term applied to the separation of subsurface necrotic tissue, more especially necrotic bone, from the surrounding healthy tissue. The separate necrotic portion is termed the sequestrum, and the process of its separation sequestration. An osseous sequestrum may be encapsulated, the capsule later becoming osseous, thus forming an involucrum.

Effects.—Necrosis is the condition resulting from tissue destruction. The effects of tissue destruction depend upon the variety of tissue, the extent and location of the condition, and the age and condition of the animal in which it occurs. If the tissue destroyed is capable of regeneration, or if it is limited in extent, and the animal is otherwise in good condition, the effects will be insignificant. If the tissue destroyed cannot be regener-

ated and is extensive, the animal will be deprived of that quantity of tissue and if the function of the destroyed tissue is of prime importance, the animal will die.

Necrosis is invariably associated with inflammation, which is especially active around the necrotic area, and the results of this inflammatory reaction must also be considered in estimating the sum total of the effects of necrosis.

DEATH.

DEFINITION.

ETIOLOGY.

Suspended heart action.

Respiratory arrest.

Suspended brain action.

SIGNS.

Post Mortem Staining.

Temperature change.

Muscular rigidity.

Decomposition.

TESTS.

Mirror.

Blister.

Incision.

Relaxation of sphincter muscles.

Death is the condition resulting from the permanent arrest of all functions. Death should not be confused with necrosis. The former refers to somatic death and the latter to the death of a part. It is difficult and in fact impossible to determine the exact time when life ceases in a body. The various body tissues do not all become lifeless when the individual as a whole dies. The length of time that vitality is retained in the tissues of a dead animal depends upon the variety of tissue, the age of the animal and the cause of death. The less highly organized, the tissue, the longer its vitality is retained. The tissue of young animals possess their vitality for a longer time than the same tissues of an aged animal. Death results from disturbance of certain vital centers and these tissues, as well as all others specifically acted upon by the agency that causes death, lose their vitality earlier than tissues not acted upon.

Death may be physiologic or pathologic.

Physiologic Death.

This is that type of death observed in old animals. During embryonic life the principal function of all tissue cells is reproduction. As the tissue becomes more matured, the reproductive property of its cells gradually diminishes and has practically disap-

peared in old age. Cell repair is complete in early life, but gradually diminishes as the animal becomes aged. The activity of cells and their life cycle is limited as is that of all active structures either animate or inanimate. Therefore, if new cells are not produced and the old cells are not repaired their energy or vital forces are finally exhausted and they degenerate and die. If large numbers of cells of all tissues die the animal involved is incapacitated and ultimately sufficient cells die to diminish the function of the vital organs to such an extent that there is collapse and somatic death.

Physiologic death is initiated by a gradual decline which may continue until the individual dies. Or after a long period of slow decline, death may be sudden as a result of a suddenly diminished function of a vital organ. Physiologic death is similar in a way to the collapse of the one horse chaise which, as the story runs, was used until it literally fell to pieces. Very few domestic animals die a physiologic death. Those animals whose flesh is used for food are butchered long before physiologic death would intervene, and those animals used as beasts of burden are usually destroyed when their earning capacity is monetarily less than the food they consume.

Pathologic Death.

Pathologic death signifies the ending of life prior to the time that the vital forces have been exhausted.

Etiology.—Pathologic death is that type caused by accident or disease process. Death primarily is the result of permanent suspension of heart action, respiration or brain functioning.

Suspended heart action may be caused by influences acting upon the cardiac nerve centers in the medulla or upon the heart musculature direct. The significance of suspended heart action is self evident. There being no blood circulating the tissue would soon consume all available nutriment and then succumb. Temporary arrest of heart action is called syncope.

Respiratory arrest is usually the result of nervous influences though clonic spasms of the respiratory muscles would produce a similar effect. The absence of respiration implies the absence of oxygen to oxidize the blood and the tissues and the absence of oxygen for a considerable length of time results in carbon-dioxide poisoning and death. Apnoea is a condition in which respiration is arrested.

Permanent arrest of all brain functioning even for a brief period results in cessation of all the principal functions and death.

Thus, suspended brain function results in arrest of heart action and respiration either of which results in somatic death. Coma is a term used to designate a condition in which all consciousness or recognition of environments is suspended but the control of vital functions is still maintained.

Signs of death.—The changes that occur in dead tissue are of considerable importance especially to inspectors of carcasses of animals, the flesh of which is intended for human consumption. The most important post mortem changes in tissues are as follows; post mortem staining (*livores mortis*); death stiffening (*rigor mortis*); and decomposition or putrefaction.

Post Mortem Staining.—The blood usually undergoes changes immediately after death. The disintegration of red blood cells allows of the liberation of hemoglobin which is deposited more or less extensively upon the inner lining of the blood vessels and heart and also filters through the vessels and stains the perivascular tissues. The length of time after death that post mortem staining becomes evident depends upon the cause of death. In fact the purplish staining along the cutaneous vessels evident in dead bodies may be evident in the living body of animals. Thus liberation of hemoglobin takes place during life in the blood of animals affected with septicemic diseases.

Temperature changes.—The carcasses of all dead animals assume the temperature of the environment sooner or later. The length of time necessary for the body heat to pass out of a dead body depends largely upon the cause of death. In some diseases, those in which tissue change is limited, the temperature is subnormal at the time of death and rapidly assumes the environmental temperature after death. In other diseases, those in which tissue changes are extensive, the temperature may vary from normal to considerably above normal at the time of death and may increase for several hours after death. Temperature changes may be extremely variable in a carcass. Also a remarkably low subnormal temperature has been observed in many living animals, especially those in a comatose state and yet the animals recover. The thermic variations should never be relied upon in determining whether or not life is extinct, at least not within 48 hours after the animal is supposed to be dead.

Rigor Mortis.—That the body of an animal becomes rigid after death is common knowledge to all observers. Rigor mortis represents a condition of the muscle fibre in which it becomes rigid as if in a tonic contraction. The length of time after death that rigor mortis appears and the length of time that it persists depends upon the condition of the animal at the time of death.

Thus muscular rigor appears usually in a few minutes after death and is of brief duration in animals, that have died as a result of a long continued exhaustive disease, as chronic tuberculosis. On the other hand rigor mortis may not become evident until 24 hours after death in animals that have been killed while in a perfect state of health and it may continue for from two to four days. In catalepsy, muscular rigidity is a characteristic symptom. Other conditions, however are sufficient to differentiate this from rigor mortis.

Decomposition or putrefaction is caused by the action of putrefying bacteria.

The decomposition of a tissue is sufficient evidence of the fact that it is lifeless. Decomposition or putrefaction is not easily detected in the early stages. The evolved odor is usually the accepted sign of decomposition and during some seasons of the year, decomposition may not become evident for several days after death. The carcasses of animals dead of septic infections usually decompose immediately after death, e. g. carcasses dead of anthrax, hog cholera, etc.

Tests.—Because of the uncertainty of the above signs especially, during the first 24 or 48 hours after death, certain tests are recommended to determine the presence or absence of life in a certain body. They, like the above signs, are not absolute.

The mirror test.—Respired air contains more or less water vapor. Respiration is not always perceptible. Water vapor is condensed upon a cold surface. The procedure of this test consists in holding a mirror over the nostril and if any air is expired the watery vapor from the expired air will be condensed and rendered visible upon the surface of a mirror. This test is not infallible for the respiratory functions may be so diminished that the moisture (watery vapor) of the expired air is insufficient for condensation upon the mirror.

Blister Test.—Blisters or vesicles can usually be produced by heat or chemic vesicants applied to the skin of a body in which life still exists. The formation of vesicles is not possible in dead tissue because the production of a blister represents the response of a living tissue to an irritant and only living tissues are capable of reacting. Vesicle productions varies in living animals and in some cases they are not produced.

Incision.—Because of the elasticity of living tissues, all incised wounds gap in the living body. Tissue elasticity disappears when the tissue dies, consequently incised wounds in dead tissues do not gap.

Certain post mortem changes are rather constant in the eye. These changes consist of a cloudiness of the lens and the aqueous humor, the condition gradually becoming more intense. The surface of the eye, i. e., the conjunctiva, becomes dry and scaly in appearance.

All sphincter muscles are usually relaxed at the time of death and remain so permanently.

CHAPTER X.

TUMORS.

(Neoplasms.)

DEFINITION.

FREQUENCY.

STRUCTURE.

Cells.

Intercellular.

Vessels.

Nerve tissue.

SIZE.

SHAPE.

COLOR.

CONSISTENCY.

NUMBER.

GROWTH.

EXTENSION.

NATURAL RESISTANCE.

RETROGRESSIVE CHANGES.

CLINICAL CONSIDERATION.

ETIOLOGY.

VARIETIES.

Occurrence.

Primary.

Secondary.

Recurrent.

Structure.

Histoid.

Organoid.

Teratoid.

Clinically.

Benign.

Malign.

Tissue.

Adult.

Epithelial and connective—Papilloma.

Connective.

Fibrous—Fibroma.

Mucous—Myxoma.

Cartilage—Chondroma.

Osseous—Osteoma.

Dentine—Odontoma.

Adipose—Lipoma.

Glia—Glioma.

Muscular.

Involuntary—Leiomyoma.

Voluntary—Rhabdomyoma.

Vascular.

Blood vessel—Hemangioma.

Lymph vessel—Lymphangioma.

Nervous.

Neuroma.

Embryonic.
Connective.
Sarcoma.
Endothelioma.
Hypernephroma.
Placentoma.
Epithelial.
Carcinoma.
Epithelioma.
Adenoma.
Hypernephroma.
Placentoma.
Adult and Embryonic.
Any and all tissues.
Teratoma.

The term "tumor" was formerly used to indicate any swelling in animal tissues. They, more than any other pathologic entity, have been studied and investigated by scientists, and yet little is known of their pathology. With the present limited knowledge it is impossible by definition to clearly differentiate them from some other pathologic conditions. They have been defined as new growths of tissue developing independently in any tissue of the animal body and atypical in structure and function. Also they are non-inflammatory growths of new tissue, persistent, independent of the surrounding structures, atypical in structure and function. A more concise idea can be formulated by thinking of them as parasites, that is, they are new growths of tissue that develop in or upon the animal body at the expense of the animal, and are subject to the same pathologic conditions that the normal tissues are, as degeneration, necrosis, etc.

Frequency.—Tumors are of frequent occurrence. They are more common in dogs particularly aged ones than in other animals. Of 127 animals presented in the daily clinic at the Kansas City Veterinary college during one college session, 12 were affected with tumors.

The frequency of tumors in animals treated in the Berlin, Dresden, and Munich veterinary colleges for an average period of seven years is shown by the following:

Of 86,613 diseased horses, 1,113 suffered from tumors, or 1.3 per cent.
 Of 85,537 diseased dogs, 4,020 suffered from tumors, or 4.7 per cent.
 Of 4,972 diseased cattle, 102 suffered from tumors, or 2 per cent.

Structure.—Tumors are composed of cells and usually, an intercellular substance. The cells may be similar to normal embryonic cells or to adult cells. The embryonic tumor cells differ from normal embryonic cells in that the former have no tendency to become matured while the latter have. The accompanying cut shows a section of a sarcoma composed of embry-

onic cells that are similar to embryonic connective-tissue cells. Papillomata are composed of cells that are very similar, if not identical, to adult epithelial cells, and are supported by an adult connective-tissue framework.

Tumor cells are very similar to the cells of normal animal tissues. They have practically the same structure and require the same kind of nutriment. However, they do differ from the normal tissue cells in their power of growth and reproduction.

Tumor cells are usually more susceptible to changed environments than normal tissue cells. The nuclei of the cells of a rapidly growing tumor are usually larger probably because of increased functional activity.

The intercellular substance of tumors is as variable as the intercellular substance of normal tissues. Tumors having a mesodermal origin usually have an intercellular substance closely resembling that of normal connective tissue and hence may be mucus, fibrous, cartilaginous, or osseous. Tumors of an ectodermal or an entodermal origin may appropriate the pre-existing tissue framework for their stroma. Some tumors, like some normal tissues, are practically devoid of intercellular substance. Again, in some tumors the blood-vessels are the only intercellular substance. Anatomically the intercellular substance or stroma is an integral part of a tumor and its function corresponds to the function of intercellular substance of normal tissue. The cells and intercellular substance of tumors may be so arranged that the resulting structure approximates that of normal tissue (histoid tumors), but is never identical to a normal tissue. The different parts of a tumor may be assembled so that the resulting organization appears as an atypical gland or organ (organoid tumor), or tumors may be composed of structures derived from all three germ layers grouped indiscriminately but having some resemblance to an embryo (teratoid tumors.)

Like normal tissue, tumors are usually nourished, by blood and lymph. The blood and lymph vessels may be structurally the same as normal vessels, or they may be composed entirely of tumor cells. The vessels have their origin from pre-existing vessels in the tissue from which the tumors are developed. They may be telangiectatic, cavernous, or plexiform, and their course is usually along the tumor stroma. Blood and lymph may also permeate the tumor through intercellular spaces, frequently resulting in hemorrhage or lymphorrhage. Some tumors have no blood or lymph supply, their nourishment probably being derived from consumption of normal tissue.

Nerve cells and axones have been demonstrated in some

tumors. They are, in some cases at least, a result of peripheral extension and development of the tumor tissue around normal nerve tissue, thus entangling it in the tumor. It is an open question whether nerve tissue exists in tumors except in those derived from normal nerve tissue or those in which normal nerve tissue is entangled.

Leucocytes are common in tumors. Lymphocytes and polymorphonuclear leucocytes have been demonstrated in the blood and lymph channels, perivascular and intercellular spaces, and within the tumor cells. The cells and the manner in which they are assembled, the structure and arrangement of the intercellular substance, and the presence of the blood and lymph vessels indicate a common origin of tumor tissue and normal tissue.




Fig. 137.—Section of Sarcoma, showing sarcomatous cells and blood vessels.

Size.—Tumors are quite variable in size. They may become so large that they mechanically destroy life. An abdominal subserous lipoma, about the size of a wash-tub and weighing thirty-eight kilograms, (83½ lbs.) was observed in an ox. A six-kilogram (13 ⅓ lbs.) fibroma was removed from the inferior cervical region of an eighteen kilogram (40 lbs.) dog. A twelve

kilogram (26 $\frac{2}{5}$ lbs.) chondroma was obtained from the sternum of a fifty kilogram (110 lbs.) sheep. All of the above tumors were of sufficient size to mechanically inconvenience the animals afflicted, and in one case resulted fatally. From the enormously large tumors there are all gradations to those microscopic in size, miliary tumors. The size of tumors is determined to some extent by the amount of nourishment supplied, the kind of tissue of which they are composed, and their location.

Shape.—The form of tumors is largely determined by the location and the kind of tissue in which they occur. They may be spherical, ovoid, ellipsoid, nodular, miliary, tubercular fungoid, polypoid, tabular, elongated cylindrical etc. Where there is no resistance or only a slight resistance there is a tendency to sphericity. In outline they may be regular or irregular, smooth, nodular or even granular and in some cases the exact outline cannot be determined. Large tumors that in shape approach a sphere are designated as spherical, ovoid, ellipsoid, etc. Those that vary in size from a pigeon egg to a small pea are spoken of as nodular tumors. Miliary tumors are small spherical growths varying from a small pea to those microscopic in size. Spherical or oval tumors causing an elevation in the tissue in which they grow are known as tubercular tumors. Fungoid or projecting tumors are those that develop from the surface or sub-surface tissue, being attached to the normal tissue by a wide base. Polypoid tumors or polypi have the same origin and project as fungoid tumors, but are attached by means of a small pedicle. Tabular tumors are flat and usually develop beneath the surface and especially beneath fasciae, tendons or ligaments.

Color.—The color of tumors is dependent upon; first, the kind of tissue composing them; second, pigmentation; third, degeneration; and fourth, the amount of blood they contain. A rhabdomyoma is more intensely colored than a fibroma, provided that the blood supply is the same in both, because of the hemoglobin in the muscular tissue. Melanomata and chloromata are so classified because of the deposition of pigment in them. Tumors, like normal tissues, become changed in color as a result of the various degenerations. Those having a limited blood supply are pale in color, while those having a large blood supply are highly colored. Hemorrhages may result in a deposition of hemoglobin or some of its derivatives, thus giving the tumor a mottled appearance. Mottling may also result from an unequal blood supply.

Consistency.—Some tumors are soft and spongy, jelly-like, and from this type there are all variations up to those that are hard and resistant, bone-like. Their consistency is determined largely by the kind of tissue composing them and the secondary changes (degenerations) that affect them. Myxomata being largely composed of mucus are soft, fibromata are more resistant and osteomata are bone-like. Chondromata are usually quite firm and resistant, but they may undergo mucoid degeneration and become soft and spongy. Colloid degeneration is rather common in carcinomata, rendering them glue-like in consistency. Occasionally a tumor becomes calcified as a result of calcareous infiltration.

Number.—Tumors may be single, that is, a single one only occurring in the animal body. Single tumors are usually benign although they may be malign. An animal may be afflicted with a great many tumors at the same time (multiple tumors). Tumors may become multiple by metastasis. Tumors resulting from metastasis are designated secondary and the original tumor primary. Multiple tumors may be malign, as sarcomata, carcinomata, etc., or they may be benign, as multiple fibromata. Tumors that recur after they have been removed are designated recurrent tumors.

Growth.—The growth of tumors is the result of the inherent proliferative property of the tumor cells. Some tumors grow like an onion, there being a multiplication and accumulation of the central or internal cells, resulting in an interstitial expansion and an increase in the size of the tumor. Practically all benign tumors grow by interstitial expansion. Malign tumors grow by multiplication of the peripheral cells and their infiltration as well as by interstitial expansion. The extent of growth of all tumors is proportional to the amount of nourishment they receive and to the adjacent tissue resistance. The relative amount of nourishment to tumor tissue and to normal tissue in the same body may be very unequal. Thus a tumor frequently receives an excessive amount of nourishment and grows rapidly, while the normal tissue in the same body is deprived of nourishment, resulting in its atrophy or degeneration and emaciation. As a rule, the rate of growth is indefinite. Malign tumors grow more rapidly than benign. A tumor that is growing rapidly may cease growth, diminish in size, grow again and diminish again. Diminution in size may be succeeded by absorption and disappearance.

Extension.—The manner of extension of the various tumors depends upon the migratory properties of the tumor cells and the relation and structure of the blood and lymph vessels. Tum-

ors composed of embryonic cells extend more rapidly than those composed of adult cells because embryonic cells are plastic and are to some extent capable of amoeboid movement. Adult cells are fixed in their form and none of them, excepting leucocytes and endothelial cells are migratory. The nutrient vessels of tumors are sometimes formed of tumor cells that are easily detachable, a structural peculiarity predisposing to tumor metastasis.

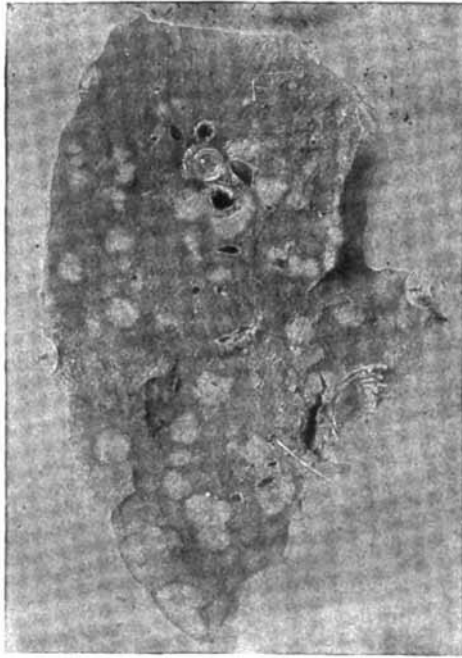

Fig. 138.—Photograph of a section of a horse's lung, showing **Metastatic Sarcoma**.

Benign tumors usually extend only by growth in continuity or contiguity. In fact, practically all tumors composed of adult tissues extend by pushing aside the normal tissue. Malign tumors are extended by blood, as sarcoma; by lymph, as carcinoma; or they pass from one point to another through natural channels as the digestive and respiratory tracts.

Summary.—Tumors may be extended (1) by growth in continuity, (2) by growth in contiguity, (3) by blood, (4) by lymph, (5) by natural channels other than the blood and lymph vessels.

Natural Resistance.—Normal tissues have a natural resistance to any injurious influence as the formation of tumors, in-

flammation, degeneration, etc. Tissue resistance to the development of neoplasms varies in different animals, in the same animal at different times, and possibly also in the different tissues of the same animal. The resistance of the surrounding tissue is made evident in some cases by the formation of a fibrous wall or capsule that limits and separates the tumor and the normal tissue. Degeneration and necrosis may also be interpreted to be a result of opposed action by the invaded tissue.

Retrogressive Changes.—Tumors are subject to the same degenerative processes that normal tissues are. Hemorrhages, necrosis and degenerations are frequent in tumors because of the imperfectly formed and irregular distribution of the supplying vessels. The results of hemorrhage into tumors depend upon the amount of extravasated blood and the secondary changes therein. A tumor the size of a cocoanut would likely become necrotic if a vessel ruptured and a half a liter of blood escaped into the tumor tissue. A small quantity of extravasate when infected with putrefactive microorganisms as a rule results in necrosis of the tumor tissue. Necrosis is a sequel of obstructed circulation or results from the solvent action of metabolic products. Thus, necrosis may be the result of thrombosis or embolism. Thrombic formation is especially prevalent because of the irregularities of the lining of the tumor vessels. Emboli are common, as they are frequently detached tumor cells. Circulation may also be interfered with by pressure of the tumor tissues, thus obstructing the efferent or afferent blood vessels. Some metabolic products of tumors constantly dissolve the surface cells, resulting in ulceration, a common necrotic condition observed in tumors. Tumors may be invaded with pyogenic bacteria, resulting in suppuration.

Of the degenerations, mucoid and colloid are the most common. Fatty degeneration and calcareous infiltration occur less frequently. Mucoid degeneration affects connective tissue and epithelial tissue tumors, occurring more frequently in the former. Colloid degeneration is found in epithelial tissue tumors.

A four-kilogram (9-lb.) renal hypernephroma undergoing colloid degeneration was obtained on post-mortem examination of a three-year-old steer. Fatty degeneration usually succeeds necrosis in tumor tissue. Calcification of tumors is quite common. Pigmentation is more common in tumors than in normal tissue. Melanomata are tumors containing melanin that has been deposited in the tumor cells. Chloromata are tumors containing a green pigment. Hemoglobin, hematoidin and hemo-

siderin are frequently found in tumors after hemorrhage into the tumor tissue.

Clinical Consideration.—Tumors are benign or malign. Benign tumors are usually encapsulated, i. e., they grow only by interstitial expansion; are composed of adult or matured tissue; have no tendency to recur when removed, and have only a mechanical effect upon the body in which they occur. Malign tumors are usually not encapsulated; they grow by peripheral infiltration; are usually composed of embryonic tissue; frequently recur when removed, and have a tendency to kill by absorption of the metabolic products which are deleterious to the body. Malign tumors of domestic animals are not as fatal as they are in the human. Many horses affected with sarcomata have been permanently relieved by operation.

Etiology.—There are some predisposing factors as heredity and breed peculiarities that are frequently involved in the development of tumors. Cadiot refers to a family of dogs in which the females were affected with carcinomata of the mammae for




Fig. 139.—Photograph of a horse affected with an ocular Epithelioma.
This was a sequel of a wire cut

two successive generations. Hereford cattle are more frequently affected with ocular tumors than any other breed. Injuries in which there is a destruction of the tissue surfaces predisposes to tumor formation, and, in many instances, in the human, sub-surface wounds are a causative factor in the production of epithelial embryonic tumors. A few cases of epitheliomata have been studied in the horse and ox that were secondary to injuries.

The exciting causes of tumor formation have not been definitely determined, and this accounts for their undetermined characteristics. Many theories have been advanced. Cohnheim advanced the idea that tumors were developed from misplaced embryonic cells (cell rests). This theory has received the support of many pathologists. It is in accord with the general biologic law that every cell produces a cell like itself or "like begets like." The supporters of this theory have not proved it, but the opponents have not disproved it. All biologists recognize the complexity of embryonic development and are aware of the possibility of cells becoming entangled or misplaced during the formation period. Experiments have demonstrated the possibility of successfully transplanting tissue, both embryonic and adult, into a foreign location in the body. Transplanted embryonic tissue, however, does not remain as such, but soon becomes mature tissue, whereas malignant tumor cells have no tendency to become matured. Transplanted tissue cells do not infiltrate the surrounding tissue nor form metastases, but remain as distinct islands of cells.

The parasitic theory has been supported by a large number of scientists. No doubt malignant tumors resemble infectious diseases in that they extend by metastasis and produce similar effects. However, the uncertain transmission of tumors from one animal to another is certainly antagonistic to the parasitic theory.

Bashford, superintendent of the Imperial Cancer Research Fund, London, England, successfully transplanted 66 per cent of sporadic tumors. On the other hand, Ehrlich has successfully transplanted only about 14 per cent of sporadic tumors. No one has produced a satisfactory proof of the isolation of any causative parasite. By some authorities bacteria were thought to be the active agent in tumor production, and by others protozoa were claimed as the causative factor, and, more recently, many radical observers have proclaimed that yeast were the cause. Some have even claimed that the tumor cells are parasites.

Chemic disturbances, particularly changed chemic reaction in a tissue, is responsible for tumor formation according to some.

An alkaline secretion at points where exposure and irritation occurs produces carcinomata (Hertzler). Following this thought an acid reaction in a normally alkaline tissue would tend to produce sarcomatous tissue.

The specific causative factor of tumor formation is not known, but it is something that excessively stimulates the reproductive power of cells. In fact, all other functions practically cease, the entire cell energy being expended in reproduction. That is, tumors are the result of a disturbance in the cell metabolism in which reproduction is far in excess of the physiologic limit and is exercised at the expense of all other functions.

Varieties.—There is no satisfactory method of classifying tumors. Some authors have attempted methods of classifying, but until more is known concerning them a classification is unwise. The following is an attempt at grouping them, but is in no way complete. They may be grouped as to:

OCCURRENCE.

- Primary*—The original or first tumor.
- Secondary*—Metastatic tumor.
- Recurrent*—A newly developed tumor at the point from which one has been recently removed.

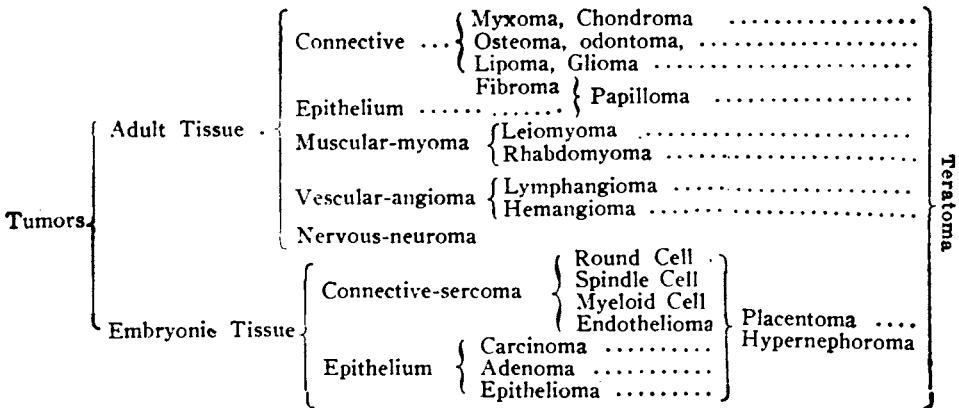
STRUCTURE.

- Histoid*—Simple tissue tumor.
- Organoid*—Organ-like tumor.
- Teratoid*—Mixture of various tissues resulting in a structure resembling an embryo.

CLINICALLY.

- Benign*—No tendency to kill.
- Malign*—Having a tendency to kill.

The following scheme shows the general structure and relation of the various tumors:



FIBROMA.

Fibromata are tumors composed of adult fibrous connective tissue. They occur in all animals. The skin and subcutaneous areolar tissue is their most frequent location, but no tissue is exempt. They are frequently found in the region of the sternum of the horse and ox, in the ovary and uterus of the cow, and in the perineal and elbow regions of the dog. In the skin and subcutaneous tissue they usually appear as loose, circumscribed, nodular growths. Some fibromata have no well defined border or line of demarcation but are apparently diffused through the tissue. This type, however, is somewhat rare, and possibly they are not fibromata. They may become so large that their pressure produces atrophy, degeneration or necrosis of the skin covering them, or the surface epithelium may produce sufficient new tissue to compensate for the increased surface. These tumors are usually single, that is, only one tumor occurring in the individual; but they may be multiple. Multiple fibromatosis is occasionally observed in the subcutaneous tissue of horses. They are variable in size, being so small in many instances that they are not observed in an ordinary examination. A fibroma may be so large that the diagnostician would mistake it for a malignant tumor, a hernia, cold abscess, etc. Their shape is as variable as their size. They may be oval, tabular, tubercular, nodular, and, in fact, they may have any conceivable shape and contour.

If the skin or covering tissue is incised or dissected away the tumor is usually found to be surrounded by a fibrous capsule or, in rare instances, it may blend imperceptibly with the surrounding normal tissue. They are not difficult to remove in their entirety because of their encapsulation. When they are excised their blood supply is found to be disproportionate to their size. With the small or limited blood supply there is a tendency to a slow growth and degeneration and necrosis. With an excessive blood supply there may be rapid growth and perhaps frequent hemorrhages into the tumor tissue. If the excised tumor is sectioned and the cut surface examined with the unaided eye, it appears to be composed of compact bundles of fibrous connective tissue atypically arranged (hard fibroma) or of loosely arranged bands of fibrous connective tissue inclosing areolar spaces (soft fibroma). In color the section appears pearly white with grayish-white, yellowish-white or dull pink areas, depending upon the compactness of the tissue, whether the fibre bundles are cut longitudinally or transversely, and the amount of blood contained. A fibroma is firm, dense and resistant, and when cut

into there may be a creaking sound similar to that produced in cutting a tendon. They have little or no tendency to peripheral infiltration but grow by central or interstitial expansion, mechanically pushing the contacting tissue aside.

If the tumor has degenerated or become necrotic quite a different picture than the above will be seen. It may be a mass of mucus as a result of mucoïd degeneration. It may contain necrotic areas or the entire tumor may undergo necrosis, the necrotic tissue becoming liquified, coagulated, caseated or calcified. Hemorrhage into the tumor tissue may give it a mottled appearance. The hemorrhagic spots may be red, yellowish-red or greenish-red, depending upon the changes in the hemoglobin.

Microscopically, the tumor tissue appears as white fibrous connective tissue, being composed of cells and a white fibrous intercellular substance.

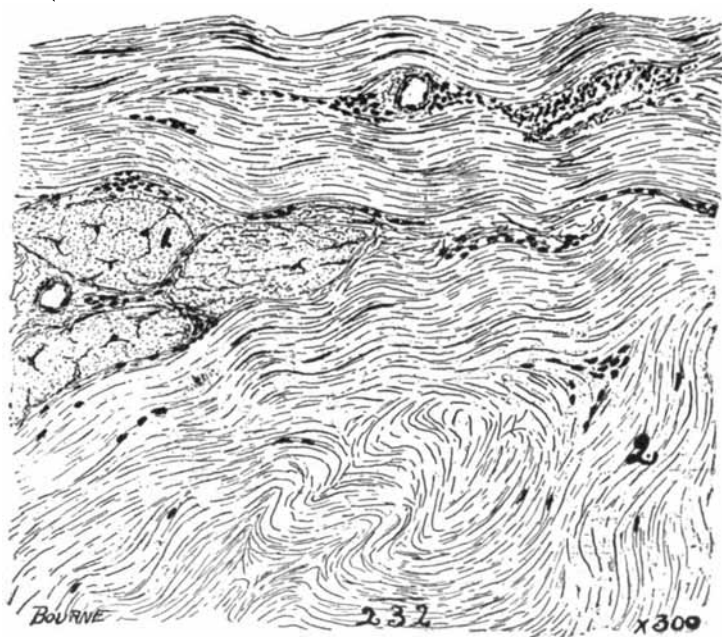


Fig. 140.—Section of a hard Fibroma showing: 1. Transverse section of bundles of Fibres; 2. Longitudinal section of bundles.

The cells are usually few in number, are flat and have a flat, oval nucleus. Cells are more prevalent in the rapidly growing tumors. The arrangement of the fibres varies and is the determining factor of the denseness of the tumor.

A hard fibroma is made up of bundles of fibres extending in

various directions and occupying practically the entire space, there being no interfunicular spaces. The bundles are compact masses of parallel, wavy fibres, with here and there a cell. The fibres are of two varieties, viz.: glia fibres and collagen fibres. Glia fibres are found along the surface of the cell and are parallel to its long axis. They are straight or slightly curved and probably extend from one cell to another. Collagen fibres are outside but lie close to the cell and appear slightly wavy. Collagen fibres predominate in fibromata. Blood vessels are few in number and may be absent.

A soft fibroma is composed of small bundles or bands of fibrous tissue loosely arranged. Cells and blood vessels are more numerous than in hard fibromata. The general appearance of a loose fibroma magnified one hundred diameters is very similar



Fig 141.—Soft Fibroma, showing wavy loosely arranged fibres.

to areolar tissue, except that in the former yellow elastic tissue is absent, while in the latter it is present. All variations in the compactness of the fibrous tissue is found from the soft to the hard fibroma. In fact some sections indicate that a soft fibroma becomes a hard fibroma by an increase in the intercellular fibres.

Clinically, fibromata are innocent or benign tumors. Their rate of growth is relatively slow. They may cause a fatal termination by mechanically obstructing the lumen of a hollow organ, as the intestine, by pressure upon vital organs, as the brain, or they may become so large that the affected animal is unable to move about in search of its food. Thus Kitt mentions a fibroma

that weighed 178 kilograms (391 $\frac{2}{3}$ lbs.) They do not extend by metastasis, neither do they recur when removed.

Fibromata can usually be differentiated from inflammatory new growths by the history of the case, fibromata having no defined cause and inflammatory new growths resulting from irritation. Microscopically, inflammatory new growths contain mitotic plasma cells and fixed connective tissue cells, while mitosis is rarely observed in fibromata. There is also an extensive blood supply in inflammatory growths, but a limited supply in fibromatous tissue. Actinomycotic and botryomycotic tissues are recognized by the presence of the causative fungi. Spindle-cell sarcomata may be confounded with fibromata and are sometimes difficult to differentiate. Sarcoma cells usually contain more protoplasm than fibroma cells, and this may be used as a basis for differentiation. By a gross examination a leiomyoma may be mistaken for a fibroma, but the microscopic appearance of the nuclei is characteristic. The nuclei of fibroma cells are oval while those of leiomyoma cells are rod-shaped. If the fibroma contains degenerated or necrotic centers the differentiation may be more difficult in gross section but microscopic examination of the unchanged tumor tissue will be sufficient. When the entire tumor has degenerated or become necrotic diagnosis may be impossible. Fibromatous tissue may be found in other tumors or fibromata may become contaminated by permeation or infiltration of other tumor tissue as mucoid, sarcomatous, etc., resulting in a fibro-myxoma, fibro-sarcoma, etc. The first portion of the compound word denoting that the mixed tumor contains more of that tumor tissue. Thus a fibro-myxoma is a tumor composed of fibroma tissue (fibrous connective) and myxoma tissue (mucoid connective), the former predominating. Mixed tumors will be discussed after consideration of the simple tumors.

A keloid is a dense overgrowth of white fibrous connective tissues in a cicatrix. These growths are quite common in the negro, especially at the point of an injury, as a razor cut or ear puncture for an ear-ring, etc. Because of their frequency and extent they have been considered as tumors by some authors. They are not true tumors but rather an inflammatory new growth resulting from improper cicatrization in wounds. They are not common in the lower animals.

MYXOMA.

Myxomata are tumors composed of mucoid connective tissue. These tumors may be a subvariety of fibroma. Purely myxomatous tumors are not very common, occurring more frequently in combination with other tumor tissue. They are usually found in connective tissue, but in no special location. They have been found in the heart, along nerve trunks, in the nostril, and a case has been reported of a pure myxoma involving the entire orbital structures in a horse. These tumors are usually about the size of a hen's egg, rarely becoming very large, probably because of their destruction by degeneration. They are invariably single. They appear as semi-solid masses, surrounded by fibrous capsules and are usually dirty-white or gray in color. After they are removed and an incision made into them a mucus or gelatinous, ropy fluid escapes. The cut section appears as a glassy, semi-transparent, semi-solid mass and is very similar to Wharton's jelly. The escaped fluid will be found by chemical test to contain considerable mucin. Their blood supply is usually very meager, in fact some authors regard myxomata as a mucoid degeneration because of their limited blood supply.

Microscopically, a myxoma is composed of stellate cells, in

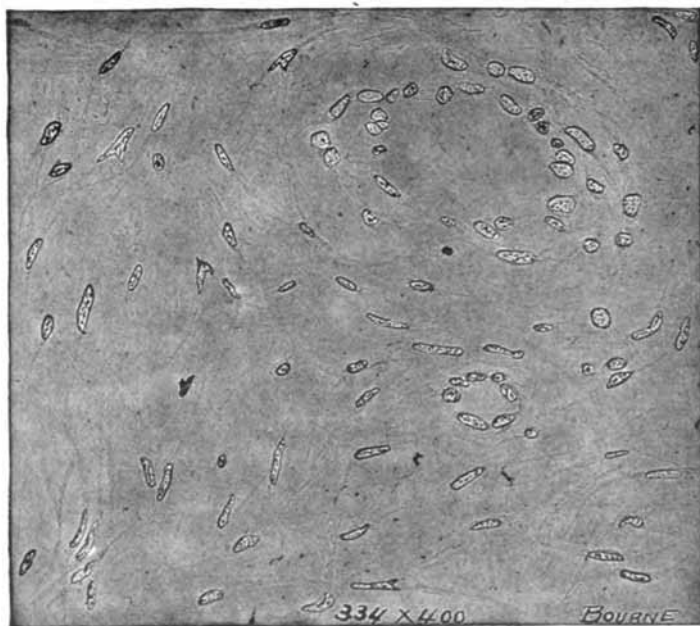

Fig. 142.—Section of Myxoma from the orbital fossa of a horse, showing stellate cells.

which the cell processes are apparently continuous with the processes of adjacent cells. Myxoma cells have an oval nucleus and the spaces between the cells and cell processes are filled with mucus, which appears as a stringy, gray substance that stains red with eosin. Myxomatous cells produce both kinds of fibres, i. e., glia and collagen fibres. The collagen fibres are more or less separated from each other by a varying quantity of fluid containing mucin. Myxomata are prone to degeneration, resulting in the formation of a cyst, or the fibrous capsule may become eroded, allowing the degenerated contents to escape into the surrounding tissue or upon a surface. In the latter case the degenerated contents is usually absorbed. Cicatricial tissue is usually produced in the cavity or space occupied by the myxoma. Sub-surface, myxomatous, degenerated areas may become infected, resulting in abscess formation.

Clinically, myxomata are benign tumors. They grow slowly by interstitial expansion, do not recur when removed, and extend only by continuity or contiguity.

These tumors are differentiated from mucoid degeneration, as the latter contains no stellate cells, and there are usually some of the cells present in mucoid degeneration that are normally present in that area. Clinically, it may at times be difficult to distinguish between mucus retention cysts and myxoma, but by the exploring needle the contents of the cyst may be evacuated and thus the nature of the mass will be determined.

CHONDROMA

A chondroma is a cartilaginous tumor. They occur in cattle, sheep, dogs, horses and fowls. They are found most frequently in the location in which cartilage is normally found. The sternum seems to be a favorite location for their development, probably because of the frequent injuries of the sternal cartilage due to the fracture of ribs and other injuries. They not infrequently occur in other bones, possibly developing from islands of cartilage that have not ossified, or from marrow or periosteum. They also occur in glandular tissue as the thyroid, parotid, ovary and testicle, and a few cases of chondromata of the lung have been reported.

These tumors appear as hard, nodular, well-defined growths, unless they are undergoing degeneration. In this case they may be of the nature of cysts, or if their capsule is ruptured, they may be soft, spongy, diffuse masses. They are variable in size. A chondroma weighing 12 kilograms (26 1/5 lbs.) was obtained

from the sternum of a sheep killed in a Kansas City abattoir. Another about the size of a pigeon's egg and attached to the sternum of a small hen was found by a city meat inspector.

Their shape is very irregular, but they are most frequently oval. As a rule they have a regular surface, though they may be lobulated. They are usually separated from the surrounding tissue by a fibrous capsule, but they may be firmly adherent to the adjacent tissue. In cutting, the tumor gives a resistance similar to cartilage and they may be gritty because of calcification or ossification. The ablated tumor is bluish-white if it is a pure chondroma. Degenerated areas will vary in color according to the kind and degree of the degeneration. Necrotic centres appear dull gray or yellowish-white and white if calcified. If the tumor is mixed the color will vary according to the contaminating tumor tissue.

Chondromatous tissue is composed of cartilage cells and an intercellular substance. The cells are irregular in size and shape and the number found in each lacuna is more variable than that in normal cartilage. The size, shape and arrangement of cells in different areas in the same tumor is variable. The cells are frequently degenerated, the nucleus fragmented and the cell membrane ruptured, allowing the cells to fuse as a homogeneous

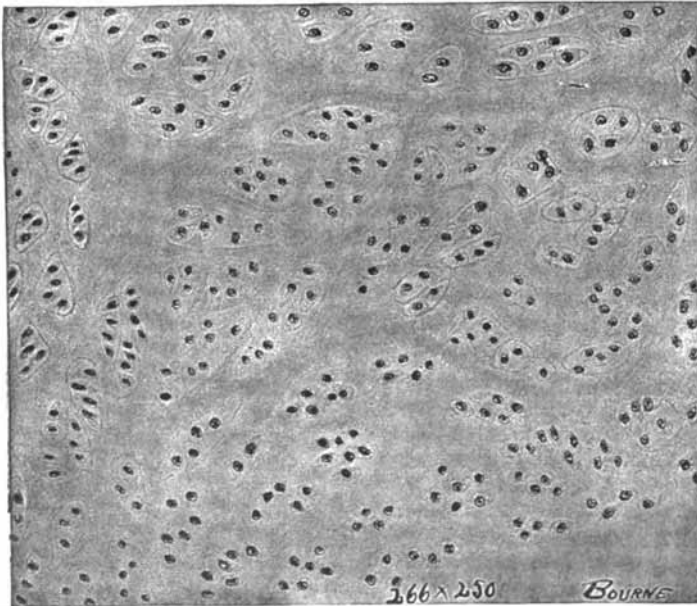


Fig. 143.—Section of Chondroma from sternum of a sheep, showing lacunae with included cartilage cells.

mass. The lacunae are not so distinct as those in normal cartilage, and their capsule may be absent. The intercellular substance is usually homogeneous, as in normal hyaline cartilage, or it may be fibrous, as in normal fibro-cartilage or elastic cartilage. The intercellular substance becomes fibrous towards the margin of the growth and finally forms a perichondrium. The cells may be arranged in rows near the perichondrium, but they are more likely to be irregularly distributed. The microscopic appearance of a degenerating, necrotic or mixed chondroma depends upon the kind and extent of the condition existing.

Clinically, chondromata are usually benign, but they may become malignant because of their extent. Some surgeons have recorded cases of metastatic chondromata. These tumors are frequently lobulated and may be multiple. They have little tendency to recur when removed.

LIPOMA.

Lipomata are tumors composed of adipose tissue with a connective tissue framework supporting the vascular supply. They occur quite commonly in the horse, ox, and dog, but none of the domestic animals are exempt. They usually develop where adipose tissue normally exists, as the subcutaneous tissue, submucosa and subserosa, omentum, etc. They may also occur in tissue that contains no fat, as the liver, kidney and even the brain. They occur most frequently in the subcutaneous tissue in the horse; in the intestinal and omental subserosa of the ox and hog; in the subcutaneous and conjunctival submucosa in the dog, and in the uterine submucosa of the sheep and the cow.

Lipomata are usually circumscribed, but they may be diffuse. The accompanying cut is from a photograph of a two-year-old colt in which there is shown a diffuse subcutaneous lipoma of the left hind leg. These tumors may become enormous in size in the horse and ox, some cases having been reported of lipomata as large as a wash-tub and weighing 30 to 70 kilograms (66 to 154 lbs.). In consistency, these tumors may be firm and dense or soft and flabby. They are usually surrounded by a fibrous capsule and in section those from the peritoneum and omentum are yellowish or white in color. Peritoneal, omental, submucous and subcutaneous lipomata have a smooth surface; intestinal lipomata are usually lobulated. Bands of connective tissue may divide the tumors into lobes or lobules or the connective tissue may be diffuse throughout the entire structure. In cutting a lipoma the resistance varies according to the quantity of fibrous connective tissue it contains. If osmic acid is applied to the free

surface of the gross specimen it stains the adipose areas black but has no effect upon other tissue. Occasionally groups of adipose cells become necrotic and calcify, thus forming gritty areas. Complete necrosis with sloughing or calcification is not rare in the larger lipomata.

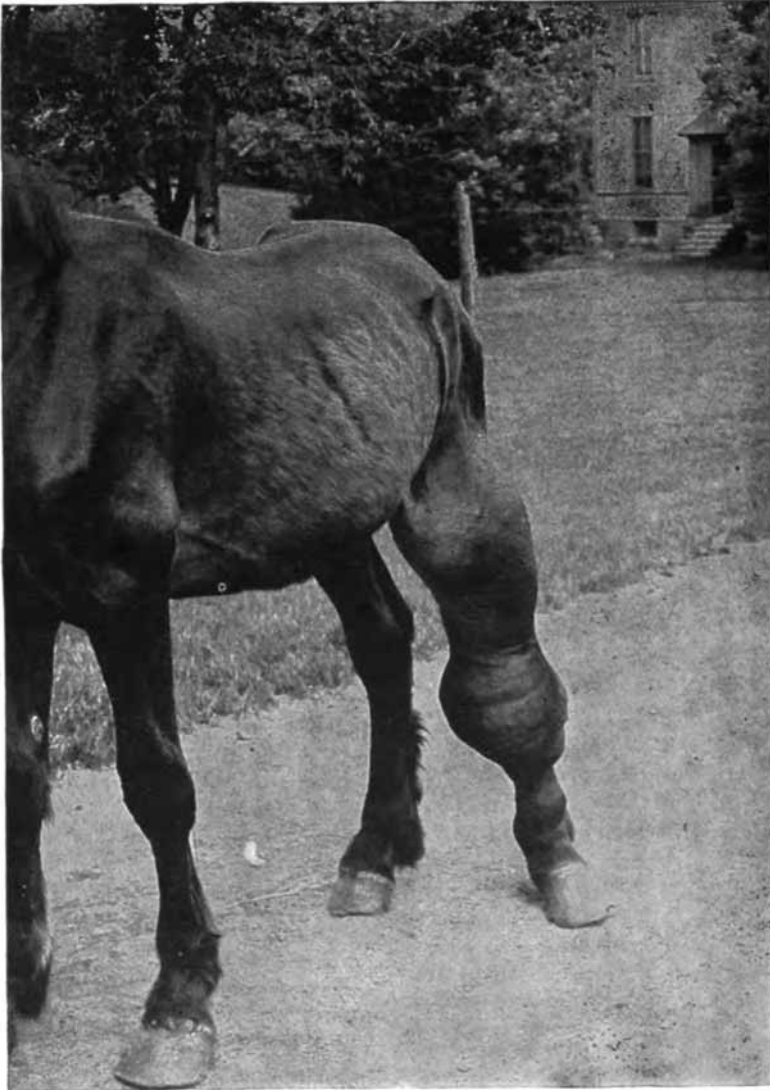

Fig. 144.—From photograph taken 6-20-'07 of a colt affected with a Subcutaneous Lipoma. Photograph presented by J. H. McNeil.

Microscopic sections of lipomatous tissue closely resemble normal adipose tissue, except that the cells may be larger and perhaps more irregular in shape. As in normal adipose tissue the adipose cells are supported by connective tissue cells and fibres. The application of Sudan III and osmic acid gives further proof of the composition of the cells.

Lipomata may be multiple but they are typical benign tumors, though death may result from the mechanical effects produced

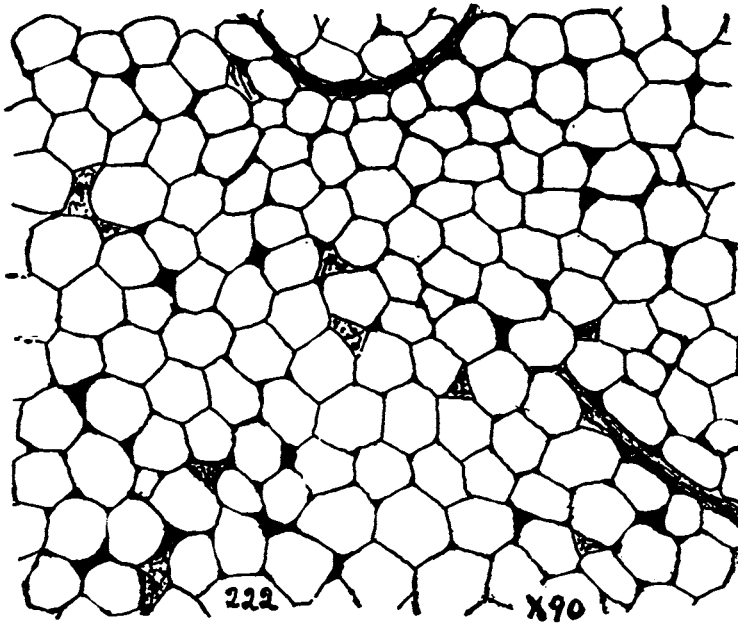


Fig. 145.—Section of a Lipoma from omentum of an ox, showing framework of adipose cells.

by them. They do not form metastases. Subserous lipomata produce volvuli which terminate fatally in hours. Large peritoneal or omental lipomata of the ox and dog frequently cause sufficient displacement of the abdominal organs to materially derange their function. Subcutaneous carpal lipomata in the horse may become so large that they mechanically interfere with locomotion. Lipomata may have a fibrinous infiltration and organization resulting in lipomatous elephantiasis.

OSTEOMA.

An osteoma is a tumor composed of osseous tissue. Pure osteomata are not common. They occur most frequently in relation to bones and usually at the union of osseous tissue developed from different ossifying centres. These tumors are quite common in mules, appearing as projecting pedunculated masses attached to the inferior maxilla. More rarely they are found in other organs, as the lung, parotid gland, mammary gland, etc.

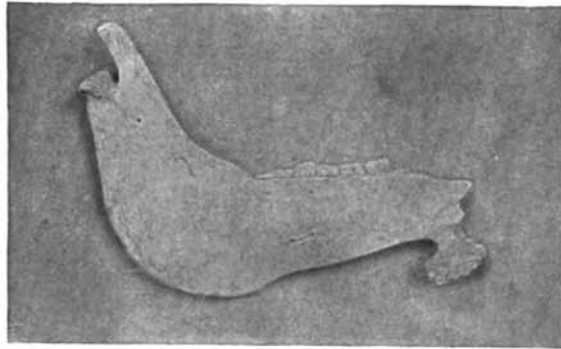


Fig. 146.—Pedunculated Osseous Tumor Maxilla. Horse.

These tumors are usually small, rarely becoming as large as a cocoanut. They are hard, nodular masses that are frequently lobulated and usually firmly attached to the surrounding tissue. It is possible that they are developed from osseous cells which have been misplaced in bone formation or from the osteogenetic layer of the periosteum. When they develop adjacent to pre-existing bone the periosteum or endosteum surrounds them. Those osteomata developing in other structure than bone are surrounded by a distinct membrane which is usually very similar to periosteum. Osteomata may be classified as: (1) hard, ivory or eburnated, and (2) soft, spongy or cancellated. Either of the foregoing classes may be homologous or heterologous. Homologous osteomata occur in bony structures and may be an exostosis or an enostosis. Heterologous osteomata occur in other tissue than bone.

Hard, ivory or eburnated osteomata are structurally very similar to the compact osseous tissue of a long bone. Haversian systems may be present or they may be absent. If the Haversian systems are present they are irregularly arranged and are approximately perpendicular to the surface of the related bone. If

the Haversian systems are absent the tumor is composed of superimposed lamellae like the outer circumferential lamellae of the shaft of a long bone.

Soft, spongy or cancellous osteomata are surrounded by a periostoid membrane. In structure they are similar to cancellous osseous tissue. The marrow spaces may be occupied by tissue that is structurally identical to red marrow or they may be filled with sarcomatous tissue, fibrous connective tissue, etc. The blood vessels are usually normal in structure and their distribution is through Haversian canals in the hard osteoma or the spaces in the soft osteoma.

Osteomata are invariably single; do not recur when removed; have no tendency to form metastases; and hence are benign.

They should be differentiated from (1) ossification of inflammatory new growths as ringbone, spavin, myositis ossificans, etc.; (2) hyperplasia of osseous tissue; (3) ossification of tumor tissue as fibromata, chondromata, etc.; (4) metaplasia in which osseous tissue is the end product; (5) calcification.

GLIOMA.

A glioma is a tumor composed of supporting cells (neuroglia cells) of the tissue of the central nervous system. Neuroglia tissue occurs in two forms, as ependymal cells lining the neural canal and the ventricles and as glia cells which are derived from the ependymal cells and act as a supporting framework of the central nervous system. Gliomata are of two types, depending upon the type of cells composing them, viz., spider cell glioma and mossy cell glioma. Gliomata have been observed only two or three times in the domestic animals. They usually have their origin in the gray matter near the central canal of the spinal cord or in the gray matter of the cerebrum. They do not become large and they are usually not encapsulated. They are composed of cells that are very similar to normal neuroglia cells. The glioma cells may be slightly larger than neuroglia cells but they have the fibre-like processes characteristic of them.

These tumors do not form metastases but are likely to produce a fatal termination by pressure upon nerve centers.

ODONTOMA.

Odontomata are tumors composed of dental tissue and usually occur in connection with teeth, particularly the superior molars. Odontomata are of frequent occurrence, the majority of dental diseases in two to five-year-old horses being due to

them (Williams). Facial bulging is a common symptom of them and there may be an excessive mucus discharge from the nostrils. Cystic odontomata may produce super-resonance, which is useful in differentiating them from empyema of the facial sinuses.

These tumors are derived from the enamel organ, dentine papilla, or the tooth follicle. Their derivation to some extent determines their structure. Those derived from the enamel organ are composed of an enamel covering and in some cases the entire odontoma is enamel. Dentine is usually the predominating tissue in those derived from the dentine papilla. From the tooth follicle there are usually formed cystic odontomata, although they may be fibrous or may contain ossified centres and cementum. Their structure varies considerably and it is not rare that all of the above structures are represented in one odontoma.

In size, odontomata vary from microscopic masses to irregu-




Fig. 147.—Photograph of an **Odontoma** of the interior maxilla of a horse.

lar bodies. Their shape and color are as variable as their size. Epithelial or enamel odontomata are the highest in the scale of hardness of all tumors. Other types of odontomata are soft. Cystic odontomata may be single or multiple, as many as three hundred having been observed in a single follicular tumor of this type. They may grow very rapidly but more frequently they develop slowly. They have no tendency to form metastases. Degeneration is common in those developing from the tooth follicle. Clinically they are benign but may cause fatal termination mechanically or from infection.

According to the derivation Sutton describes four classes of odontomata as follows:

1. Those derived from the enamel organ or epithelial odontomata. They usually appear as irregular masses covered with enamel. They may contain cystic cavities separated by enamel partitions. Epithelial odontomata are usually surrounded by a firm capsule, and in some instances appear to have had their origin from a mucous membrane. Microscopically they are found to be composed of enamel cells and irregular columns of epithelial cells forming alveoli. The epithelial cells vary in shape from columnar to the stellate or typical progenitors of enamel. These tumors occur in most of the domestic animals and usually in early life. Two epithelial odontomata were obtained from the left maxillary sinus of an aged horse used for dissecting purposes. These odontomata were completely enclosed in an osseous mass, the maxillary sinus being completely filled by the new growth. The facial bones were slightly bulged. The osseous formation surrounding the odontomata and the thickening of the facial bones indicated that considerable time had elapsed since their formation.

2. Those derived from the tooth follicle. Depending upon the nature of the neoplasm this group may be further subdivided into follicular and fibrous odontomata, cementomata and compound follicular odontomata.

Follicular odontomata result from hyperplasia of the tooth follicle tissues which thus prevents the normal eruption of the tooth. They may appear as simple or multiple cysts. Their walls may be calcareous or osseous but they are more frequently membranous. The cysts are usually subdivided into many compartments, the cavities of which are lined with epithelium. This lining epithelium secretes a viscid fluid, the accumulation of which is responsible for the enlargement of the cysts. They occur in sheep, hogs and horses.

Fibrous odontomata are produced by a marked increase of

the enveloping fibrous capsule of the follicle. The hyperplastic fibrous tissue usually fuses with the cementum, and the entire mass may later become calcified or ossified. These odontomata are most common in ruminants, goats especially being affected. They are prone to occur in animals afflicted with rickets.

Cementomata (*Osteocystoma capsulare dentiferum*) are formed by ossification of excess tissue developed around the tooth follicle. The hyperplastic cementum may include several tooth germs. They appear as masses of cancellous or spongy bone and are structurally very similar to cementum, being composed of irregular spaces surrounded by osseous tissue containing branched lacunae. They are most common in horses, occurring most frequently in connection with the incisor teeth.



FIG. 148.—**Epithelial Odontoma.**

Compound follicular odontomata result from the ossification of irregularly located areas of the tooth follicle tissues, thus leaving intervening areas of fibrous tissue. The ossified masses are designated denticles and they may be very numerous, as many as three hundred having been observed in a single tumor. The intervening tissue usually degenerates and becomes of a liquid consistency. Thus the tumor appears as a cyst containing many cavities. The denticles vary in size and consistency. These tumors have been observed in the goat, sheep, ox, and horse.

3. Radicular odontomata are those derived from the dental papilla, developing from the roots of a tooth after the crown has formed. They appear as bony masses and are frequently enclosed within the maxilla. Structurally, they consist of dentine and cementum, the dentine usually being surrounded by a cemental capsule. They are occasionally observed in domestic animals, being most common in boars.

4. Composite odontomata are composed of varying amounts of irregularly arranged enamel, dentine and cementum. A single tumor may contain several teeth fused into one mass. Their structure varies with the amount of each of the above named constituents they contain. Thus they may be almost entirely enamel or contain a very little enamel. They may be solid and massive or cystic. They are very likely to cause suppuration and necrosis of the adjacent tissues. This type of odontomes occurs more frequently in the horse.

Dentigerous cysts are more properly classified as a type of teratomata and will be discussed with that group of tumors.

NEUROMA.

Neuromata are tumors composed of nerve tissue. They are exceedingly rare. They occur in connection with ganglionic cells and most frequently those of the sympathetic ganglia, although they may occur in the brain. They appear as nodular growths varying from the size of a pin head to that of an apple. They are gray or white in color, rather firm, and usually surrounded by a capsule. Irregularly shaped ganglionic cells interposed with some nerve fibres constitute their minute structure.

These tumors should be differentiated first from the so-called "amputation neuromata," which are simply an entangled mass of regenerated axones and are not tumors; second from fibromata that develop from the perineurium or endoneurium of a nerve trunk.

Neuromata may be multiple but they are benign.

ANGIOMA.

These are vessel tumors that are developed independently of pre-existing vessels. But it is frequently impossible to determine whether the mass of vessels is a result of excessive growth of the pre-existing vessels (hyperplasia) or whether they are newly-formed vessels.

Possibly angiomata should be discussed under the caption of

endotheliomata as it has been thought by some that the endothelium is the only neoplastic portion of an angioma.

This group is composed of (1) hemangiomata. (2) lymphangiomata.

Hemangiomata are blood-vessel tumors. In the human they are found most frequently in the skin and may occur in the skin in domestic animals, but are not often observed there because of the pigmentation of the skin. They are found most frequently in the liver and the spleen of the ox, dog, horse and sheep. An occasional case is observed in the subcutaneous tissue of the horse. Hemangiomata may be subdivided into four varieties.

Hemangioma simplex (Capillary telangiectases, nevus, birth mark) is a tumor in which there is an excess of capillary vessels are considerably enlarged or dilated. The vessel wall is usually altered in structure, the endothelial cells being larger and the perivascular tissue more dense. These are quite common in the liver of the ox where they appear as irregular blood spots, red or purplish in color.

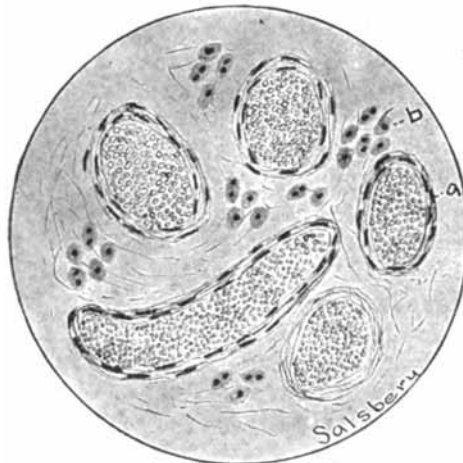

Fig. 149.—**Haemangioma Simplex.**

a. Large capillaries engorged with blood.

b. Liver cells.

Cavernous hemangioma (hemangioma cavernosum) is a tumor composed of spongy tissue similar to erectile tissue. The cavernous spaces are filled with blood, thus coloring the tumor red or bluish-red. These tumors are found most frequently in the liver and spleen. An ox liver containing cavernous spaces, each as large as a hen's egg and containing parietal thrombi, has been observed. A lobulated enlargement in the spleen of a dog was

found to be a cavernous hemangioma. The spaces in cavernous hemangiomata are lined by endothelium that is supported by a very limited amount of white fibrous connective tissue, yellow elastic tissue being practically absent.



FIG. 150.—Photograph of spleen of dog affected with an *Hemangioma Cavernosum*.

Hemangioma hypertrophicum is a blood-vessel tumor composed of masses of relatively small vessels, in which the vessel walls are hypertrophied. One of these tumors occurring in the subcutaneous tissue of the metacarpal region of a horse has been observed. It appeared as a mass beneath the skin and was about the size of a hen's egg. Pulsations could be observed and by palpation they were quite distinct. The tumor when removed was a tangled mass of blood-vessels with comparatively small openings. Microscopically, the vessel walls were found to be hypertrophied. The vessels were held together by fibrous connective tissue.

Cirroid aneurisms are tumors composed of dilated and enlarged

tortuous arteries. This variety of hemangiomata is not common in the domestic animals.

Lymphangiomata are tumors composed of newly-formed lymphatic vessels. These tumors are not common; in fact, only one

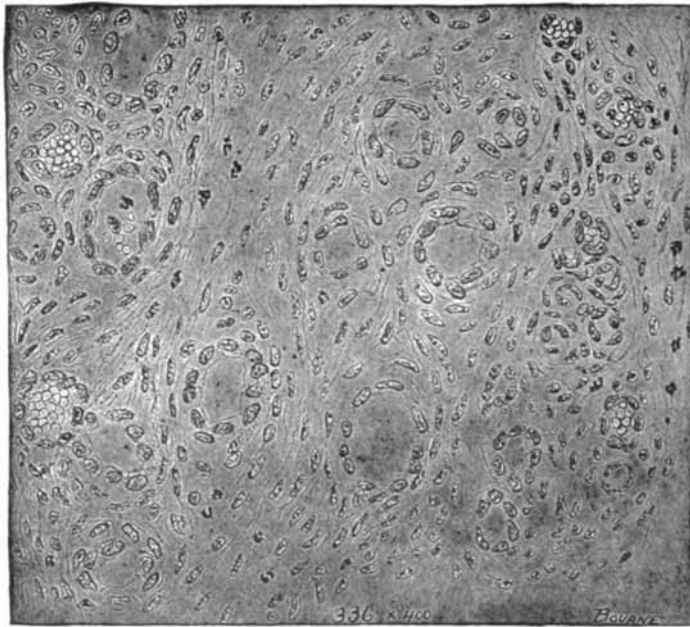


Fig. 151.—Section of **Hemangioma Hypertrophicum**, showing an increase in the number of the vessels and an hypertrophy of their walls.

or two cases have been reported by veterinarians. The tumors may be conveniently divided into capillary and cavernous.

Angiomata are usually benign tumors, although by rupture they may produce fatal hemorrhage or lymphorrhage.

MYOMA.

Myomata are muscle tumors. They are divided into two classes: 1. Leiomyomata or the smooth muscle tumors. 2. Rhabdomyomata or the striated voluntary muscle tumors. Myomata, found occasionally in the human, are rare in the lower animals.

Leiomyomata are found most frequently in those locations in which involuntary muscle tissue normally exists, as the uterus, bladder, intestine, etc. They are nodular or diffuse, dense, pale pink masses appearing very similar to fibromata. Microscopically they are composed of miscellaneous arranged involuntary muscle cells. They differ from fibromata in that the muscle cells are thicker and usually not as long as the fibres of fibromata. Frequently they are combined with fibromata forming a leiomyofibroma, making the diagnosis more difficult. Leiomyoma cells may be very similar to the cells of a spindle-celled sarcoma, but




Fig. 152.—**Leiomyoma**, small intestine, mule.

the nuclei of the former are long and rod-shaped while those of the latter are oval in shape, a characteristic usually sufficient for diagnosis. The cytoplasm of the leiomyoma cells stains densely with acid stains.

Rhabdomyomata have been found in the kidney, ovary and testicle. They are probably the result of the development of misplaced embryonic myoblasts. These tumors are usually pale in color. In microscopic section the cells are irregularly striated,

and are variable in shape and arrangement. These tumors are benign.

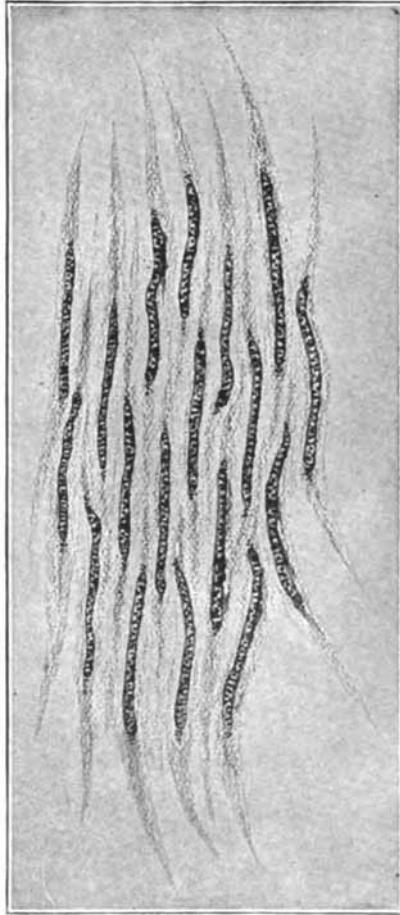


Fig. 153.—Leiomyoma.
a. Smooth nucleus cell, showing nucleus.

SARCOMA.

A sarcoma is a tumor composed of embryonic connective tissue cells. The cells have no tendency to become mature but constantly appear as undifferentiated embryonic cells. Sarcomata are of frequent occurrence in all domestic animals. They have no predilection for tissue or location, and are variable in size and shape. They may be circumscribed but are more frequently dif-

tuse. Metastases are frequent in the lungs, liver and kidney. Metastatic sarcomata are usually circumscribed.

Sub-surface sarcomata may produce necrosis of the surface tissue, the tumor projecting as a red, granular mass, which appears very similar to exuberant granulation. The surface tissue may not be destroyed, the tumor appearing as a sub-surface nodule or diffuse mass. Some sarcomata are encapsulated and are easily enucleated, but the malignant varieties have no capsule and it is impossible to differentiate the surrounding tissue from that of the tumor. Sarcomatous tissue may be soft and spongy or hard and dense, depending upon the extent of the intercellular substance and the kind of cells composing it. In color they vary from gray or white to pink and they may be mottled, depending upon hemorrhage, pigmentation, or necrosis.

The microscopic appearance varies with the different varieties, but in general they are composed of embryonic cells having




FIG. 154.—Photograph of a horse affected with **Sarcoma** of the **Mediastinum** resulting in obstructed circulation.

(a) Oedema inferior thoracic region.
(b) Jugular vein engorged with blood.

(c) Subcutaneous veins.

a limited amount of intercellular substance. The cells may be round, spindle, or myeloid, and the intercellular substance may be mucoid, fibrous, cartilaginous or osseous. The cells contain a large centrally located ovoid nucleus, occupying practically the entire cell body. Mitotic figures are common in rapidly growing sarcomata. Frequently there are multipolar mitotic figures indicating the possible division of a cell into three or more daughter cells. Karyolysis or nuclear fragmentation is well marked in those cells that are centrally located in the tumor, that is, in degenerating centres, and in cells of sarcomata that

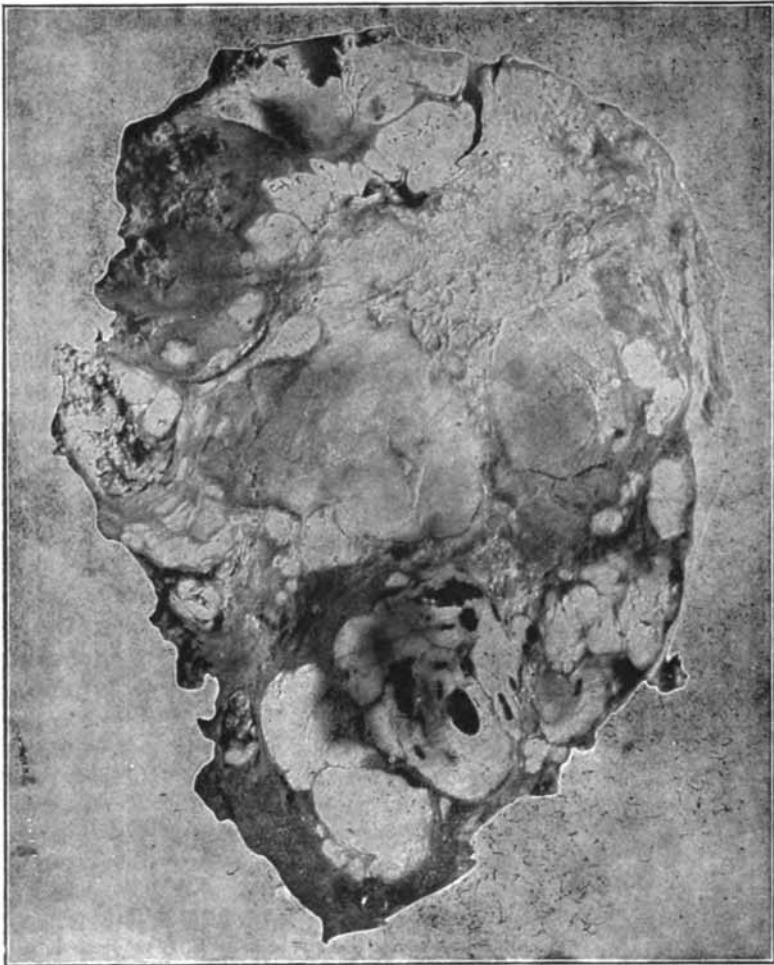

Fig. 155.—Section of tumor, showing mottled appearance, a result of Necrotic centres

are not growing rapidly. The portion of the cell body not occupied by the nucleus is composed of undifferentiated protoplasm. In appearance the intercellular substance varies according to its composition. An abundance of capillaries and small blood vessels are found in sarcomata. These may be normal in structure or they may be infiltrated with sarcomatous tissue, and, in some cases, the blood flows through channels formed by sarcoma cells. Hemorrhage is of frequent occurrence in sarcomata. The blood vessels have no regularity in their distribution, a structural peculiarity frequently resulting in degeneration and necrosis. Lymphatic spaces and vessels are absent in sarcomata, excepting lympho-sarcomata, unless they are entangled during the development of the tumor. Nervous tissue has not been demonstrated as a distinct entity in sarcomata. There are usually many leucocytes and frequently some plasma cells in sarcomatous tissue. The plasma cells may produce the intercellular structures of sarcomata or they may become adult connective cells and produce fibrous connective tissue.




Fig. 156.—Round cell Sarcoma.

The rapid development and the irregular distribution of blood vessels predispose sarcomata to destructive processes. Muroid degeneration frequently occurs and may result in the complete destruction of the tumor. Necrosis is also quite common, and suppurative conditions are not rare. If the normal tissues are eroded, exposing the tumor tissue, septic infection is common and sometimes results fatally.

This group of tumors may be classified, according to their

cellular elements, as (1) round-celled sarcomata, (2) spindle-celled sarcomata, and (3) myeloid-celled sarcomata.

Round-cell sarcoma. This tumor is composed primarily of round cells (spherical cells) and is rather common. They develop in any tissue and are, as a rule, the most malignant tumors of this entire group. They are soft, spongy, and usually quite vascular, and, as a rule, are not encapsulated.

Structurally the cells of this variety approximate the embryonic epithelial cells more closely than do those of any of the other types. According to the size of the cells two classes may be recognized, viz.: small and large. There is, however, no distinct line between the two classes. The small, round cells are about the size of lymphocytes while the large, round cells are as large and sometimes much larger than mononuclear leucocytes. The nuclei of this type of sarcoma cells are, relatively, much larger than the nuclei of lymphocytes or leucocytes. In fact, the nucleus occupies practically the entire cell body. The intercellular substance is very limited and is usually mucoid or reticular. Blood vessels are usually numerous, and their walls are frequently formed by sarcomatous cells. Metastatic growths are frequently in this type. The cut on page 273 is from a photograph of the lung of a horse, showing metastatic round-celled

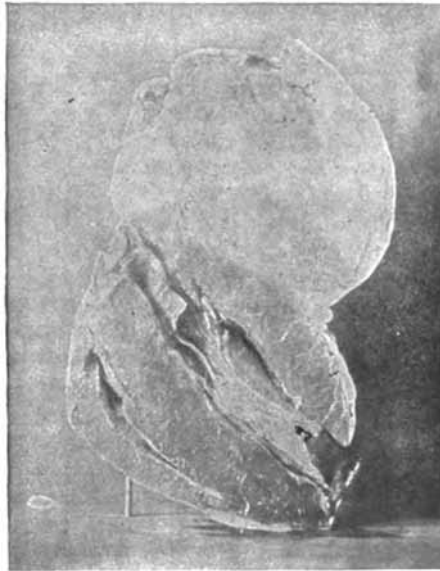


Fig. 158.—Photograph of sheep's heart, showing a lympho sarcoma of the pericardium.

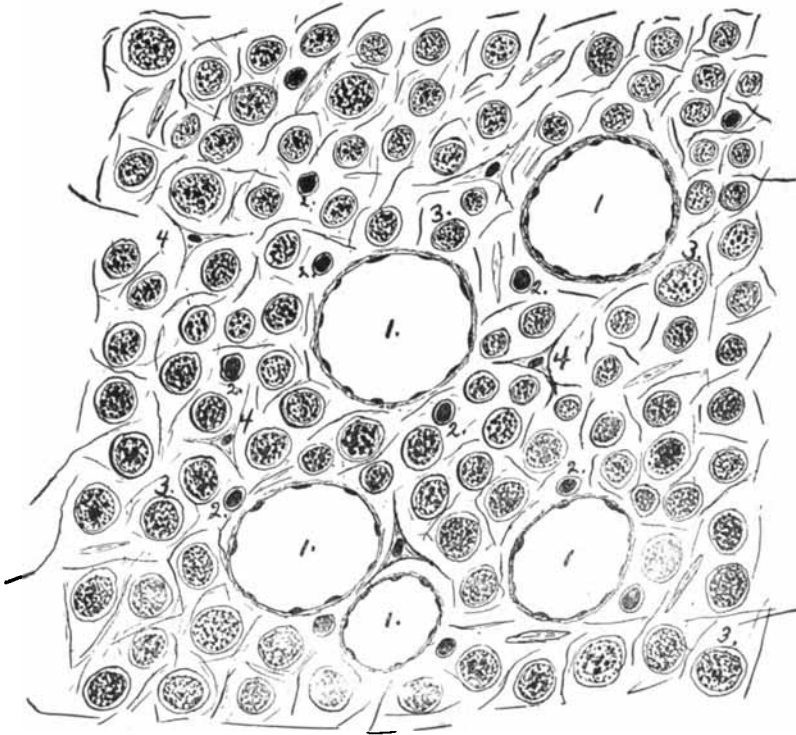


Fig. 158.—Section of a **Lympho Sarcoma** of a dog's omentum, showing the lymph vessels and sarcomatous tissue.

sarcomata. The primary tumor involved the eye-ball and finally destroyed the soft structures of the entire orbit. In this case two or three metastatic tumors were observed in the liver also. The cut on page 299 is a photograph of a horse in which there was an extensive sarcomatous formation in the thoracic cavity involving the mediastinum, pericardium, pleura and some smaller nodules in the lung. (The lung nodules were, no doubt, metastatic formations.) Because of their tendency to form metastases and the rapid peripheral infiltration these tumors usually cause a fatal termination.

Lympho-sarcomata are a variety of round-celled sarcoma, and are called lymphomata by some authors. They are quite common in all domestic animals. These tumors have their origin in lymphoid tissue and are extended by the lymph. Two cases have been studied in the ox in which the primary lesion was in the wall of the abomasum. One case of generalized lymphosarcomatosis has been observed in a chicken. A pericardial lym-

phosarcoma was found in a post-mortem examination of a sheep. An omental lymphosarcoma in a dog was reported in the American Veterinary Review, December, 1905. The color, consistency and size of lymphosarcomata is quite variable.

Microscopically these tumors are found to be composed of lymphoid cells, the tumor cells being supported by stellate cells. Lymph vessels are usually quite numerous and their structure is similar, if not identical, to that of normal lymph vessels. The stellate supporting cells and the presence of lymph vessels are the distinguishing characteristics of lymphosarcomata. There is no leucocytosis in animals affected with lymphosarcomata, while in those affected with leukemia leucocytosis is well marked.

These tumors are malignant. They form metastases through the lymph and blood channels. They are usually surrounded by a very thin capsule.

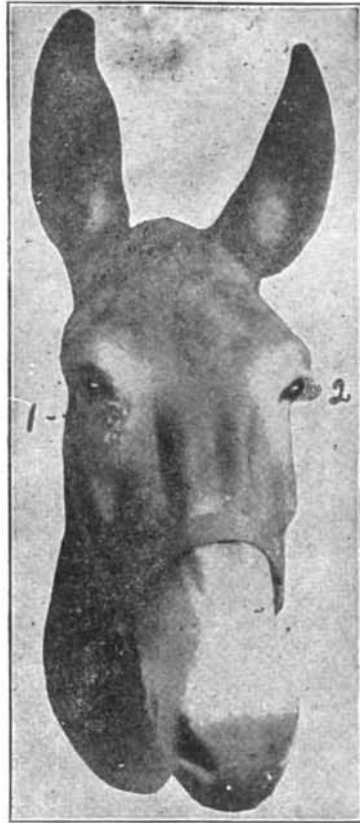


Fig. 159.—Photograph of a mule affected with a spindle cell Sarcoma of the eyelids
1. Granular denuded tumorous surface. 2. Granular fungoid tumorous mass.

Spindle-Cell Sarcoma.—Tumors of this variety are composed of spindle-shaped cells. They are more firm and dense than the round-cell sarcomata. These tumors are not rare, occurring most frequently in connection with the skin or subcutaneous tissue. Some of the resistant and incurable cases of fistulous withers are spindle-celled sarcomata. A collar boil that did not respond to treatment was found to be a spindle-cell sarcoma. These tumors are common in the eyelids of horses and mules and are sometimes quite resistant to surgical interference. The




Fig. 160.—Section from spindle cell Sarcoma of a mule's eyelid.

cells vary from short, thick fusiform cells to elongated fibre-like cells. Spindle cells are more matured than the cells of round-cell sarcoma. Round cells have no tendency to become spindle cells, neither do spindle cells become either round cells or matured connective tissue cells. The cells in spindle-cell sarcomata have no definite arrangement but extend in all directions. In microscopic section some cells are cut transversely, others obliquely, and still others longitudinally. Hence we find the nucleus is centrally located, is usually spherical or oval in shape, and is not as large in proportion to the size of the cell as that of the round cells. Some have suggested a classification of this

group into large and small-celled varieties. The cells are usually held together by reticular connective tissue. This may be demonstrated in sections in which the sarcoma cells have been dissolved out by acetic acid. The density of the tumor depends upon the relative quantity of protoplasm the cells contain and the amount of intercellular material. A tumor composed of short, thick spindles is less dense than one composed of fibre-like cells. Blood vessels usually have normal vessel walls and are not as numerous as they are in round-cell sarcomata.

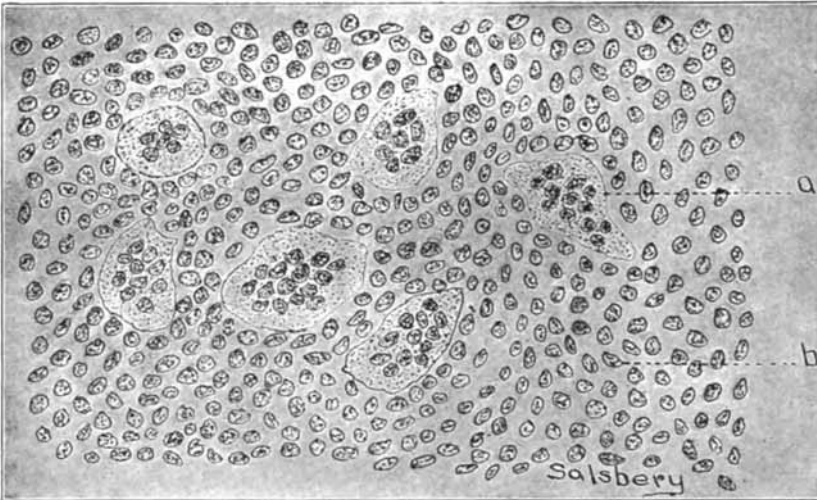


FIG. 161.—Myeloid or Giant cell Sarcoma of the Humerus.
a. Giant cells. b. Sarcoma cells.

These tumors are usually encapsulated, rarely form metastases and are, in general, not as malignant as the round-cell variety. They may be mistaken for fibromata, but a careful study of a microscopic section is usually sufficient for differentiation. Fibromata contain no elements that appear like transverse sections of spindle cells. Leiomyoma may be differentiated by the shape of the nucleus and the selective action of stain as picrofuchsin.

Myeloid-Cell Sarcoma (Giant-Cell Sarcoma).—This is a variety of sarcoma characterized by the presence of myeloid or large multinucleated giant cells (myeloplaxes). Surgeons and pathologists frequently find myeloid sarcomata in man, but they are rare in domestic animals. They are invariably found in relation to, or in connection with, bone-marrow, or more rarely

in relation with periosteum. They frequently contain cartilaginous, osseous or calcareous centres.

Microscopically, they are composed of myeloid cells and round or spindle cells. The myeloid cells are the distinguishing elements of this variety of sarcoma. The size of the myeloid cells is variable, frequently being 80 to 100 microns in diameter and with an irregular outline, varying in shape from a sphere to an elongated mass. Their protoplasm may be quite granular or almost clear. They have many nuclei—150 being observed in one cell. These nuclei have no definite arrangement but occur miscellaneously throughout the entire cell body. The round and spindle cells are like those occurring in round and spindle-cell




Fig. 162.—Photograph of horse's head affected with mixed cell Sarcoma.

sarcoma. There may be an excess of one or the other or they may be equal in number. The intercellular substance varies from mucoid to calcareous in nature. There is usually an excessive blood supply, the blood vessel walls being usually normal

in structure. Degeneration as well as necrosis and calcification are of frequent occurrence in myeloid sarcomata.

These tumors may not be completely encapsulated, though there is always a tendency for them to be circumscribed. They are the least malignant of all sarcomata. They rarely form metastases.

Mixed-Cell Sarcoma.—This is a variety of sarcoma characterized by the presence of variously shaped cells, as round, spindle and even stellate cells. This variety is not as common as either the round-cell or spindle-cell varieties. They have been observed in the horse, hog and ox, but they doubtless occur in all domestic animals. They affect bone, glandular tissue, and meninges of the brain, in fact, no tissue is exempt. An interesting case of mixed-cell sarcoma of the inferior maxilla of a horse was described in the December Veterinary Review, 1905. The tumors frequently degenerate and become necrotic. Microscopically they are composed of round cells and spindle cells that are identical in structure with those described in the discussion of round-cell and spindle-cell sarcomata. Stellate cells may be present, and are very similar in structure to mucoid connective tissue cells. The cellular elements are supported by reticular tissue or by fibrous connective tissue. The number of blood vessels is variable. There is an excess of vessels in those

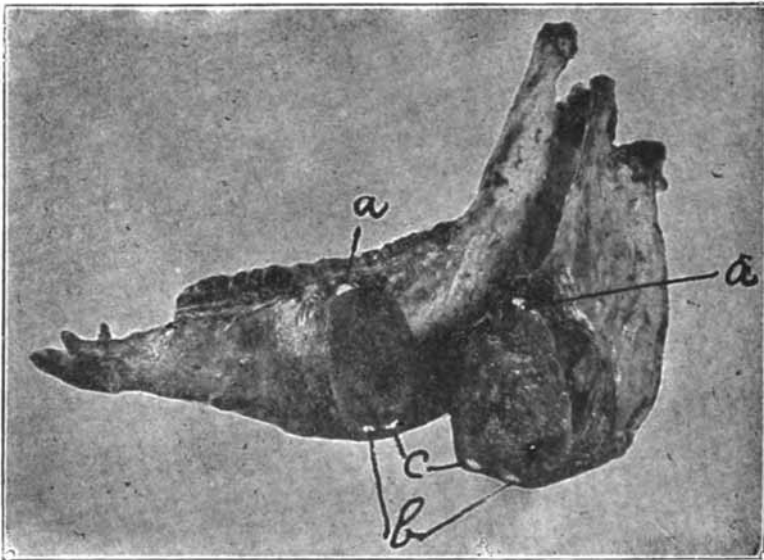


Fig. 163.—Photograph of Maxilla of horse shown in Fig. 162, showing 3 bony points; the remainder of the maxilla being completely destroyed by the sarcomatous tissue.

made up principally of round cells and in those that have a limited amount of intercellular substance. The vessel walls may be normal or they may be composed of sarcomatous tissue. Degenerate or necrotic changes in the tissue necessarily alter the microscopic appearance.

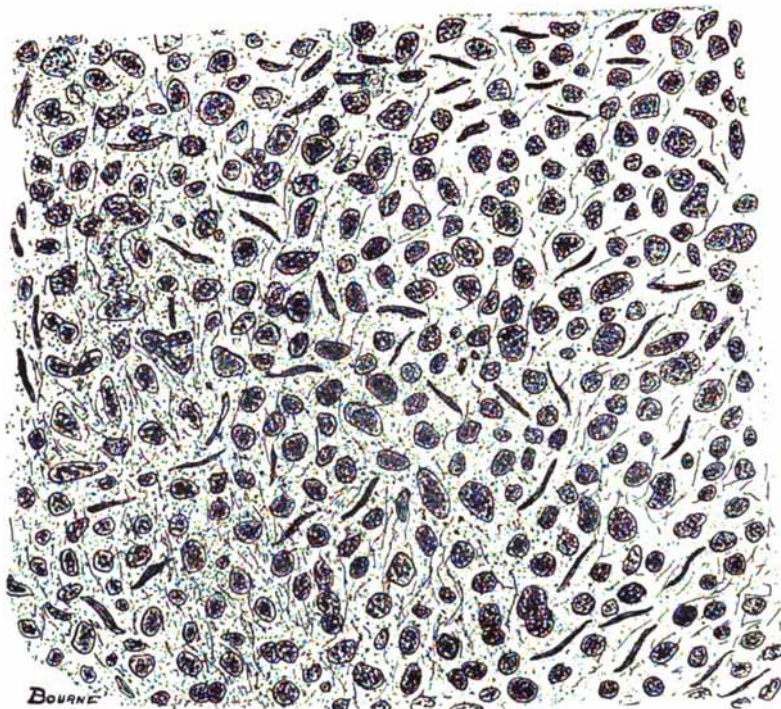


Fig. 164.—Section of a mixed cell Sarcoma of the Inferior maxilla of a horse.

These tumors are usually diffuse; that is, they are not encapsulated. They form metastases, and hence are malignant.

Alveolar Sarcoma.—This is a sarcoma characterized by the arrangement of the sarcoma cells into groups or nests, and is occasionally found on domestic animals, especially in the ox and hog. The reproductive glands, ovary and testicle, are the structures most frequently invaded by them. They may become quite large. An alveolar sarcoma obtained from the ovary of a heifer weighed 15 kilograms (33 lbs.) and was about 20 cm. (8 in.) in diameter.

Microscopically the cells are usually round, although they may be spindle-shaped. The stroma of the tumor is made up of

two portions. One portion is usually composed of spindle cells which are connected into dense bands extending in various directions and forming alveoli; hence the name alveolar. The other portion of the stroma is intercellular and corresponds to that of the round-cell sarcoma. The arrangement of the cells into nests is suggestive of a carcinoma, but the differentiation is not difficult and depends upon; first, the presence of intercellular substance between the cells which is present in sarcomata but is absent in carcinomata; second, sarcomatous cells are embryonic connective tissue cells and hence contain nuclei relatively large in proportion to the size of the cell, while carcinomatous cells are embryonic epithelial cells and contain nuclei relatively small in proportion to the size of the cell.

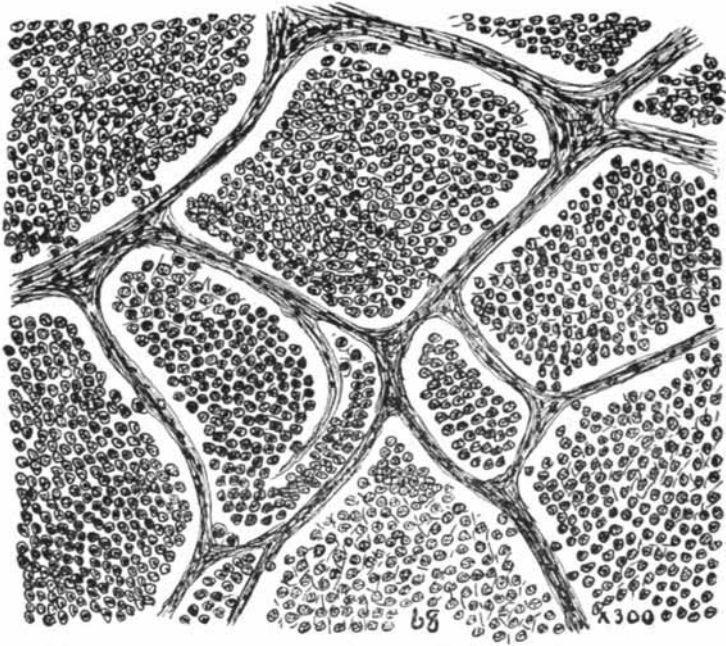


Fig. 165.—Section of **Alveolar sarcoma** from ovary of heifer showing alveoli filled with sarcomatous cells.

These tumors grow slowly. They are usually encapsulated and have no tendency to form metastases. They are very mildly malignant.

Entothelioma is a tumor composed of endothelium. This is a tumor that is not specifically a sarcoma, but may be so classed. Endothelium has the same origin as connective tissue, i. e., the

mesoderm. Embryonic endothelial cells are structurally identical with embryonic connective tissue cells. These tumors are not very common in domestic animals. An endothelioma was observed in the lung of a dog, another in the testicle of a bull. These tumors may have their origin from the endothelium lining blood or lymph channels, peritoneum, pleura, pericardium, arachnoid membrane, any organs developed from mesothelium, or deflections from any of them. They are variable in shape, size, color and consistency.

Microscopically they are composed of cells that most fre-

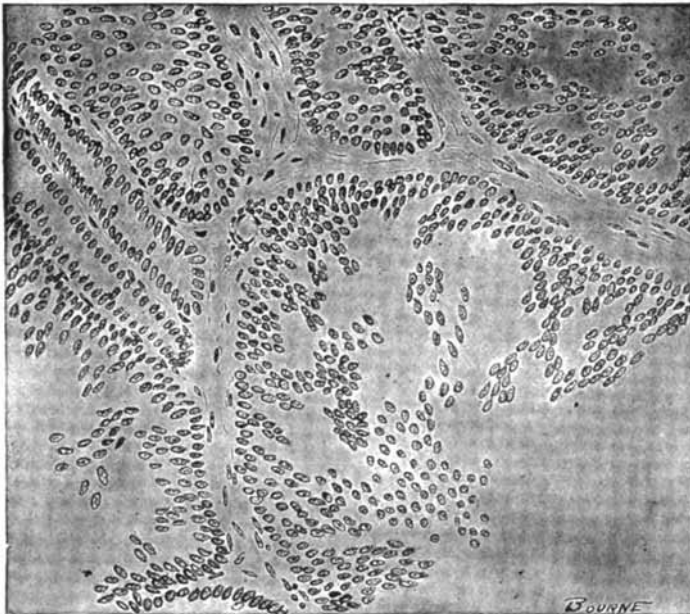


Fig. 166.—Section of Endothelioma from a bull's testicle. Note the bands of connective tissue and arrangement of cells.

quently resemble sarcoma cells, although they may approximate the structure of carcinoma cells. The cells may be arranged in tubules, transverse or oblique sections appearing as sections of gland tubules or acini. If arranged in columns transverse or oblique sections appear as cell nests. The cells are usually cubical or spherical in shape, although they may be spindle or even squamous. The stroma varies according to the tissue invaded and may be dense fibrous or mucoid. Blood vessels are usually quite numerous, and if the endothelium is derived from

the endothelium of a vessel, the vessel may be very irregular in calibre and structure. If the cells occur in columns or nests it will be necessary to differentiate them from carcinomata. This differentiation involves the comparison of cells derived from mesoderm and those derived from entoderm or ectoderm. The only essential difference, and that is not constant, is the size of the nucleus. The differentiation may also be governed to some extent by the distribution of the blood vessels. If the cells occur in tubules, their differentiation from the adenoma will be necessary. Adenomata may be differentiated by observing the same




Fig. 167.—From drawing of a Nodule of a Mediastinal endothelioma.
1. Column of endothelial cells. 2. Diffuse mass of endothelial cells.

factors that are used in differentiating endotheliomata from carcinomata. Alveolar sarcomata are very difficult to differentiate from endotheliomata, in fact it is sometimes impossible.

These tumors are not encapsulated and usually form metastases. They usually occur in internal organs and hence surgical relief is impossible. Fatal termination is the usual outcome.

Fibrosarcoma.—This is a tumor composed of both adult and embryonic connective tissue. They are quite common, especially in the eyelids and in labial commissures of horses and

mules. Several cases of dense tissue growths in the withers of horses have been observed. These animals when presented appeared to be affected with chronic inflammation of the subcutaneous tissue or deeper structures. Most of the above cases were clinically diagnosed as fistulous withers and an operation recommended. The operation usually consisted of dissecting away the dense masses of tissue. The cases were usually returned in




Fig. 168.—A so called **grape sarcoma** from uterus of a cow.

from four to six weeks after the operation with growths larger than those present before the operation. The operation was usually repeated two or three times with the same results.

On microscopic examination these growths were found to be fibrosarcomata, being composed principally of fibrous connective




Fig. 169.—Photograph showing Melanotic tumor superior to anus.

tissue in which there were some spindle cells and occasionally a few round cells. The presence of both fibrous and sarcomatous tissue is the principal characteristic of these tumors. The number, size and distribution of blood vessels are very irregular.

These tumors are not distinctly encapsulated, but they do not form metastases. They are prone to recur after ablation. They may destroy life after a considerable time, as their growth is

relatively slow. Operation usually stimulates them to grow more rapidly.

Melanosarcoma.—A melanosarcoma is any variety of sarcoma in which melanin is deposited in the tumor cells. These tumors are quite prevalent. Gray horses seem to have a special predisposition to them, but they are also found in bay and black horses, black or red cattle, black hogs, and, in fact, all varieties of do-

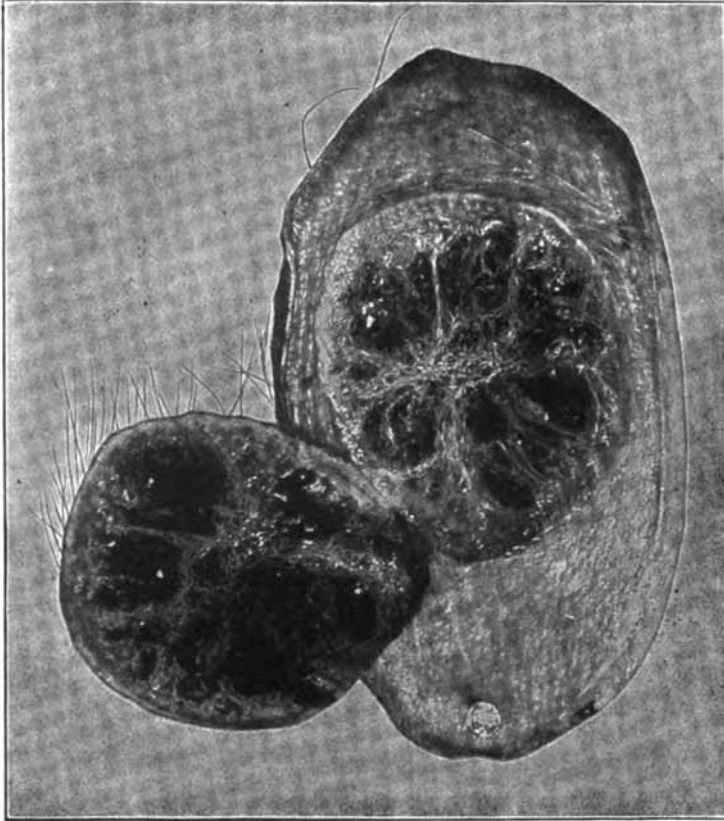


Fig. 170.—Melano Sarcoma of hog skin.

mestic animals regardless of color. On microscopic examination, melanin is found deposited in the tumor cells. The melanin may be in masses or granular and occasionally it may be found outside of the cells. Excepting the deposit of melanin, these tumors have the same microscopical appearance as the round or spindle-cell sarcomata described before.

Melanotic sarcomata are frequently malignant. In an autopsy of a gray mare metastases of melanosarcomata were found in the liver, lung, spleen and kidney, the primary growth being located in the subcutaneous tissue on the right superior portion of the anus. Another case was observed in which there was generalized melanosarcomatosis in a short-horn cow.

Myxosarcoma.—This is a tumor composed of myxomatous and sarcomatous tissue. The existence of this group of tumors

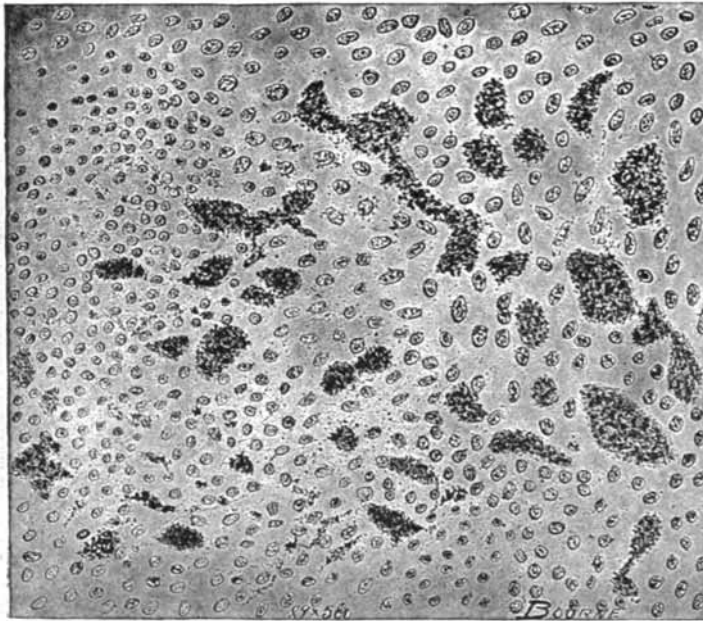


Fig. 171.—Section of **Melano Sarcoma** of a horse's liver, showing the deposit of melanin in the tumor cells.

is doubted by some pathologists because sarcomata are prone to undergo mucoid degeneration, and, because if the mucoid degeneration is of limited extent and generalized throughout the entire tumor, differentiation would be practically impossible. If the mucoid degeneration affects localized areas the differentiation is not difficult. One myxosarcoma has been studied. It involved the right lobe of the liver of a cow but was not the cause of death. The tumor, about the size of a goose egg, was encapsulated, soft and pale pink in color.

Microscopically it was composed of stellate cells, the processes of which were apparently united, thus forming alveoli.

There were also round cells, some areas being composed almost entirely of round cells and others of stellate cells. The round cells were like the round cells found in sarcomata. The alveoli formed by the stellate cells were filled with a stringy mucus material. A few blood vessels were observed but they were not as numerous as in pure sarcomata.

These tumors may be malignant. When they occur upon or near available surfaces they usually become necrotic, slough and produce no further trouble.

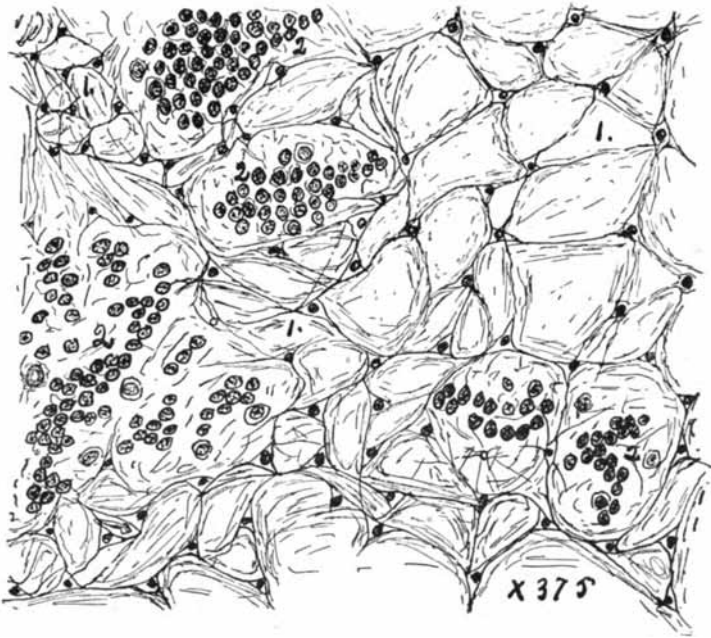

Fig. 172.—Section of a **Myxo-Sarcoma**, from a cow's liver, showing:
 1. Spaces formed by the union of the processes of the stellate cells.
 2. Sarcoma cells.

Chondrosarcoma and tumors composed of chondromatous and sarcomatous tissues are not common. They usually occur in the location most favorable for chondromata. A chicken affected with a chondrosarcoma of the sternum was obtained at a butcher's stall at the city market in Kansas City recently.

Microscopically, these tumors are found to be composed of a mixture of chondromatous and sarcomatous tissues in varying proportions. Sometimes the chondromatous tissue is apparently stroma for the sarcoma tissue proper. In other cases the stroma is apparently formed of sarcomatous tissue and the chondromatous tissue is the essential portion of the tumor.

These tumors may grow to an enormous size. They are not as malignant as pure sarcomata and metastatic tumors are rare. They should be differentiated from chondroifying sarcomata and from sarcomata involving cartilage.

Osteosarcoma.—This variety of tumors is composed of osseous and sarcomatous tissues. They are rather common, occurring in the horse, dog and ox.

Microscopically, osteomatous and sarcomatous tissues are arranged in various proportions and in various relations, but the combining tissue in any case must be new growth tissue. Ossifying sarcomata are not osteosarcomata, neither are sarcomata of osseous tissue osteosarcomata.

These tumors are usually malignant, but they do not form metastases.

Hemangiosarcoma.—These tumors are composed of hemangiomatous and sarcomatous tissues. They are relatively common, occurring in the location common for haemangiomata and may affect any of the domestic animals. These tumors are essentially very vascular and are highly colored.

In microscopic examination variations are observed in different hemangiosarcomata. The sarcomatous tissue in some cases appear to have had its origin from the tunica adventitia of the vessel wall; in other cases the sarcomatous tissue appears to have had its origin independent of the vessels. Again, the vessels may act as the supporting stroma for the sarcomatous tissue. The vessels may be capillary or cavernous, sinusoid or plexiform. The vessel wall may be practically normal, but more frequently it is either hypertrophied, as a result of increased number of the cellular elements or increase in the size of the cells, or it may be thin, scale-like and atrophied. Sometimes the endothelial cells lining the vessels are cubic or columnar in shape, thus diminishing the lumen of the vessel. The sarcomatous cells may be either spindle-shaped or round.

These tumors are quite malignant, and they usually grow rapidly. The metastatic tumors are most frequently pure sarcomata.

PAPILLOMA.

(Warts.)

Papillomata are fibro-epithelial tumors. These are perhaps the most common of all tumors. They occur upon the surface of the skin, and upon mucous, serous, and synovial membranes. They are very common upon the skin of calves, especially around the eyes, ears and poll. They occur most frequently on the lips,

buccal mucous membrane, and arms of dogs. The skin of the legs and lips are the common locations in the horse. The lumen of the oesophagus of the ox may be almost occluded by the presence of masses of papillomata. In a horse used for dissecting the cardio-pyloric junction was found to be a mass of these tumors. The mucous membrane of the bladder of the ox, sheep

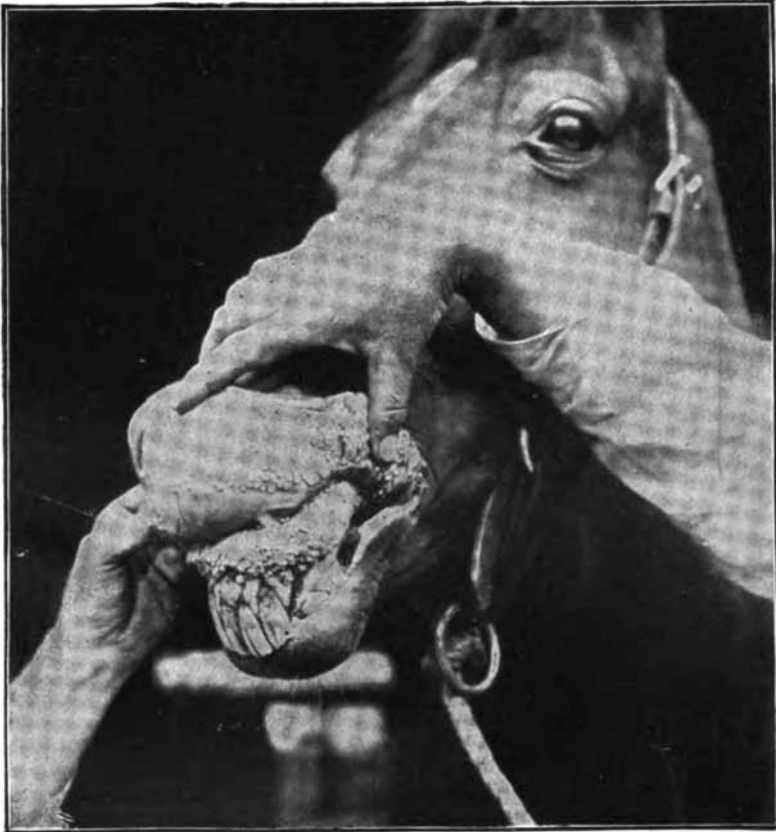

Fig. 178.—From photograph showing **Papillomatosis** of mucous membrane of lips of a horse.

and hog is sometimes studded with papillomata. These tumors have also been observed upon the combs and wattles of fowls. They sometimes occur in horses' feet but are usually necrotic and do not have the appearance of papillomata.

These tumors may be hard, i. e., covered over by stratified squamous epithelium that has become cornified. This variety is

invariably found upon the skin and constitutes the growths ordinarily known as warts. They may also be soft, and are then found upon mucous, serous or synovial membranes, in which case the covering epithelium is not cornified. Hard papillomata or warts may appear as tabulated masses, as fungoid growths or as a mass of villi. Any of the above forms may have a smooth surface or be fissured with a very irregular surface. They vary in size from a millet seed to an apple. They may be single but are more frequently multiple.

Microscopically, they are composed of adult epithelium and of fibrous connective tissue in varying proportions. They suggest the structure of cutaneous papillae. In fact, they have been

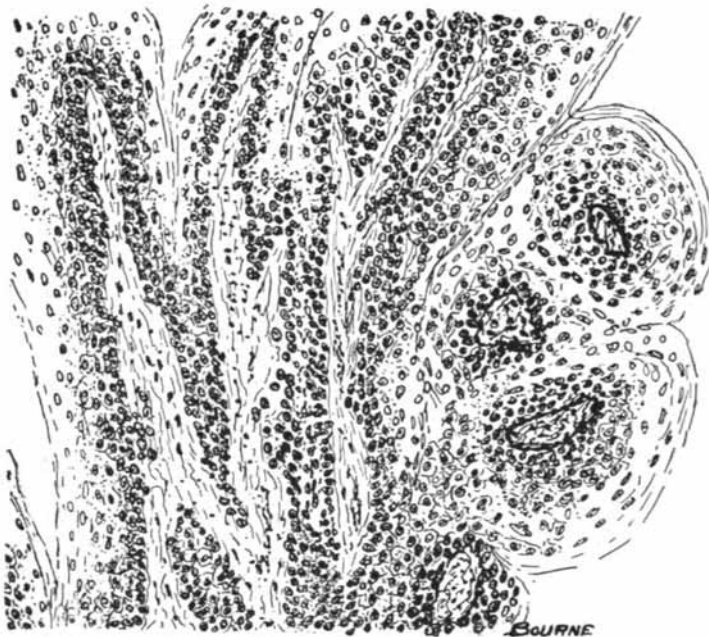


Fig. 174.—Section of Papilloma from Oesophagus of cow, showing bands of stroma covered by epithelium.

described as hypertrophied papillae. The fibrous tissue is the supporting structure or framework of the tumor and contains the blood vessels and nerves when they are present. The epithelium is the covering mantle of the fibrous tissue. In the hard papillomata the epithelium is stratified and the surface cells are cornified. In soft papillomata the epithelium may be single or stratified but the surface cells are not cornified. The proportion of fibrous tissue and epithelium in papillomata may be the same

as in normal papillae or the fibrous tissue or the epithelial tissue may be in excess. Hence some papillomata are apparently sub-epithelial fibromata and others are masses of epithelial cells upon a very limited fibrous matrix. Papillomata have the same relation to underlying structures that normal papillae have. The stroma of the papillomata has a definite connection with the dermis in cutaneous papillomata and the epithelium apparently originates from the lower layers of the epidermis. Transverse sections appear as areas of stroma surrounded by epithelial cells, while epitheliomata are composed of columns of cells surrounded by a stroma.

These tumors are essentially benign. They may result fatally because of mechanical interference, as in the occlusion of the oesophagus or the urethra. They may undergo necrosis, thus providing an entrance for infection and result in fatal septicemia. Papillomata do not form metastases, but they are frequently multiple. Cases have been recorded where the condition papillomatosis has been transmitted from one animal to another. By constant irritation some epithelial cells may become enlarged in the subsurface, thus providing a centre from which an epithelioma may develop. They respond to medicinal treatment and surgical interference.

EMBRYONIC EPITHELIAL TUMORS.

This is a group of tumors composed of embryonic epithelial cells, and for description may be divided into three varieties,—(1) carcinoma, (2) epithelioma, and (3) adenoma.

Carcinoma is an epithelial tumor characterized by the grouping of cells into nests or alveoli. They are of rather common occurrence but not as common as sarcomata. Horses and mules, cattle, sheep, hogs and dogs have been observed affected with carcinomata. These tumors have no selective action for any tissue. They have been found affecting mucous membranes, glandular structures, invading muscles and even in bone. They are usually diffuse, although they may be limited by a membrane resulting from reaction of the surrounding tissue. They are usually soft (encephaloid), but they may be quite hard (scirrhous), depending upon the amount of stroma or fibrous tissue contained. The color of a cut section of a carcinoma is usually gray, dirty-white or pale pink. They may be mottled because of degenerating or necrotic centers or hemorrhage. Lobules may be observed, especially in those carcinomata formed by the cel-

lular infiltration into dense areolar tissue. Small blood vessels may be present, but the blood supply is usually very limited and the vessels occur only in the stroma.

Microscopically, these tumors are found to consist of embryonic epithelial cells arranged in nests, the cells having no intercellular substance between them. The cells are variable in size and in shape, they may be squamous, spherical or columnar. The nucleus is usually much smaller in proportion to the size of the cell than the nucleus of sarcoma cells. The stroma is usually

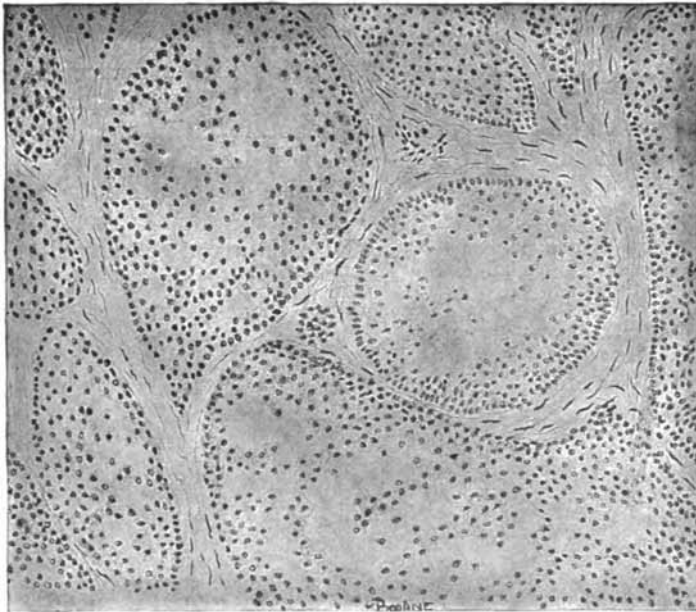


Fig. 175.—Section of **Maxillary Carcinoma** of a horse, showing the nests of epithelial cells surrounded by a stroma.

appropriated from the pre-existing tissue and therefore is variable in quantity and structure. In some cases sarcomatous tissue constitutes the stroma. The stroma forms alveoli in which the carcinoma cells occur. In fact, the alveoli are, in many instances, simply dilated lymphatic spaces which have been invaded by carcinoma cells. Lymph is usually quite abundant and bathes the nests of the carcinoma cells in the alveoli. Because of the freedom of anastomosis of lymph spaces and the constant flow of lymph, carcinoma cells are easily and rapidly diffused. Karyokinetic figures are of common occurrence in rapidly growing carcinomata. There is usually an inflammatory reaction accom-

panied by a leucocytic infiltration in the adjacent tissue. In rapidly growing carcinomata the cells frequently completely obstruct the flow of lymph through the alveoli, resulting in degeneration or necrosis. Mucoïd degeneration is perhaps the most frequent variety, thus producing a mucous mass.

Clinically, these tumors are malign. They are not circumscribed, hence their extirpation is practically impossible. In fact, surgical interference usually stimulates them to more rapid development, and, in addition, opens an avenue for infection. They

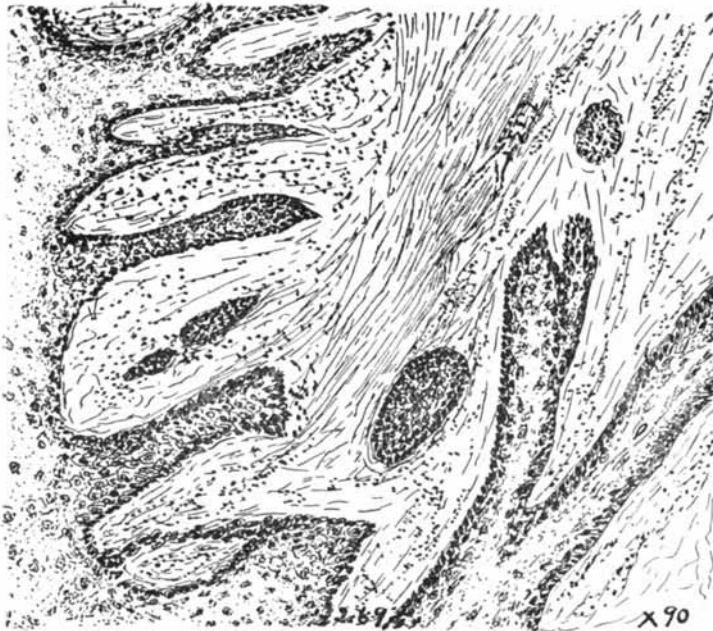

Fig. 176.—Section of an **Epithelioma** of the hock of a horse: was the sequel of an injury. Note the ingrowth of the columns of epithelial cells.

form metastases. The metastatic tumors usually occur in the first lymphatic gland that the lymph passes through from the area affected with the carcinoma. Then by metastasis they will be extended on to the next group of glands and finally reach the blood stream and form carcinomatous emboli in the lungs, liver, etc.

These tumors should be differentiated from alveolar sarcomata, endotheliomata and papillomata. The sarcoma has a much larger nucleus in proportion to the size of the cell and the cells are usually smaller than carcinoma cells. In a cross-section of a

papilla from a papilloma the cells will be found arranged around the stroma instead of in nests as in carcinoma.

Carcinomata are sometimes associated with other tumors as fibromata and chondromata, but they are more frequently in combination with sarcomata, in which the sarcomatous tissue forms the stroma of the carcinoma. The sarcoma cells are usually of the spindle-celled variety.

Epithelioma.—This type is the result of an ingrowth of epithelium into the underlying structures and has been classed by some as a sub-variety of carcinomata. In this variety of tumors

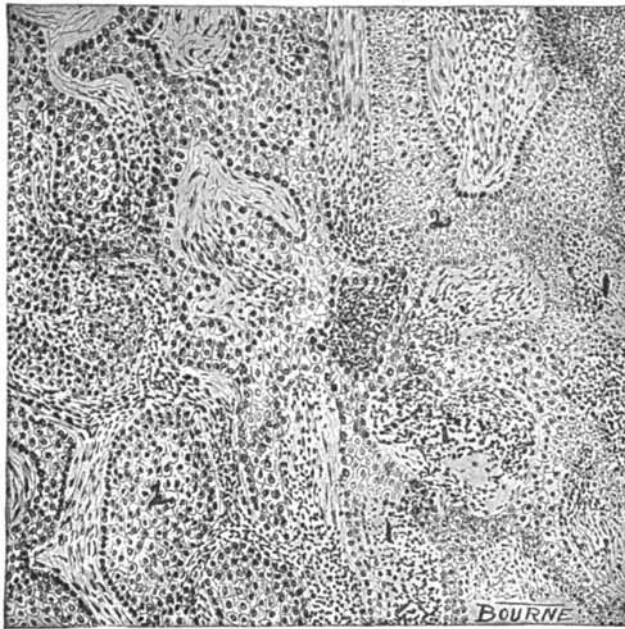


Fig 177.—**Epithelioma** from eye of an ox.

there is considerable evidence that they are secondary to surface injuries. A horse with a large fungoid growth beneath the left eye was sent to a Kansas City veterinarian for treatment. The history of the case brought out the fact that the tumor was the sequel of a wire cut. Two similar cases of epitheliomata occurred in the eye of two cows after severe attacks of keratitis. Epitheliomata are not rare and may affect any of the domestic animals. They always occur primarily in relation to epithelial surfaces. The surface is usually denuded and there is usually an acrid, fetid discharge. They may appear as elevated nodular

masses or as ulcerated surfaces and are rarely encapsulated. Their consistency varies with the amount of connective tissue stroma present. Their color is usually white or gray, although it may be quite variable as a result of degeneration or necrosis. The quantity of blood depends upon the vascularity of the tissue invaded.

Microscopic sections of epitheliomata are usually very similar to carcinomatous sections, indeed, it is sometimes impossible to differentiate them from carcinomata. In the beginning of the tumor formation, if sections are made perpendicular to the sur-

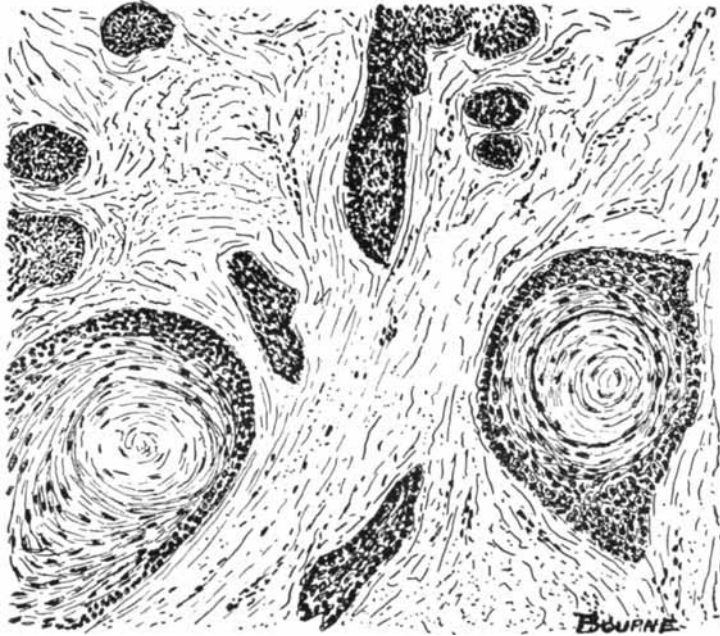


Fig. 178.—Section of a pearl cell Epithelioma of the Subcutum of a 14-year-old dog, showing pearl cells and columns of epithelial cells.

face, the ingrowing epithelium will be observed as columns of cells. These cell columns extend into the areolar lymph spaces and are then distributed the same as in carcinomata, the pre-existing tissue stroma becoming the stroma of the tumor. The presence of the epithelial cells or their katabolic products sometimes produces a chronic inflammation of the stroma. The pressure produced from the thickened stroma upon the columns of epithelial cells may result in the formation of "pearls." Epitheliomata containing the "pearls" are designated pearl-cell epitheliomata.

Clinically these tumors are not as malignant as carcinomata proper, and they have less tendency to form metastases. They are frequently completely destroyed by surgical interference.

Adenoma.—This is a glandular tumor. While it is similar to a gland it is functionless or has a perverted function. Though occurring more frequently in glands, as the kidney, mammae, mucous or sebaceous glands, testicle, liver, etc., they may occur in any tissue. Swine and dogs are most frequently affected with them. They are usually circumscribed, rather firm, nodular, white or grayish-white masses, varying in size from a pea to a

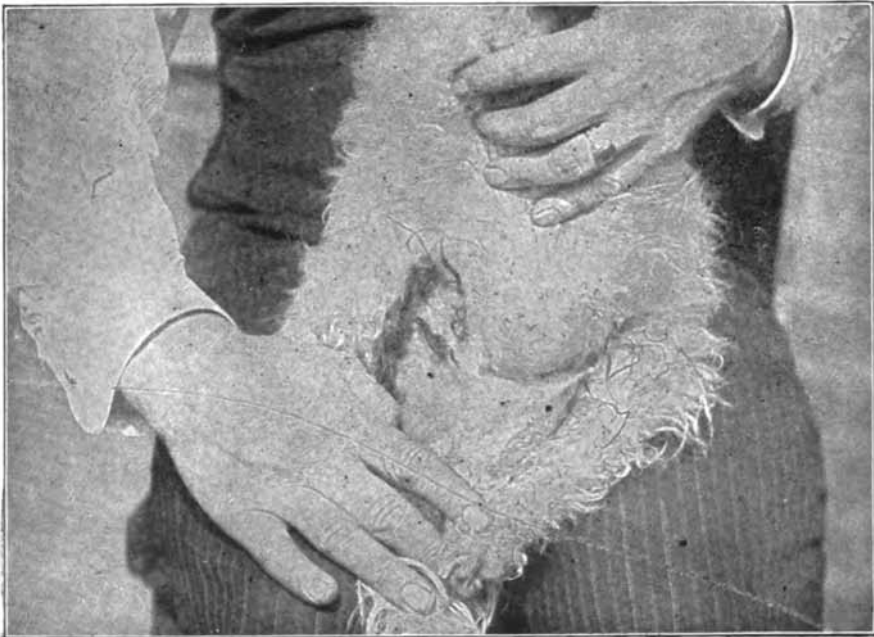


Fig. 179.—Photograph showing Mammary Adenoma of a bitch.

man's head. In section the gross specimen usually appears lobulated, and, if the tumor is large, there are usually necrotic centres here and there through it. The blood supply is limited, the vessels usually being obstructed by the pressure of the new-formed adenomatous tissue.

In microscopic sections glandular cells are found in various arrangements as tubules, acini, etc. The mimicry, however, is not complete, and there is usually little difficulty in differentiating adenomata from normal gland tissue. The cells vary in shape from short cubical to tall columnar. They are usually

arranged in a single layer, although the tubules or acini may be entirely filled with cells arranged layer upon layer. The type of cells adheres to the description given in discussing carcinoma.

The stroma is usually composed of fibrous connective tissue and is variable in amount. Blood vessels are found within the stroma. The cells lining the acini may be active and the secretion is frequently retained, thus resulting in a cyst-adenoma. The accumulated secretion may cause degeneration of the stroma, and the acini rupturing one into another produce a large cyst.

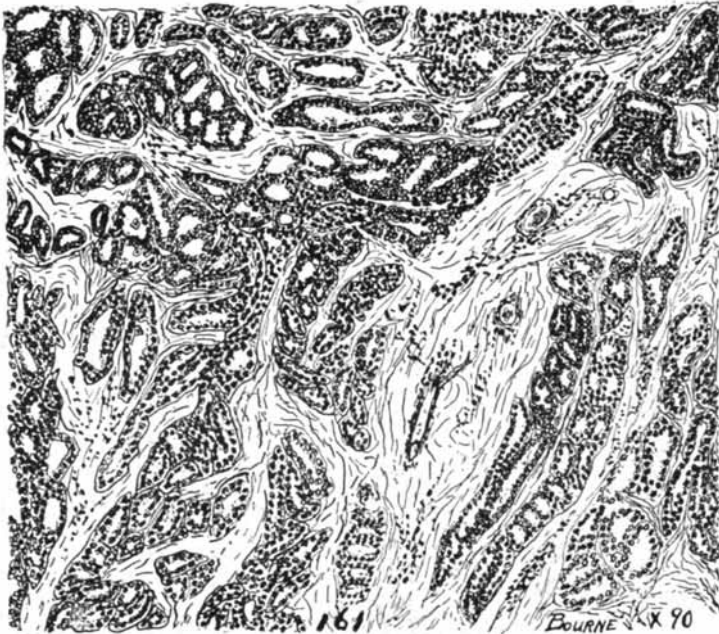


Fig. 180.—Section of an Adenoma from the frontal sinus of a mule, showing the arrangement of tumor tissue into acini and tubules.

Clinically these tumors, as a class, are malignant, but do not produce fatal results as rapidly as carcinomata. Many individual adenomata are benign. A horse's tail was recently amputated that for three years had been affected with an adenoma of the sebaceous glands. A bitch affected with an adenoma of the mammary gland has been under observation for two years and is normal except for the presence of the tumor. These tumors rarely recur when removed. From experience it has been found that mammary adenomata of the bitch usually result fatally immediately after operation. (The operation appears to produce

sufficient shock to destroy life.) Adenomata are extended by means of the lymph. Various combinations of adenomata are common.

Adeno-Sarcoma.—This is a tumor composed of adenomatous and sarcomatous tissue. These tumors are seldom observed during life because they occur in the kidney, and it is not an easy matter to palpate the kidney in the domestic animal unless there is extreme emaciation. They usually affect only one kidney. They occur in young animals and are most common in the hog although one has been observed in a horse. These tumors grow rapidly and may become very large. Day reported one that weighed 27.2 kilograms (60 lbs.) found in the kidney of a hog.

Renal adenosarcomata usually have their origin near the kidney pelvis. The renal tissue is gradually displaced by the tumor, and in some instances the kidney tissue is entirely destroyed as a result of pressure atrophy. The tumors are usually confined to the kidney, but they form metastases, in the lung (through the blood, or in the sublumbar lymph nodes (through the lymph.)

In gross appearance, these tumors are irregular in outline. They are usually surrounded by a thin fibrous capsule from which fibrous bands project into the tumor dividing it into

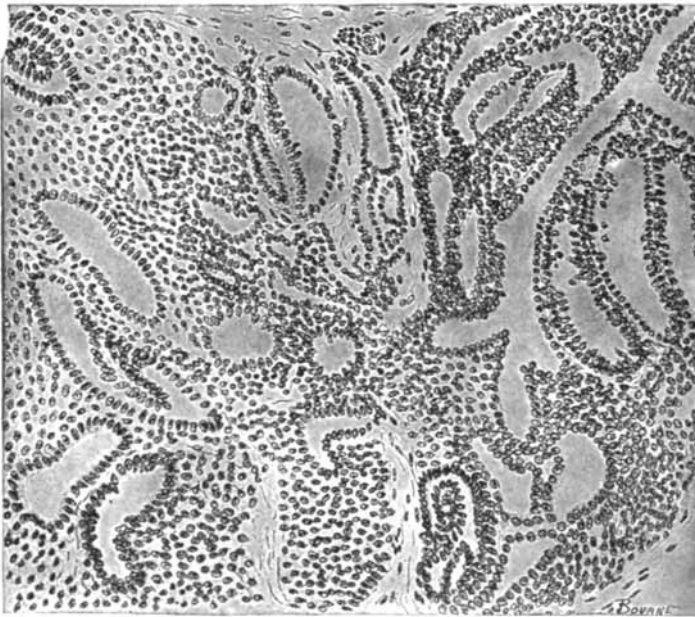


Fig 181.—Section of an **Adeno-Sarcoma** of the kidney of a hog, showing the sarcomatous tissue between the acini and tubules.

irregular lobes. These tumors are usually mottled, though they may be uniform and of a white or light gray color.

Microscopically, adenosarcomata are composed of epithelium and connective tissue. The amount and arrangement of the two types of tissue are variable. Some areas may be entirely epithelium (adenomatous) and other areas connective tissue (sarcomatous). The epithelium is arranged as grandular tissue, the tubes and acini of which are irregular in shape and size and may contain disintegrating, epithelial cells or their products. The epithelium is usually arranged in a single layer in the tubes and acini though they may be grouped in some instances and

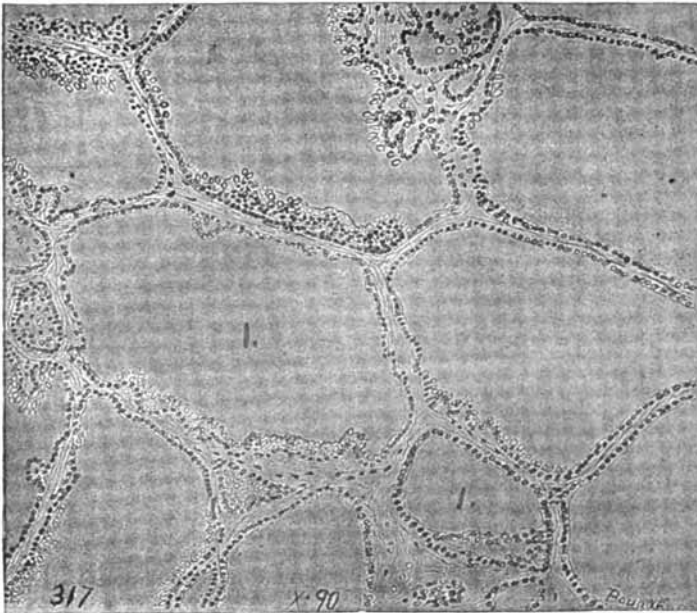


Fig. 182.—Section of a **Cystadenoma** of the mammary gland of a sheep, showing:
1. Conglutinated cystic contents surrounded by an atrophied acinous wall.

thus appear similar to carcinomatous nests of cells. The epithelial cells are small and usually contain finely granular chromatin. The connective tissue cells are usually fusiform although they may be nearly spherical in shape. They contain relatively large nuclei in which granules may be observed.

Cystadenoma is also common, especially in those adenomata that produce secretion. They are found in the adenomata of the mammary and sebaceous glands.

Hypernephroma are tumors which may be classed either with

sarcomata or carcinomata and is composed of tissue similar to adrenal tissue. They occur most frequently in the kidney, ovary, or adrenal body itself. Hypernephromata are rarely diagnosed as such in living domestic animals. They are variable in size, frequently weighing as much as five kilograms (11 lbs.) Usually gray in color and invariably containing hemorrhagic areas they thus appear mottled. There is usually an encapsulating membrane present. Blood-vessels are numerous, especially in the stroma. Degeneration and necrosis is of common occurrence.

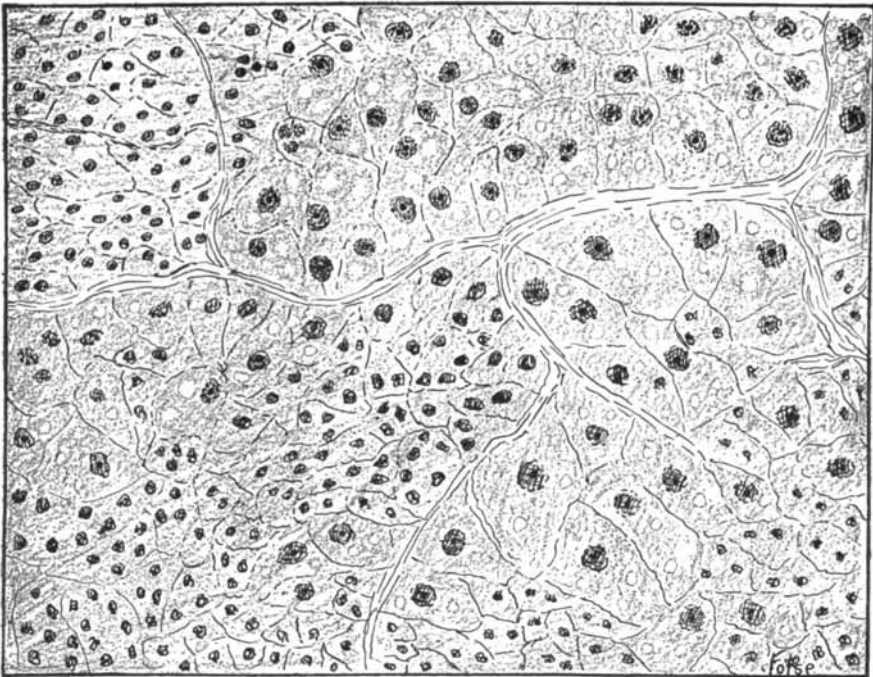


Fig. 183.—Hypernephroma of the kidney of an ox, showing large, typical hypernephromatous cells containing fat droplets. X 250

Microscopically, these tumors are found to be made up of large cells similar to epithelial cells and usually containing fat droplets. These cells are arranged in rows or columns, the columns being separated from each other by a small amount of stroma. The columns of cells may be quite variable in their diameter, appearing at times as long, slender columns and again as rather long nests of cells. The stroma is composed of fibrous connective tissue and contains many blood-vessels.

Clinically, these tumors are very malignant, and, although

they are encapsulated, they form metastases through the blood. They usually result fatally in the human, even after operation, probably because of the liberation of considerable of the adrenalin substance which increases blood pressure to such an extent that heart failure supervenes.

PLACENTOMA.

(Syncytioma.)

A placentoma is a tumor composed of tissue similar to the chorionic villi.

These tumors have been described under a variety of names as syncytioma malignum, deciduoma malignum, chorio-epithelioma, epithelioma seritonale, chorio-carcinoma. Only recently have placentomata been recognized as distinct tumors.

A placentoma is essentially a tumor of the uterus. They are not common in domestic animals but this may be because of failure to recognize them. The uterus or fallopian tube is their most frequent location. They occur more frequently after spurious or mole-pregnancy and usually appear a short time after parturition. Abortion is a predisposing cause. The primary tumor almost invariably occurs in the uterus though a few cases have been reported in women in which the primary tumor was in the kidney. They are very malignant.

These tumors appear as soft, spongy, villous, bleeding masses and are variable in size. They have the general appearance of placenta or foetal membranes in both the primary and the metastatic tumors. They begin to develop at the cotyledons or zone of placental attachment and rapidly extend into the uterine muscular tissue and invade blood vessels, thus metastases occur in a short time after the tumor appears. Because of their structure (embryonic cells and rich vascular supply) they grow rapidly.

The presence of a placentoma is indicated by uterine hemorrhage occurring a few days after normal parturition or abortion. The uterus is enlarged and the affected individual rapidly becomes anemic and emaciated. The uterine discharge usually contains shreds of the tumor and the cavity of the uterus is occupied with a soft bleeding mass.

Microscopically, these tumors are composed of a protoplasmic ground-substance, which is arranged in an irregular network forming alveoli. The protoplasmic mass is usually continuous, there being no evidence of cell partitions, and it contains many nuclei thus forming a syncytium. Within the alveoli of the pro-

toplasmic mass occur many small variously shaped cells. Blood cavities and canals are abundant and hemorrhagic areas are not uncommon.

TERATOMA.

These tumors are composed of the different kinds of tissues that approximate the structure and arrangement of normal tissue so closely that it is difficult to differentiate them macroscopically or microscopically from normal tissues and organs. Teratomata are so closely related pathologically to malformation, that in some cases it is impossible to determine which condition exists. Structurally they are found to be composed of either embryonic or adult tissues. Cutaneous structures are the most frequent tissues observed in this class of tumors, although tissues of bone, muscle, intestine, rudimentary eyes, brain, etc., have been found in them as well as sarcomatous and carcinomatous tissue.

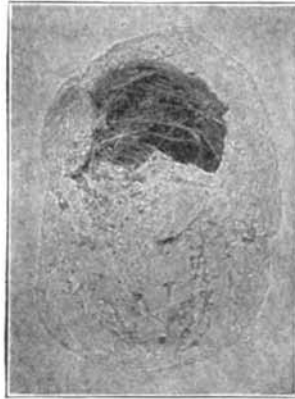
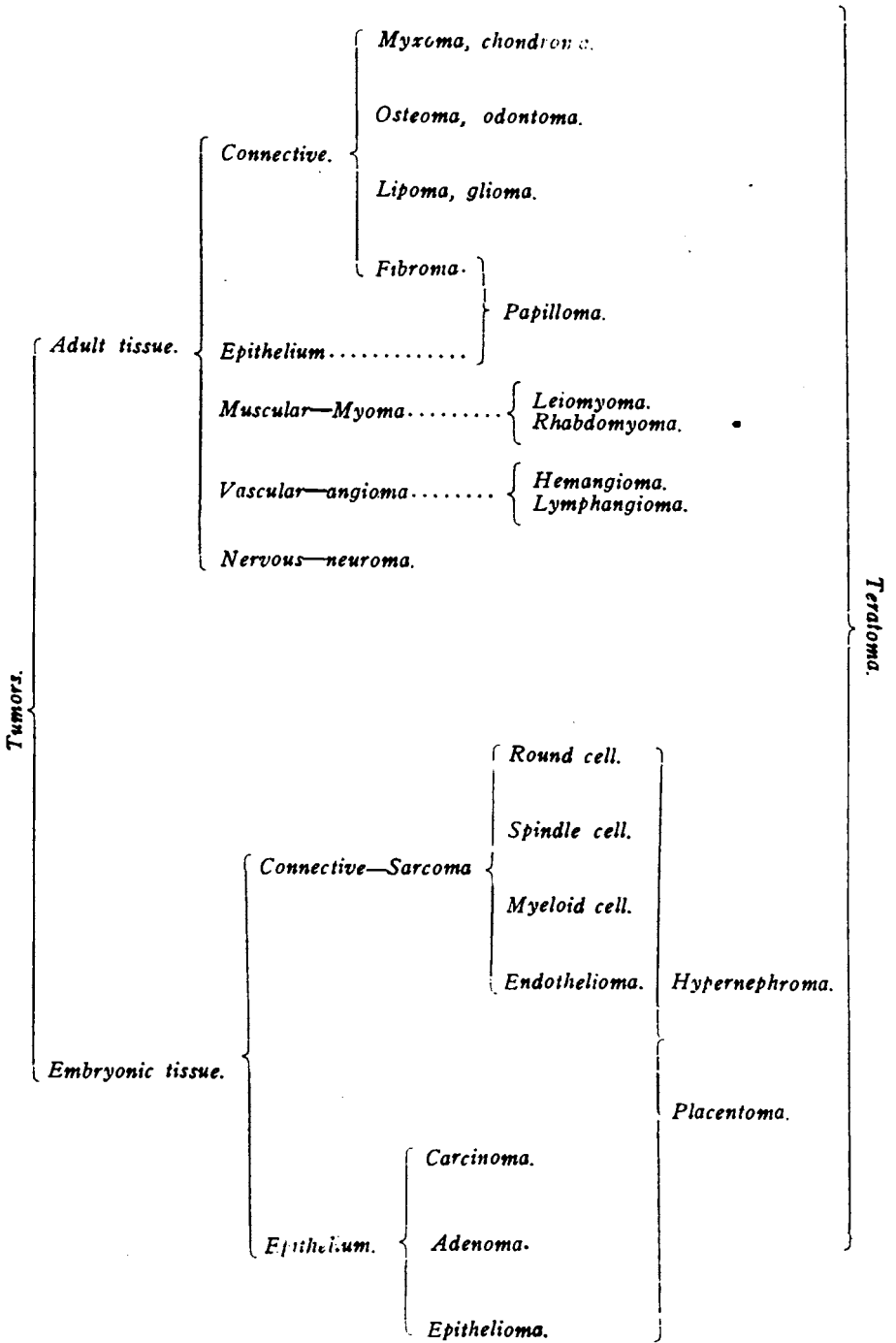


Fig. 184.—Dermoid Cyst from the withers of a horse.

These tumors are quite variable in size, shape and color. In consistency, they vary from a viscid mass to dentine and enamel. They are usually single, grow slowly and rarely form metastases, although a few have been observed that grew rapidly, metastasized and recurred when removed. They frequently undergo degeneration tending to cystic formation. Clinically, teratomata are benign, only rarely terminating fatally.

Etiologically, they are as mysterious as the other types of tumors. They may have their origin from tissue inclusions. Some teratomata may succeed imperfect tissue union. The the-

TABLE I.



ory of parthenogenesis may be applicable in the explanation of some of them, but the specific cause or causes of teratomata has not yet been determined.

Teratomata are of frequent occurrence in all domestic animals but are more prevalent in equines. They are found in any tissue and in all parts of the body although they are more frequent in the skin, ovaries, testicles, kidneys and parotid glands.




Fig. 185.—Dermoid Cyst from eye of a steer, showing tuft of hair growing upon cornea.

Because of the heterogenous structure of teratomata they are difficult to classify.

Dermoid cysts are teratomata composed primarily of skin and its appendages (hair, sebaceous glands, horn, teeth, etc.) They may be solid, but are more frequently cystic. In size they vary from a pea to a basket ball. There is usually surrounding them a dense capsule from which a villous mass may be ob-

served projecting into the cyst cavity. Extending from the villous projection are tufts of hair or teeth. The villus is, in structure, very similar to skin. In some teratomata hair and teeth are produced directly from the inner portion of the cyst wall. Cystic dermoids usually contain hair and a pultaceous material derived from the sebaceous glands or they contain teeth and a viscid fluid. Dermoid cysts without any capsule are occasionally observed. The accompanying cut illustrates hair extending from the anterior surface of the eye. Those found in the ovaries



Fig. 186.—Dentigerous Cyst on left inferior maxillary of 3 years old colt containing 431 teeth. Removed Dec. 11, 1905, by H. M. Stevenson, Perry, Iowa.

usually contain elements of all three germ layers. Those of the testicles may contain vestiges of all the germ layers, but are usually cystadenomatous or cystocarcinomatous in type although they may contain cartilage, teeth, osseous tissue, etc. Solid dermoid cysts are a heterologous mass, of embryonic or adult tissue.

Dentigerous cyst is the name applied to those dermoid cysts containing teeth. These are the most important to the veterinarian because they are of the most frequent occurrence. They are invariably encapsulated and may or may not contain a villus

projection. The teeth vary from an irregular conglomerated mass of dental tissue to those perfect in form and structure. The constant production and accumulation of the containing viscid fluid results in enlargement of the cyst and frequently rupture of the capsule and the production of a fistula. The most frequent location of dentigerous cysts is near the base of the ear in the region of the parotid gland although they may occur in any other place especially in the ovary and testicle. They are most common in horses.

Cholesteatoma is a teratoma composed of pearl like masses of epithelium in which there is more or less cholesterin. They are not common but have been observed in the brain, (choroid plexus and tuber cinereum) and urinary organs. There was recently obtained from near the kidney of an ox, a mass of substance of a waxy consistency, that gave the typical reaction of cholesterin and was probably a cholesteatoma.

CYSTS.

DEFINITION.

ETIOLOGY.

Retained secretion.
Obstructed outflow.
Excessive production in ductless glands.
Retention of hemorrhagic extravasate.
Colliquation necrosis.
False bursae.
Parasites.

STRUCTURE.

VARIETIES.

Retention; Atheroma.
Exudation; Hygroma, Shoe boil, Capped hock, Meningocele.
Extravasation; Hematocele, Hematoma.
Degeneration; Colliquation necrosis, Hydatiform
Parasitic; Echinococcosis, Measley pork.
Dermoid; Cutaneous, Dentigerous

SECONDARY CHANGES.

EFFECTS.

A cyst is a bladder like growth surrounded by a capsule and containing a liquid, semiliquid or gelatinous material. Cysts are not true tumors. However, a tumor may become cystic, (Cystoma,) and the capsule surrounding a cyst may proliferate and become a true tumor. Collections of inflammatory and oedematous fluids, are not usually considered as cysts. Cysts may be single or multiple. The latter are designated multilocular cysts.

Cause.--Cysts may be caused by, 1. obstruction of gland ducts, thus favoring accumulation and retention of a normal secretion

or excretion, e. g., renal cysts; 2. By excessive secretion into ductless structures, e. g., distension of bursae; 3. By extravasation into the tunica vaginalis sac, e. g., hematocele; 4. Liquefying necrosis, e. g., formulation of cysts in the cerebrum of horses affected with "blind staggers." 5. Parasites, e. g., *Cysticercus cellulosae*.

Structure.—The cystic wall varies according to the age of the cyst. In the beginning it may represent the original gland structure or a condensation of the normal tissue of the part. Later the cystic walls may be lined with epithelium or endothelium, which actively secretes as long as the cyst grows. The cystic capsule may be composed entirely of fibrous connective tissue. In some instances the primary capsule is fibrous and later an endothelial lining develops. The cyst wall or capsule may be

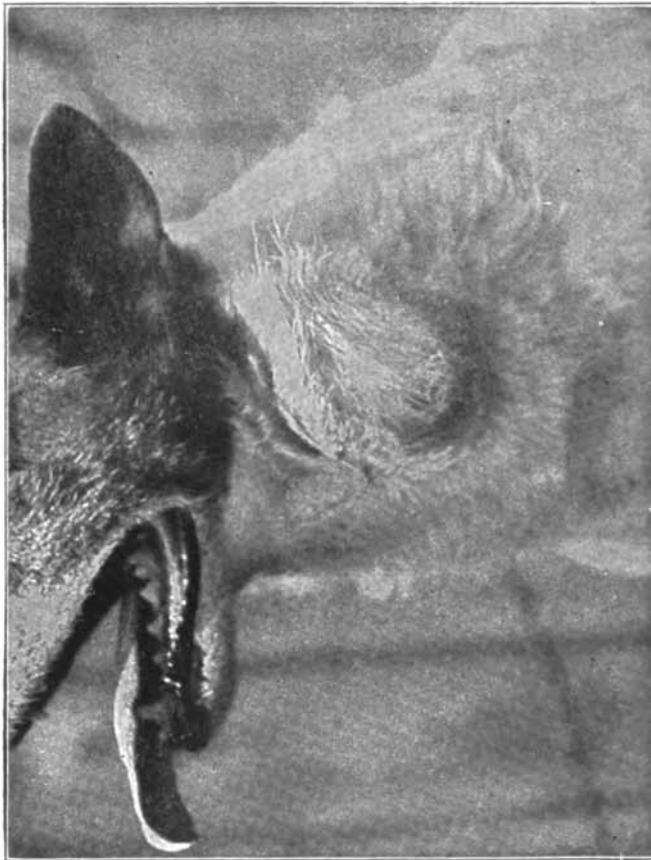

Fig. 187.—Retention Cyst in cervical region of dog.

firmly adherent to the adjacent tissue or it may be loosely attached.

The cystic content varies according to the nature of the cyst. Urine, milk, saliva, mucus, semen, liquor folliculi and other secretions and excretions are represented in cystic contents. Blood i. e., hemorrhagic extravasates and various tissues that have undergone colliquation necrosis may represent the contents of cysts. The various secretions, excretions, extravasates, exudates and necrotic tissue usually undergo some modification when retained within a cyst.

Varieties.—*Retention cysts*, those resulting from the accumulation and retention of normal secretions, e. g., ovarian cysts, renal cysts, mammary cysts, testicular cysts, ranulae, mucus cysts, sebaceous cysts (Atheromata).

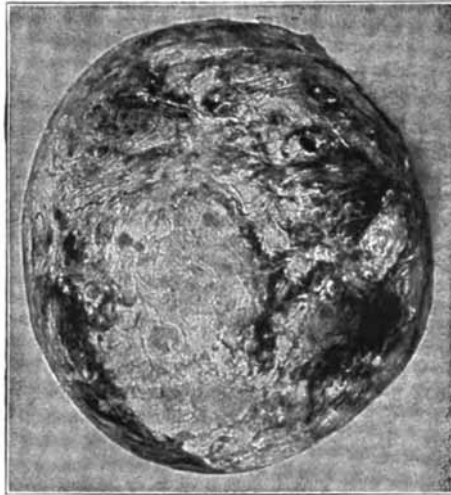

Fig. 188.—**Uterine Cyst** the capsule of which had become osseous.

Exudation cysts, those resulting from excessive secretion into ductless glands or cavities, e.g., hygroma, capped hock, meningocele.

Extravasation cysts, those resulting from hemorrhage into tissues or closed body cavities, e. g., hemocele, hematoma.

Degeneration cysts, those resulting from liquefaction of necrotic tissue, e. g. colliquation cerebral cysts.

Parasitic cysts, those resulting from the development of parasites in the tissue, e. g., cysticercus cellulosae, cysticercus bovis, cysticercus echinococcus, etc.

Dermoid cysts, those resulting from inclusion of cutaneous tissue. These have been discussed under the head of teratomata.

Secondary Changes.—The cystic wall may become the seat of inflammatory disturbances, neoplastic formation or necrosis. In some instances cysts are destroyed because of the disintegration of their capsule, by disease.

The cystic contents may undergo degeneration, become inspissated or calcified.

Effects.—The effects of cyst formation depend upon the tissue involved and the size and nature of the cyst. The cysts frequently become so large that the entire organ is destroyed, e. g., ovarian and renal cysts. In some cases the cysts may destroy life, especially if a vital organ, e. g., the brain is involved. Cysts may persist for years and be of no serious consequence, on the other hand they may seriously inconvenience the functional activity of the part involved and impair the health of the animal from the beginning.

CHAPTER XI.

FEVER

(Pyrexia).

DEFINITION.

ETIOLOGY.—*Toxins; ptomains; katabolic tissue products; drugs.*

PERIODS OR STAGES (Course).

Onset (Stadium Incrementi).

Acme (Stadium Fastigium).

Decline (Stadium Decrementi).

Convalescence.

VARIETIES, according to

Course.

Regular.

Irregular.

Duration and temperature variation.

Ephemeral.

Continuous.

Remittent.

Intermittent.

Severity.

Sthenic.

Asthenic.

SYMPTOMS.

Chill, diminished secretions, increased heart action and respiration, nervousness and restlessness.

LESIONS.

Parenchymatous degeneration, hemolysis, hyaline degeneration, loss of fat.

Body heat is a product of metabolism. The body heat or temperature of warm blooded animals is practically constant, although changed environment, diet and use or occupation produce some variations. Thus a horse confined in a barn has a temperature .5 to 1° F. higher than when not so confined, provided the diet is the same in both conditions. A narrow ration is conducive to increased oxidation and consequently a higher temperature. Animals in action have a higher temperature than when at rest. Thus a dog's temperature is from 1 to 4° F. higher immediately after than it is before a chase.

The accurate regulation of body temperature is accomplished by the action of the thermo-regulating center or centers. Tissue action is always accompanied by increased heat production, and frequently different parts of the same animal may vary 1 to 6° F. in temperature. The equalization of body heat and the distribution of heat to the different parts of the body is accomplished by means of the circulating blood. Heat is continually produced in the animal body and is constantly eliminated from the body

in the excretions (air, perspiration, urine and feces), as well as by direct radiation. The relative amount of heat dissipation by the excrements and by radiation varies in different animals.

Normal temperature is the balance of equilibrium maintained between thermogenesis (generation of heat) and thermolysis (dissipation of heat). The normal temperature of an animal used during the day is about 1° F. higher in the evening than in the morning.

Fever is a condition in which the equilibrium between thermogenesis and thermolysis has been overthrown, i. e., there is a disturbance of metabolism accompanied by increased temperature. It is not a disease but a symptom complex, common to several different pathologic conditions. Fever should be differentiated from heat stroke and sunstroke. In heat stroke there is no disturbance of thermogenesis or thermolysis, but the thermolytic centers are unable to cope with the existing external conditions, and there is accumulation of heat in the body, whereas fever is a result of disturbed equilibrium between thermogenesis and thermolysis. Sunstroke is a condition produced by the action of actinic or chemic rays of the sun upon the nerve centers, temperature variations being only a predisposing factor.

Etiology.—Fever is usually caused by bacterial products as toxins, endotoxins and bacterial proteids. Tissue products as leucomains, peptones and various albumins are also capable of producing fever. Certain therapeutic agents are causative factors of fever.

Course.—The course of a fever may be divided into four periods or stages, as follows:

Onset (stadium incrementi) is the period of increase between the time of normal temperature and the time that the tempera-

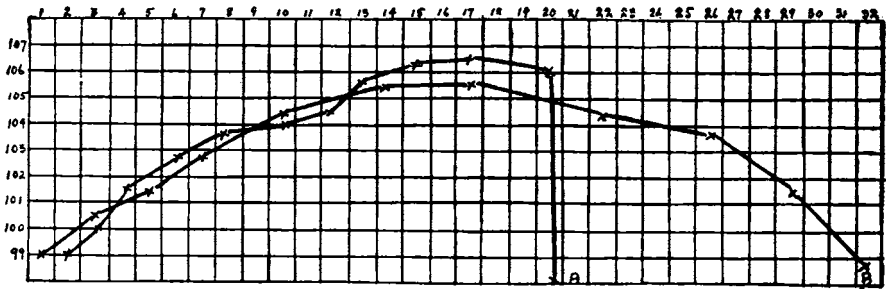


Fig. 169.—Charts showing two fever curves. On the left is given the temperature and on the top each number signifies one day or 24 hours. From 1 to 13 is the onset; from 13 to 17 and 20 respectively the Acme; from 17 to 32 is a gradual decline (lysis); and on 20 is shown a rapid decline (crisis).

ture reaches its **average height**. The length of the **onset and the temperature** during this period is variable.

Acme (stadium fastigium) is that period of time that the temperature remains high. It is the time from the termination of the onset to the beginning of the decline.

Decline (stadium decrementi) is the time extending from the termination of the acme until the temperature reaches the normal level. A sudden decline, i. e., when the temperature suddenly changes from acme to normal, is called crisis. In a **large** percentage of the cases of fatal equine pneumonia the temperature suddenly drops from the acme to normal, or even subnormal, the sudden change (crisis) causing death. Excessive variations, as a sudden rise of temperature or a sudden fall of temperature (may be to subnormal) are of rather frequent occurrence a short time before death and is called the moribund or premortal stage. A gradual decline from acme to normal is called lysis.

Convalescence is that period extending from the time that the temperature becomes normal until the animal has recovered. This period varies in length, a long continued fever essentially requiring a long period for convalescence. The temperature variation during this period is inconstant, but usually there is only slight fluctuation from the normal.

Varieties.—Fever may be classified according to course, to duration, and to temperature variation as follows:

According to the course fevers are regular and irregular, typical or atypical. A regular fever is characterized by the appearance of the various stages or periods of fever as described above. An irregular fever is one in which the stages are not distinct or are not regular in their appearance and duration.

According to duration and temperature variations, fever may be ephemeral, continuous, remittent or intermittent.

Ephemeral fever is of brief duration, usually lasting not longer than 24 hours. It is the type of fever observed in nervous, excitable animals. This variety of fever may be produced at will by some nervous women.

Continuous fever is that type in which there is a continuous high temperature. In continuous fever there are usually morning and evening variations the same as in the normal temperature. Croupous pneumonia without complications is an example of disease in which there is a continuous fever.

Remittent fever is characteristic of pyemia and is recognized by the irregularly periodic variations of temperature in which the temperature is always above normal.

Intermittent fever is the name applied to that type in which there are periodic variations, the temperature becoming normal between the fever periods. Intermittent fever is observed in equine pernicious anemia.

Fever may also be classified as: 1st. Sthenic. 2nd. Asthenic. Sthenic fever is active, vigorous and destructive. Asthenic fever has an insidious onset and is slow in action.

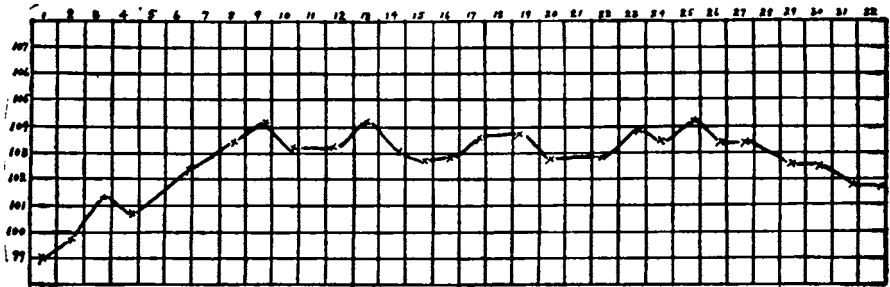


Fig. 190.—Continuous fever chart showing morning and evening variations, but a continuous high temperature.

Symptoms.—Fever is usually ushered in by a chill because of the constriction of cutaneous vessels which thus diminishes the temperature of the skin and produces the sensation of chilling. There are diminished secretions, as perspiration, saliva and urine. In long continued fever there is constipation because of absorption of fluid from the intestines. The pulse rate is usually

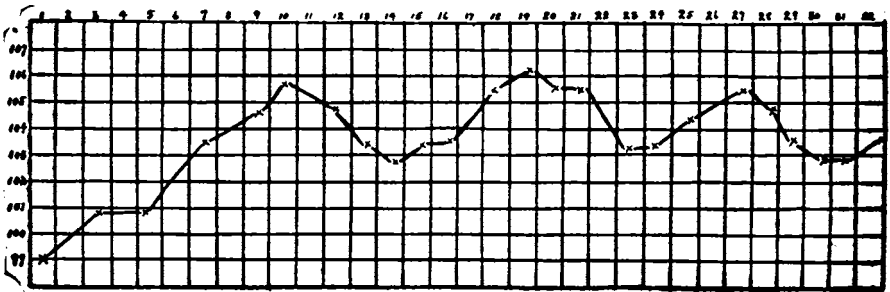


Fig. 191.—Remittent fever chart, showing variations in which the temperature is always above normal.

increased and its character is changed because of the action of katabolic products on the nerve centers. Respiration is increased probably because of an effort to eliminate large quantities of air and waste material, and thus there is a tendency for the temperature to be diminished. The affected animal is more or less nervous and restless.

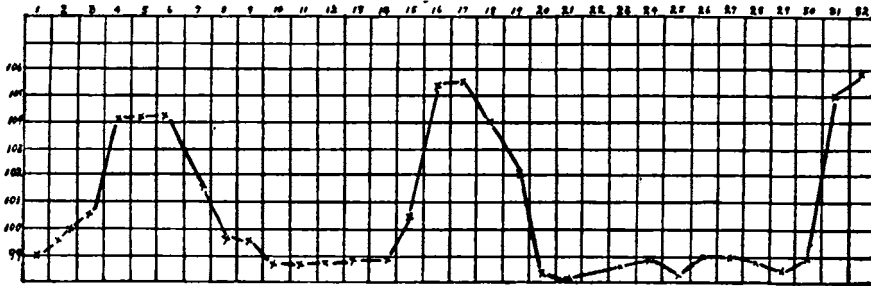


Fig. 192.—Intermittent fever chart in which there are periods of normal temperature.

Lesions.—All parenchymatous structures are affected with cloudy swelling, the extent of which depends upon the degree of temperature and its duration. Hemolysis is more or less extensive. Chronic or long continued fever usually causes hyaline degeneration, especially of the vessel walls. The affected animal rapidly diminishes in weight because of the consumption of fat.

CHAPTER XII.

INFECTIVE GRANULOMATA.

Infective granulomata embraces a group of specific inflammatory conditions characterized by the proliferation of endothelial cells, fibroblasts and other cells. Though the consideration of the following diseases belongs more properly to a discussion of infective diseases, their description will be of value to the student of general pathology.

TUBERCULOSIS.

Tuberculosis is a specific, infective disease, caused by the bacterium of tuberculosis affecting practically all of the higher animals and also some of the lower forms of animal kind.

Extent.—McFarland states that 14% of the deaths in the human family are from tuberculosis. It is probable that 25% of all humans have or have had tuberculosis.

The prevalence of animal tuberculosis is variable in different communities, the percentage depending upon methods employed for control and eradication under different sanitary laws, upon transportation rules and regulations and upon the conditions under which the animals are maintained. The exact percentage of tubercular animals in any country is not known, but the relative number has been determined by tuberculin testing and by post-mortem examination at abattoirs. In the United States the percentage, generally speaking, is low in comparison with other countries. According to the post-mortem findings of 7,621,717 cattle slaughtered in United States establishments having official inspection during the fiscal year beginning July 1st, 1906, and ending June 30th, 1907, 29,835, i. e., .4% were tubercular. This percentage is probably below the actual percentage, as dairy cattle are more extensively affected than beef cattle. The Secretary of Agriculture in his report for 1908 holds that 1% of beef cattle and 10% of dairy cattle are tuberculous.

According to the above report 2% is the estimated prevalence in the United States of tuberculosis among swine.

Porcine tuberculosis is apparently on the increase in the United States. In Germany it varies from 1-7%. Equine tuber-

culosis is not common in the United States, or at least only a few cases have been reported. Tuberculosis is usually found in those horses and mules that have been fed on tubercular cows' milk.

Tuberculosis of sheep is very rare and the disease is still less common in goats.

Dog and cat tuberculosis is not uncommon and is usually observed in pets of tubercular humans, although barn cats, especially those fed milk from tubercular cows, frequently become tubercular. (A dairy was recently inspected in which 68% of the cows were tubercular and on autopsy three barn cats also were found to be affected in a like manner.)

Tuberculosis of fowls is more prevalent in the United States

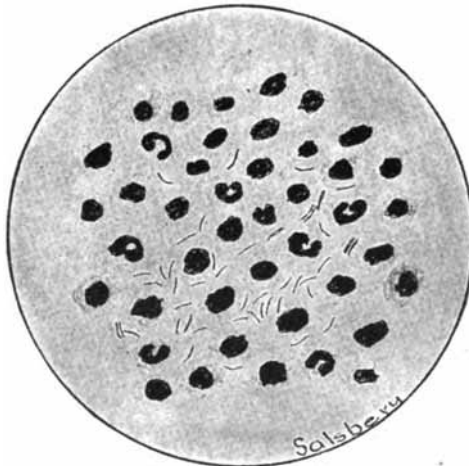


Fig. 193.—*Bacterium Tuberculosis Bovine.* Pus showing leucocytes and tissue shreds.

than is ordinarily suspected, although the percentage of affected birds is difficult of determination because there is at present no official inspection of fowls.

Etiology—Tuberculosis is caused by the *Bacterium tuberculosis*. This bacterium has rounded ends and is frequently slightly bent. It varies from 2 to 5 microns in length and from .3 to .5 in width. (These bacteria may appear as long, delicate, mycelial threads, branching forms, or even as a ray like fungoid growth, the form depending upon the environment. The pleomorphism of this micro-organism has caused some doubt as to its classification as a bacterium.) The *Bacterium tuberculosis* may occur singly or in pairs, and it is not uncommon to find several lying

side by side. They do not form spores, but they may contain granules and vacuoles, and they may have a beaded appearance because of fragmentation of their cytoplasm.

The Bacterium tuberculosis is extremely resistant to external injurious influences, probably because of a wax-like substance that constitutes about one-third of the body weight and forms the principal part of the external covering or capsule. (These bacteria are stained with difficulty but when once stained retain their stain even though subjected to the action of alcohol and acids.) The staining peculiarities are probably due to a fatty substance they contain.

Source of infection.—The bacterium tuberculosis may be transmitted direct from tubercular to healthy animals, but infection is more frequently obtained from foodstuffs, or barns, feed racks, watering troughs, posts, soil, etc. Tubercular animals are almost constantly eliminating the bacterium which contaminates everything that the tubercular discharges contact. The cadavers of tuberculous animals are usually deposited in the soil, and, in many instances, the proper precautions are not taken to destroy the infecting micro-organism. Infected manure is spread upon the soil and thus it becomes infected. The various crops, including hay, grown upon a tubercular infected soil, may be contaminated with the Bacterium tuberculosis and infect susceptible animals that consume such food. Sometimes the carcasses of animals dead of tuberculosis are thrown into rivers or creeks, thus infecting the water. The waste products of many small slaughter houses are fed to hogs and this affords opportunity for them to become infected. Skimmed milk and whey from creameries and cheese factories are also sources of tubercular infection.

Channel or avenue of entrance of the infection.—The Bacterium tuberculosis may gain entrance into the tissues of a healthy, susceptible animal through the mucous membranes or through abrasions of the skin, though the latter mode of infection is not of common occurrence in domestic animals. Cutaneous infection is occasionally observed in the mammae of sows and in the castration wounds of barrows.

From clinical and experimental evidence and autopsy lesions observed in abattoirs, it seems evident that the digestive tract is the principal channel of entrance of the Bacterium tuberculosis in hogs, cattle and fowls. It was originally erroneously concluded that the presence of pulmonary tubercular lesions was positive evidence that the infection had gained entrance through the respiratory tract. Tubercular free experimental animals fed

foodstuff contaminated with the *Bacterium tuberculosis* have frequently become affected with primary pulmonary tubercular lesions. (The possibility of inhalation of the infection was carefully guarded against in these experiments.) It is presumed that the *Bacterium tuberculosis* is incorporated by leucocytes in the digestive tube and that the leucocytes then pass through the intestinal wall into the lacteals and thence to the thoracic duct to the right heart and on to the lung, the first capillary system encountered, where they may lodge and establish tubercular foci. No doubt the respiratory tract is the channel of entrance in some cases of tuberculosis, but the number of animals infected through this channel is very small.

An occasional case of tuberculosis may be the result of infection through the genito-urinary organs. Thus the penis of a bull may become infected by serving a cow afflicted with uterine or vaginal tuberculosis, and this same bull by copulation may infect other cows. Tubercular lesions are occasionally observed in the superficial inguinal glands of steers, and this may be the result of infection in the castration wounds.

Conjunctival infection may occur as a result of forcible discharge of infection from the respiratory tube of an affected animal.

In summarizing, the digestive, respiratory, cutaneous abrasions, and genito-urinary organs are the principal channels of entrance of the *Bacterium tuberculosis*, the frequency being in the order mentioned.

Lesions.—The characteristic lesion of tuberculosis is the tubercle. A tubercle is a nonvascular nodule, composed of leucocytes, endothelial, giant and connective tissue cells, with a tendency for the central part of the nodule to undergo necrosis. The lesion may vary in animals of different genera and in different animals of the same genus. Thus tubercular lesions in hogs may differ in some particular from those in cattle because of variations in the resistance of the hog and ox. Variations of the tubercular lesions in different individuals of the same genus occur because of variation of individual resistance of the infected animal and variation of the virulency of the infecting organisms. Tubercular lesions may be modified or obscured by lesions resulting from secondary infections. The initial or primary lesion may occur in any tissue or organ. Lymphoid tissue, however, is more frequently affected than any other.

The *Bacterium tuberculosis* and its products are the etiologic factors in the formation of a tubercle. The bacterium having lodged in a tissue favorable for its growth and development, be-

gins to multiply and to eliminate those products that stimulate the surrounding connective tissue and endothelial cells to increase in number, and, at the same time, exerts a positive chemotactic action upon leucocytes. If the influence of the bacterial products is exerted upon the connective tissue and endothelium, the resulting tubercle will be composed of connective tissue cells and endothelial cells, and if the influence of the bacterial products is of a chemotactic nature, the tubercle will contain leucocytes.

Structurally, a young tubercle consists of a cellular focus infected with varying numbers of the *Bacterium tuberculosis*. As

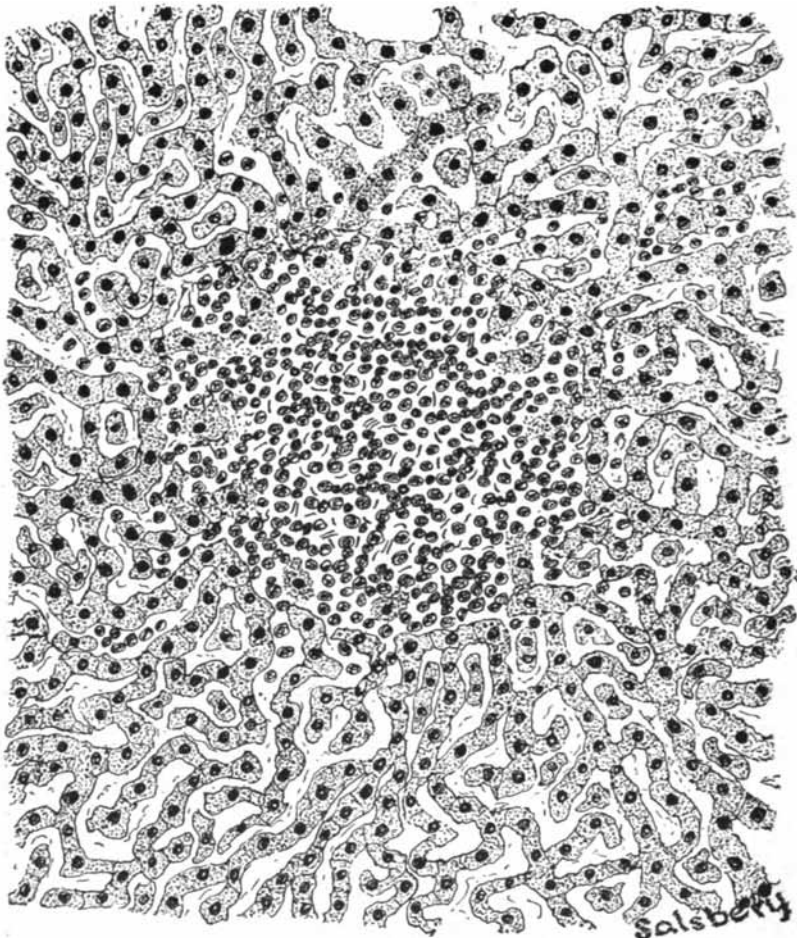


Fig. 194.—Small cellular tubercle; liver, x500. Showing small round cells with tubercle bacilli scattered here and there, also a few partially destroyed hepatic cells.

As the bacteria multiply the quantity of their products is increased, and these stimulate cellular multiplication and accumulation, and thus the tubercle grows. The formation of a tubercle constitutes a tissue reaction, but there is no vascularization; that is, no new blood vessels are formed, and the existing capillaries in the invaded tissues are finally obliterated. A tubercle is, therefore, strictly non-vascular, although in the very beginning the affected zone may be hyperemic. Cells constituting a tubercle obtain nutriment from adjacent tissues by absorption. Tubercles grow by multiplication of the peripheral cells, the central cells becoming degenerated after they have consumed all available nutrition. The structure and appearance of a tubercle varies according to its age, thus: a tubercle in the very early stages is a cellular mass, a little later the central portion of the cellular mass becomes necrotic, and at about the same time a median zone, consisting of bacteria, endothelial, and, in some cases, giant cells, becomes evident; the outer zone is the active zone and is composed of bacteria, connective tissue cells and leucocytes. As the tubercle becomes larger the necrotic zone extends to the median and outer zones toward the periphery. Necrosis is usually evident in tubercles that have attained the size of a pea. The central necrosis is primarily of the coagulation type, but the coagulated necrotic tissue may become liquefied, always becomes caseous and usually calcified according to the quantity of fluid contained. The calcification may be limited in extent, the necrotic tissue containing small calcareous particles that cause the necrotic tissue to have a "gritty feel," or it may be so extensive that the tubercle cannot be dissociated except by the use of a sledge. Liquefied tubercular necrotic tissue (pus) is yellowish in color in the ox, dirty white in hogs and yellowish in fowls. It is not sticky, although it becomes quite thick and is finally caseated.

Tubercles may vary in size from a microscopic point to large masses. All tubercles are small in the beginning and are usually entirely cellular. Small cellular tubercles in which there is no necrosis are designated miliary tubercles. Miliary tubercles appear as minute, grayish, translucent, pearl-like specks or nodules. If all the lesions in an affected animal are miliary in character, the disease is termed miliary tuberculosis. Miliary tuberculosis is most common in hogs.

The appearance of a tubercle changes when central necrosis begins. The color of caseous and calcareous tubercles varies from a dirty white to a yellow color. The tubercles may or may not be encapsulated. The capsule of a tubercular lesion is rela-

tively thin, though it is tough. Secondary tubercles may develop from a primary tubercle, and daughter tubercles may develop from a secondary tubercle, thus are produced the irregular nodular tubercular masses. The tissues contiguous to a tubercle are ischemic, probably because of the enfringement of the affected areas with lymphoid cells.

Little difference is noted in tubercular lesions in the various

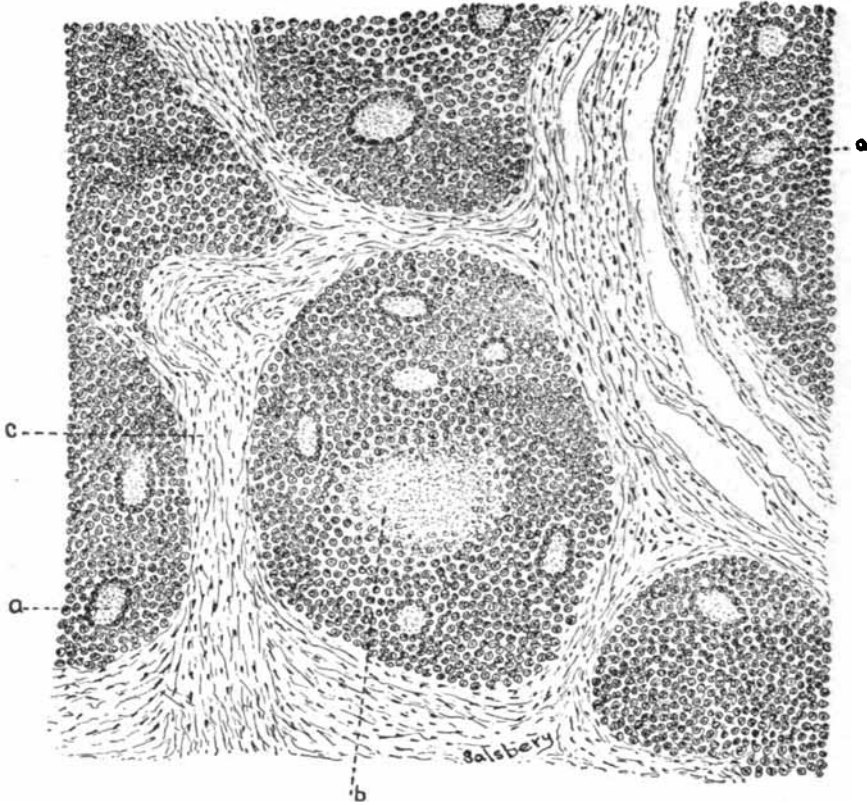


Fig. 195.—A Lesion of Tuberculosis from the Post-pharyngeal Lymph Gland of an Ox. A—giant-cells; b—caseous center within the tubercle; c—fibrous capsule.

tissues except possibly osseous tissue and serous membranes. Tubercular lesions of osseous tissue are usually associated with extensive suppuration of the osseous structures, while tubercular lesions of serous membranes are frequently entirely cellular in structure and do not undergo central necrosis.

Bovine tubercular lesions are usually encapsulated and become quite extensively calcified. The age of the lesions is sometimes important in medico-legal cases. Calcification usually begins

when the tubercle is from six to eight months of age and is extensive by the time the lesion is one year old. Tubercular masses are occasionally observed in the lung, bronchial or mediastinal glands, and in the liver. These masses may contain all stages of tubercular formation or the entire mass may all be in the same stage of development, as liquefying necrosis, caseation or calcification. Tuberculosis of serous membranes of bovines should receive special mention because of the characteristic appearance of the lesions. Bovine serous membrane lesions vary in size from a millet seed to a walnut, but are usually about the size of a pea. These lesions are frequently thickly studded over large areas of a serous membrane. The nodules are surrounded by a firm capsule which causes them to appear as pearl-like bodies, and hence

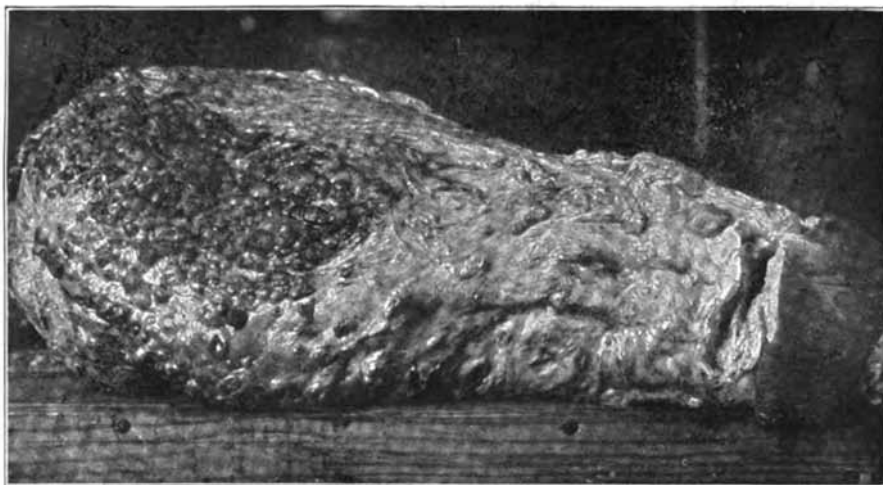


Fig. 196.—Photograph of a tubercular mammary gland, Ox.

the name, "pearly disease." Sometimes serous membrane tubercular lesions are very extensive; this type may be called "mass tuberculosis."

Porcine Tubercular lesions are characterized by enlargement of lymphatic glands, the formation of tubercles of variable sizes in or upon serous membranes and within the substance of glandular organs, bones and other connective tissues. The tubercles produce increased density of invaded soft tissues and are, therefore, easily detected except in very recent infection. The tubercular nodules in the early stages present about the same color as the surface of the tissue invaded. In sectioning the tubercle the central portion is caseous and slightly yellow or fibrous and white.

Sometimes there is a combination of both conditions and occasionally the tubercles contain calcareous granules. The central portion of porcine tubercles rarely contains liquefied necrotic tissue.

Microscopically porcine tubercular lesions are always cellular in the beginning. The cellular tubercles are fairly constant in structure regardless of the tissue in which they occur. The center is at first represented by a mass of lymphoid cells, the other cellular elements occurring as the tubercle develops.

Necrosis, or fibrosis, succeeds the cellular stage in the porcine tubercular lesion. Necrosis of tubercles is probably the result of the activity of very virulent bacteria or the low resistance, of the infected animal. The necrotic center may be surrounded by a cellular zone (lymphoid and endothelial cells), or it may be surrounded by fibroblasts. The necrotic material is invariably caseated and later becomes calcified.

Fibrous lesions vary from the formation of small quantities of fibrous tissue to dense fibrous centers. Fibrous lesions are probably produced by bacteria of low virulence, or occur in animals having a marked resistance. The central portion of the fibrous lesion may become calcified.

The so-called arbor vitae gland is a fibrous center in which the fibrous tissue is arranged similar to the trunk and branches of a tree, hence the name. This lesion is observed in the hog in the cervical lymph nodes. The bacterium tuberculosis has been demonstrated in about 30 per cent of arbor vitae glands.

The lesions of porcine tuberculosis are in brief either cellular, necrotic and calcified tubercles, or cellular, fibrous and calcified tubercles. The lesion is always non-vascular as in other animals.

Avian tubercular lesions are very similar to mammalian tubercles, and may occur in practically any tissue. Microscopically, avian tubercles are found to contain giant cells, endothelioid cells, small round cells and connective tissue cells, the arrangement of which is the same as described in mammalian tubercles. Avian tubercular lesions have been found in the liver, spleen, intestine, mesentery, kidney, lung, skin, and bones, the frequency being in the order mentioned.

Avian tubercles in glandular tissue, i. e., in the liver, kidney, spleen, etc., begin as small, dirty, white cellular foci. They usually occur singly, though they may occasionally become confluent, thus producing nodules a quarter of an inch in diameter. As the tubercles in glandular tissue undergo necrosis, they assume a yellowish color. Intestinal tubercles are about the same

size as those in glandular tissue. The intestinal lesions are usually quite hard and dense and present a glistening appearance. Necrosis frequently destroys the intestinal wall and thus a tubercular intestinal ulcer is produced. Mesenteric tubercles are frequently pedunculated and they invariably present a pearl like appearance.

Extension.—Tuberculosis, except in some cases of the acute form, essentially a localized disease. However, the disease, even in the chronic form, has a tendency to extend and involve new tissue. The extension may be accomplished by means of, first, the lymphatic system, second, the digestive, respiratory and genito-urinary tubes, third, the blood vascular system and fourth, by continuity and contiguity.

Tuberculosis is usually extended by the lymphatic circulation. Thus the first group of lymph nodes through which the lymph passes from a tubercular lesion is almost invariably involved. In fact this is a characteristic of the disease. The large per cent of lymphatic lesions is also evidence of extension by means of the lymph. It has been previously stated that hogs are invariably infected by ingestion of tubercular material and in 93 per cent of tubercular hogs the submaxillary lymph nodes are affected, which is further evidence of lymphatic extension. The fact that infection may extend along the digestive, respiratory or genito-urinary tracts, has been demonstrated. Thus the discharges, containing the *Bacterium tuberculosis* from a pharyngeal tubercle may pass through the oesophagus and stomach and find a nidus favorable for its development in the intestine. In a like manner the lung tissue may become affected by extension from laryngeal, tracheal or bronchial tuberculosis and prostatic tuberculosis may result from extension of renal tubercular lesions. In extensive or generalized tuberculosis the tubercles not infrequently involve and produce necrosis of the blood vessel walls and the virulently contaminated necrotic material being discharged into the blood resulting in tubercular metastasis. Thus tuberculosis is extended by means of the blood. Extension by the blood invariably results in generalized tuberculosis which is usually acute.

In the discussion of tubercular lesions, the formation of secondary and daughter tubercles was mentioned. The production of secondary and daughter tubercles is a means of extension. If the newly formed tubercles are in the same kind of tissue as the primary tubercle then the extension is by continuity. If the secondary or daughter tubercles are in tissues dissimilar to that

in which the primary tubercle occurs the extension is by contiguity.

In the majority of the cases of lymphatic extension and in some of the cases of blood extension the *Bacterium tuberculosis* is incorporated in and transported by leucocytes. The leucocytes usually have sufficient vitality to destroy the incorporated bacteria but occasionally the leucocytes may be destroyed after having transported the bacteria a considerable distance. Thus a *Bacterium tuberculosis* from a pulmonary tubercle may be incorporated by a leucocyte and carried to the kidney and the leucocyte being destroyed the liberated bacterium may establish a tubercular focus in the renal tissue. The occurrence of *Bacterium tuberculosis* in the milk of cows having no mammary tubercular lesions as well as the fact that ingestion of tubercular material frequently causes pulmonary tuberculosis, may be due to leucocytic incorporation and transportation of the infecting micro-organism.

Elimination.—From the sanitary point of view it is always of considerable importance to know the channels or avenues through which infectious agents are discharged in order that they may be destroyed. Tuberculosis affects all tissues and the *Bacterium tuberculosis* may not be eliminated from the affected animal or it may be discharged in one or more of the secretions or excretions. It has been determined by the Department of Agriculture that about 40 per cent of tubercular cattle eliminate the *Bacterium tuberculosis* in their feces. The same investigators also found, in a limited number of dairies, that about 25 per cent of tubercular cows, regardless of location of the lesions, eliminated the *Bacterium tuberculosis* in their milk. These are facts of prime importance in adopting means for checking the progress or for suppression of the disease. The discharges from the respiratory tract of tubercular animals frequently contain the *Bacterium tuberculosis*, especially if they have pulmonary lesions of the disease. The urine and discharges from the female genital organs may be contaminated with the infection. Renal tuberculosis, however, is not of frequent occurrence and it is not probable that the *Bacterium tuberculosis* is eliminated in the urine of tubercular animals in which there are no renal lesions.

In general the channel of elimination of the bacterium tuberculosis depends largely upon the location of the lesion.

Tuberculin and Tuberculin Test.—Tuberculin is a bio-chemic material containing the products and the disintegrated bodies of the *Bacterium tuberculosis*. It is prepared by growing the *Bacterium tuberculosis* in glycerine bouillon for a certain length

of time. The glycerine bouillon culture is filtered and the filtrate sterilized by heat and concentrated to the desired strength by evaporation over a water-bath. The active principle of tuberculin is probably a nucleo-proteid or its chemic derivatives.

Tuberculin is a very reliable diagnostic agent. Its chief use in veterinary medicine has been in the diagnosis of tuberculosis in cattle. It is practically as reliable in the detection of human, porcine and probably avian tuberculosis as in the detection of bovine tuberculosis. The principal method of application has been by subcutaneous injections and noting the temperature changes in the suspected animal. The normal temperature of the animal is ascertained previous to the injection and the temperature is taken every two hours, beginning eight hours after tuberculation. On the day succeeding the injection a rise of from two to three degrees Fahrenheit is considered a reaction and this signifies that the patient is tuberculous. This reaction is probably due to the specific irritating action of the injected tuberculin upon the tubercular foci producing intense hyperemia around and disintegration of the tubercle. Thus there is a sudden discharge of tubercular products into the system and the intense reaction, thermic and constitutional follows.

A purified tuberculin used directly in the conjunctival sac is now on the market. The ophthalmic reaction consists of the production of a marked hyperemia of the conjunctive in from six to ten hours after tuberculation. At the present time the technique is at fault or the tuberculin is of inferior quality and the ophthalmic tuberculin test cannot be relied upon.

ACTINOMYCOSIS.

Actinomycosis is a specific, inflammatory granuloma, caused by the *Cladothrix actinomyces* and characterized by the formation of tumorous masses of fibrous tissue that usually develop suppurating centers and fistulous tracts.

Distribution and extent.—Actinomycosis is prevalent in Europe, Australia, Africa, North and South America. The extent of the disease varies in different countries. According to the 24th Annual Report of the Bureau of Animal Industry there were slaughtered in establishments having federal inspection 7,621,717 cattle, of which 22,742 were found to be affected with actinomycosis, or one in about each 340. The actual per cent is even larger, for many animals afflicted with actinomycosis are slaughtered where there is no official inspection maintained.

Susceptible Animals.—Cattle are more frequently affected

with this disease than other animals, though actinomycosis of sheep, goats and hogs is occasionally reported. A few cases have also been observed in the horse, mule, dog and wild animals.

Etiology.—A fungus, the *Cladothrix actinomyces* or *actinomyces bovis*, is the specific cause of actinomycosis. The life history of this organism is not known, but it is thought that it passes a part of its life cycle upon some of the grasses. Each matured fungus is composed of a central body 10 to 40 microns in diameter, from which the radiating filaments (mycelia) extend outward for a distance of from 5 to 20 microns, then becoming enlarged, terminate in club-shaped bodies from 10 to 50 microns in length. Thus the matured fungus has the appearance of a rosette and is commonly called the "ray fungus." Detached clubs are capable of reproducing the entire rosettes as described. The fungus can be cultivated in artificial media where it develops a tangled mass of mycelia.

Source.—The *Cladothrix actinomyces* is probably most fre-

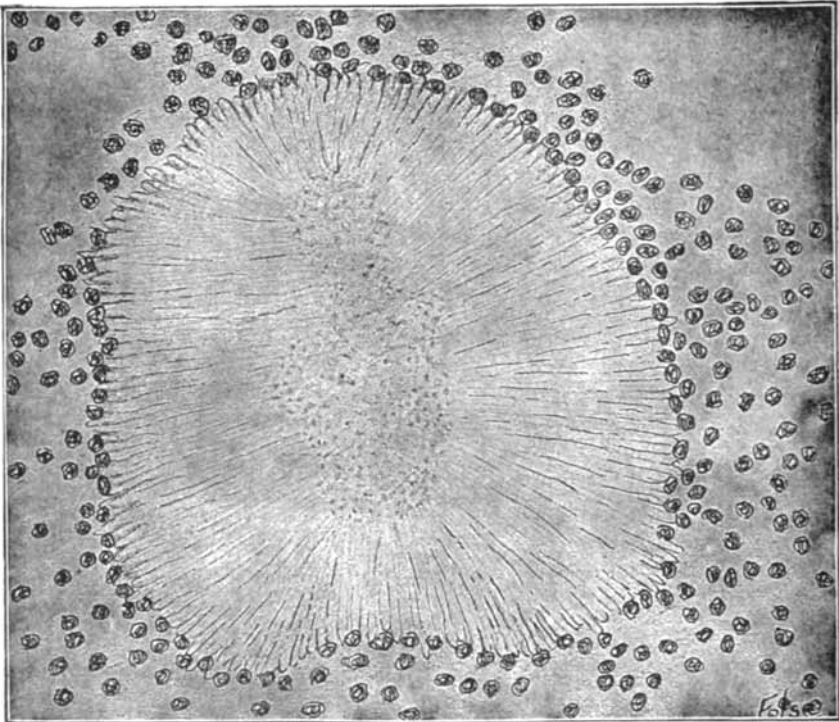


Fig. 197.—Drawing of *Actinomyces* (Ray fungus) in section of tongue.

quently obtained from vegetation, especially wild rye (*Horidium murinum*) consumed by the animal. Infection occurs most frequently in animals fed on dry feed as fodder, stover, straw or hay. During January and February, 1908 .86% or 376 cattle of 41,405 slaughtered had actinomycosis of the tongue or submaxillary lymph nodes, and of 12,484 cattle slaughtered in July, 1908, 44 or .34% were affected with actinomycosis. Some rather extensive outbreaks have been investigated in which it seems highly probable that infection has been direct from one animal to another, or indirect by means of the discharge of actinomycotic animals that had been smeared on rubbing posts, feed racks and feed troughs. (Of 98 head of cattle, three of which were actinomycotic when placed in the feed lot in November, 42 head were affected with actinomycosis when inspected 2½ months later.)

Channel of Entrance.—The causative fungus may gain entrance into the system by way of the digestive tract, the respiratory tract or through the skin. Abraded surfaces appear to be essential for infection, though it has not been proven that the fungus cannot penetrate uninjured surfaces. The digestive tract is the most frequent channel of entrance in cattle. The tongue, especially the dorsal surface at the junction of the base and apex, is subject to injury by the rough, harsh food consumed by cattle. Tongue injuries may also be inflicted by licking boards, posts, etc., containing nails and splinters. Awns of wheat, barley and rye, chaff, splinters and hair accumulate in the erosions or wounds of the tongue, producing the so-called "hair sores." More than 12% of 48,000 cattle slaughtered during the winter months in one of the Kansas City packing houses had "hair sores" upon their tongues. The "hair sore" is intimately associated with lingual actinomycosis; indeed it is rare to find actinomycosis of the tongue or submaxillary lymph glands when there is no "hair sore." Diseased teeth, especially if the gingival mucous membrane is involved, also provide an entry for the ray fungus. The possibility of the infection passing through the intestinal or gastric wall explains the cases of peritoneal actinomycosis that are occasionally observed.

Respiratory infection is not of common occurrence. This type of infection probably occurs by inhalation of chaff or awns contaminated with the *Cladotrix actinomyces*.

The skin is probably the most frequent channel of entrance in hogs. Actinomycotic scirrhus cords are quite common, the infection taking place in the castration wound. Mammary actinomycosis is sometimes observed in sows, especially those running in stubble fields, the infection taking place through abra-

sions produced by the stubble. Abrasions resulting from rubbing on stanchions and feed boxes may be a source of infection in dairy cattle.

Lesions.—*Macroscopic.*—Actinomycotic lesions may be surface or subsurface. The fungus may invade and produce the lesion in any tissue.

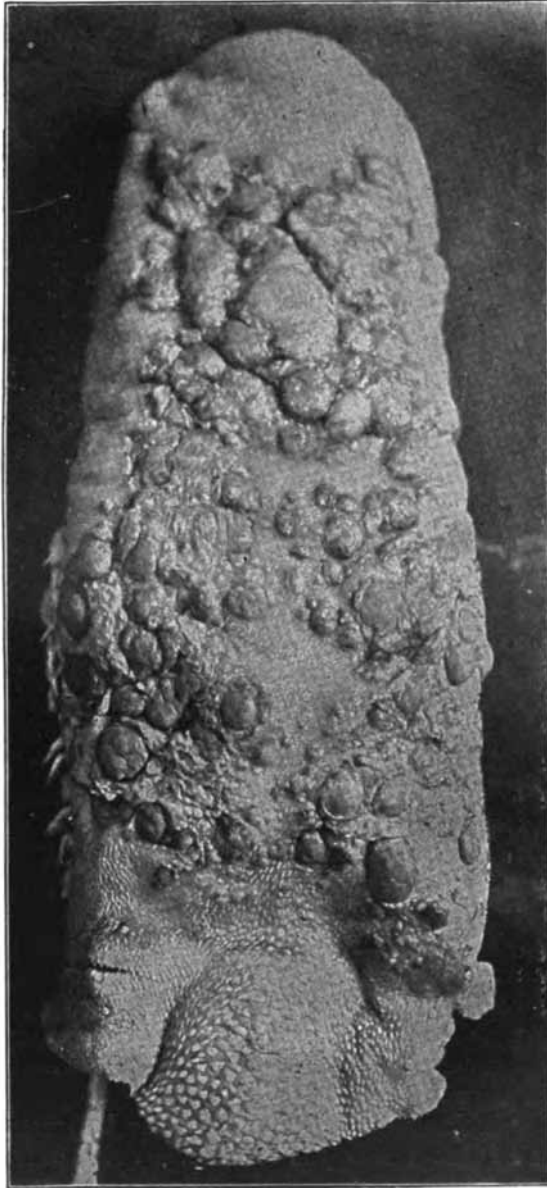
Surface lesions begin as small inflammatory centers which usually thicken and become elevated above the general surface. The lesion gradually increases in size, and in some cases assumes a fungoid appearance. At this stage the lesions vary in size from a small pea to a walnut. The surface tissue may become eroded as a result of the extension of necrosis from the lesion and the typical actinomycotic pus discharged or more frequently the lesion becomes encapsulated by the formation of a dense fibrous capsule. The capsule usually limits the development of the lesion and it may be diminished in size by the contraction of the fibrous tissue constituting the capsule.

Subsurface lesions, though beginning as inflammatory centers, are invariably circumscribed by a dense, fibrous wall. As the disease progresses the center of the lesion undergoes liquefying necrosis. The necrosis extends, producing irregular, tortuous sinuses that may extend through the capsule and into the surrounding normal tissue. Ultimately the liquified necrotic tissue (pus) would ordinarily be discharged upon a surface, or the fungus contained in the necrotic tissue (pus) would perforate the primary capsule and cause the production of a secondary fibrous capsule. Thus the lesion is frequently composed of several communicating cavities (multilocular) containing actinomycotic pus. If such a lesion is incised and pressure applied the typical beads of actinomycotic pus will appear in various places upon the cut surface. Actinomycotic pus is creamy, sticky, tenacious, yellowish-white and contains small, yellow, gritty granules. The pus has a greasy feel and may have a slight odor. If the pus is permanently maintained within the capsule, its fluid content is absorbed and becomes caseous.

Osseous actinomycosis is of common occurrence. The fungus having gained entrance produces inflammation, which is succeeded by disintegration of the osseous tissue and the formation of cavities or pockets. By growth and extension of the infecting fungus, inflammation and disintegration is favored, and thus communicating cavities are formed in the affected bone. As the process of rarefaction continues within there is new osseous tissue deposited without. Thus bone affected with actinomycosis

becomes enlarged and cancellous and has a honeycombed appearance.

Microscopic.—The presence of the *Cladothrix actinomyces* in a tissue produces an irritation resulting in an accumulation of



198.—From photograph, showing actinomycotic nodules on the dorsum of an Ox tongue.

small round cells, the production of endotheloid and giant cells by the invaded tissue, and finally the development of a fibrous capsule around the entire mass. The fungus may appear in the beginning as mycelial elements, but later it has the typical rayed appearance. In old lesions the central portion or body of the fungus becomes calcified.

Surrounding the clubs or mycelium in the early stages are varying numbers of small, round cells (lymphocytes).

As the disease progresses, the matured fungus is more or less surrounded by giant cells that actually contact the fungus. The actinomycotic giant cell is very irregular in shape and size and has varying numbers of nuclei scattered indiscriminately throughout the cell body.

Endotheloid cells appear marginally to the giant cells. These cells are similar in appearance to the endotheloid cell of tuberculosis, having a relatively large cell body and a small, single nucleus.

The small, round cells are first noticed immediately around the fungus, but later they infiltrate the surrounding tissue also, and are in excess of all other cells in the lesion.

Fibroblasts appear in the margin of the early lesion, and through their activity a thick fibrous capsule is produced.

Actinomycotic pus is found to be composed of tissue shreds and fragments, lymphoid cells and some polymorphonuclear leucocytes, an occasional endotheloid cell and the *Cladotrix actinomyces*.

Extension.—The extension of actinomycosis has usually been described as taking place only by growth in continuity or contiguity, or by passing along the respiratory, digestive or genitourinary tubes. By a careful observation of over 72,000 cattle slaughtered, it has been found that many cases, in which there were "hair sores" but no actinomycotic tongue lesions, showed actinomycosis of the submaxillary lymph nodes. The majority of cases of lingual actinomycosis are accompanied by involvement of the submaxillary lymph nodes. That practically all cases of actinomycosis of the submaxillary lymph nodes occurred in animals having "hair sores" is indicative of lymphatic extension. It is therefore quite probable that actinomycosis may be extended in the animal body by means of the lymph.

Differential Diagnosis.—Bovine actinomycosis may be confounded with tuberculosis, nodular disease, abscess formation and various tumors.

Tubercular lesions calcify, actinomycotic lesions rarely become calcified. Tubercular pus is usually quite different from

actinomycotic pus. The former is not sticky or tenacious, and does not contain the small, yellow, gritty granules found in the latter. The capsule of an actinomycotic growth is thicker and denser than the capsule of a tubercular growth. The two diseases can be differentiated positively by microscopic examination of the pus and the lesion. The Bacterium of tuberculosis would be found in tubercular pus and the *Cladothrix actinomyces* in the actinomycotic pus. Tubercular lesions are characterized by the presence of the horse shoe giant cell, the actinomycotic giant cell is irregular in outline and size, is polynuclear, the nuclei being scattered indiscriminately through the cell body.

Nodular disease, though not very prevalent in cattle may be mistaken for actinomycosis. The nodules of nodular disease are in the intestinal wall. The pus in the nodule is greenish yellow in color, and though fluid in the early stages, it later becomes caseous but never contains the calcareous granules. Microscopically the finding of the *Cladothrix actinomyces* in actinomycotic lesions or pus and the absence of this fungus in the lesions of nodular disease is sufficient for differentiation.

From abscesses the differentiation may be made by the peculiarity of the pus, and the capsule, which is usually much more dense in actinomycotic lesions than in abscesses.

Osteosarcomata may produce lesions in bone similar to actinomycotic lesions. A microscopic examination is always sufficient for differentiation of these diseases.

Ovine actinomycosis may be confounded with ovine caseous lymphadenitis and nodular disease. Ovine caseous lymphadenitis is essentially a disease of lymphoid tissue characterized by the formation of greenish yellow pus that later caseates in concentric layers, but never contains gritty granules. The color of the pus and the arrangement of the caseated necrotic tissue is usually sufficient for differentiation of ovine caseous lymphadenitis from actinomycosis.

The remarks on the differentiation of nodular disease in bovines is equally applicable to ovines.

GLANDERS.

Glanders is a specific, infective disease, especially affecting equines, caused by the bacterium *mallei*.

Glanders is prevalent in all countries with the possible exception of Iceland, Australia, and some isolated islands. The disease is found in practically all parts of the United States. It is

more prevalent in those portions of a country in which there is extensive horse traffic. The invasion of a province or a country by an army is usually succeeded by the appearance of glanders.

Etiology.—Glanders is caused by the *Bacterium mallei*. This organism was described by several different investigators in 1882. It is similar in appearance to the *Bacterium tuberculosis*, has rounded ends, is from 2 to 3.5 microns in length and .3 to .5 microns in width. This bacterium occurs singly except that when grown upon potato medium, pairs or even long filaments are not rare. Like, the *Bacterium tuberculosis*, it produces pleomorphic forms when cultivated in different media or under varying conditions. In old cultures it frequently becomes short and is sometime coccoid in appearance. Branching forms are not uncommon. It does not form spores.

The *Bacterium mallei* is stained by aqueous solutions of ana-




Fig. 199.—*Bacterium Mallei*, x1000.

line dyes that are slightly alkaline in reaction, such as Loeffler's methylene blue. It is so-called "Gram negative," i. e., it is decolorized by Gram's solution.

Source of Infection.—Infection probably occurs most frequently in an indirect manner, i. e., the infection is obtained from some surrounding object or thing that has been contaminated with the infected discharges of a glandered animal.

The *Bacterium mallei* is strictly parasitic and the source of the micro-organism is either the discharges from an infected animal or the carcasses of animals that have died of glanders. Fortunately this bacterium possesses little re-

sistance to light, dessication and other external influences and consequently the infection in discharges is as a rule, promptly destroyed. The length of time that the *Bacterium mallei* may exist outside of the animal body and retain its virulence has never been absolutely determined. Authentic cases of glanders have appeared in horses that had been placed in stalls that had been vacant for one year, but prior to that time occupied by glanderous horses. A few reports are indicative of the fact that the *Bacterium mallei* may retain its virulence in infected buildings for two or even three years, but these reports need further substantiation. It seems probable from clinical and experimental evidence that, except in the animal body, the virulence of *Bacterium mallei* is rarely retained longer than one year.

In cities, public drinking fountains, hitching posts and feeding troughs are probably the greatest sources of infection. The purchase of second hand harness, wagons, and other equipment should be regulated by ordinances or laws to prevent the spread of such infections as glanders.

The Channels of Entrance of the Infection.—All exposed surfaces and natural openings of the body may permit the *Bacterium mallei* to gain entrance to the tissues. In glanders, as in tuberculosis it has been quite conclusively demonstrated experimentally that the majority of the cases of glanders results from the ingestion of the *Bacterium mallei*. No doubt infection may occur by inhalation of the infectious agent and an occasional case may be the result of cutaneous inoculation. It is possible for the discharges containing the *Bacterium mallei* to become pulverized and carried by air currents and inhaled. Farcy may or may not result from cutaneous infection. Such inoculations are easily accomplished by bridles, harness, saddles, curry combs, etc. More rarely the conjunctival membrane may be the channel of entrance. For example a horse, affected with nasal glanders may sneeze or cough and thus infection be forcibly introduced onto the mucous membrane of the eye of another horse.

Lesions.—*Macroscopic.*—The lesions of glanders are found especially in the mucous membrane of the anterior respiratory passages, lymph nodes, lung and skin, the frequency being in the order mentioned. It is probable that the *Bacterium mallei* primarily affects lymphoid tissue. The gross lesions may be diffuse or circumscribed, depending upon the virulence of the infecting organisms and the resistance of the affected animal.

Diffuse glander lesions are usually found in animals having

little resistance and in which the disease assumes an acute form. In the nasal mucous membrane, diffuse, glanderous lesions appear as severe inflammation in which the submucosa is extensively infiltrated. The engorgement of the tissue may be sufficient to obstruct circulation and result in necrosis of the mucous membrane thus producing ulcers variable in size and irregular in contour. The submaxillary lymph nodes are invariably hard and enlarged and may or may not be adherent to the maxilla.

Pulmonary, diffuse glander lesions vary in size from a hazel nut to a basket ball and are irregular in shape. These lesions are grayish or dirty white in color. The lesions may undergo a central necrosis or they may become fibrous in nature. The necrotic material may be of a semi-solid or caseous consistency and in the smaller foci there may be calcification. In practically all cases of pulmonary glanders the bronchial and mediastinal lymph nodes are enlarged and contain cellular necrotic or fibrous centers.

Diffuse cutaneous lesions are not of common occurrence. They may be present in acute general glanders, the manifestation in the skin being of the nature of a diffuse gangrenous dermatitis. Cutaneous nodular lesions may become diffuse as a result of rapid and extensive necrosis. Diffuse lesions occur in lymphoid tissue. Splenic lesions are usually nodular though a few cases have been reported in which there were diffuse lesions of the spleen. Osseous lesions are usually diffuse and appear as a suppurative osteitis.

Nodular lesions are common in animals that have a marked resistance or in those cases infected with mildly virulent bacteria. In chronic glanders the lesions are usually nodular.

The appearance of nodular lesions in the nasal, pharyngeal and tracheal mucous membranes as well as in the mucous lining of the facial sinus varies according to the age of the lesion. In the beginning the lymphoid tissue of the mucosa or submucosa becomes swollen and the tumefaction is surrounded by a hyperemic zone. As the disease progresses there is necrosis which not only involves the lesion but also the surface tissue, thus producing an ulcer. The size depth and contour of the ulcer necessarily depend upon the extent of the necrosis. In some instances the nasal septum and facial bones may be perforated. The ulcers vary in size from mere points to areas as large as a silver dollar. The large ulcers are usually the result of two or more necrotic centers becoming confluent. The denuded surface is usually limited or surrounded by a raised

border, the latter being the result of cellular infiltration. The tissue adjacent to the denuded surface may finally produce sufficient new tissue or granulation tissue to repair the injury. If the necrosis involves only the superficial epithelium the repair will be complete and there will be no scar, but if the necrosis has involved the mucosa and portions of the submucosa,

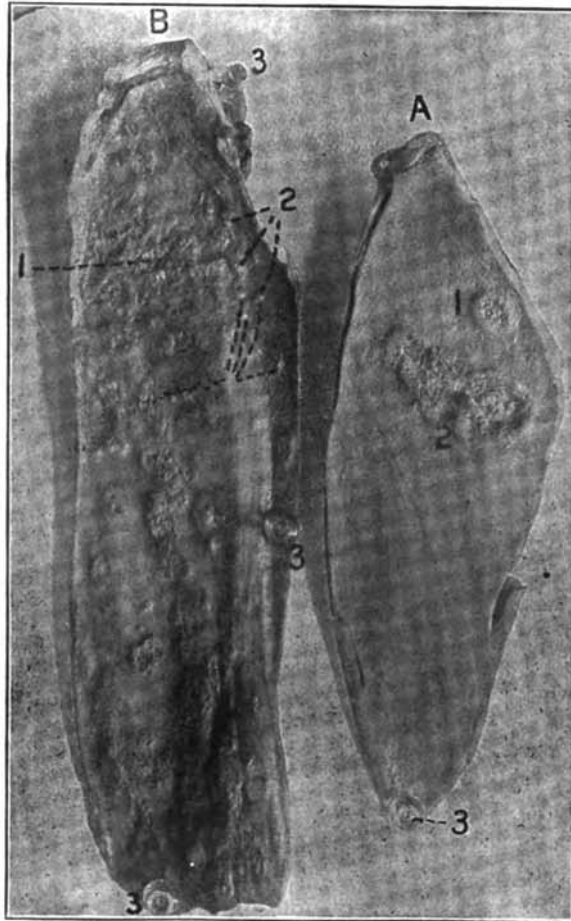


Fig. 200.—Nasal septa, showing glanorous ulcers.

- A.** A nasal septum from glanoured horse.
1. A crateriform ulcer having a thick raised border with a depressed granulating center.
2. Shows characteristic outline of an ulcer, also fusion of two or more primary ulcers.
3. Thumb tacks.
B. A nasal septum from a second glanoured horse.
1. Typical crateriform ulcers and large necrotic area the result of fusion of several ulcers.
2. Cicatrices shown as irregular white spots.
3. Thumb tacks.

there will be large quantities of cicatricial tissue produced and consequently a scar. In nodular glanders of the anterior air passages, the submaxillary lymph nodes are invariably enlarged and contain fibrous, caseous or calcified necrotic foci.

Pulmonary nodular lesions are usually dirty white in color and vary in size from pin point centers to masses as large as a man's head. These nodules in the beginning are entirely cellular and are surrounded by an hyperemic zone. As they become larger the central portion usually becomes necrotic and the hyperemic zone becomes infiltrated with fibroblasts that produce a fibrous capsule. The small nodular lesions may be small and thickly distributed throughout the entire lung. The large

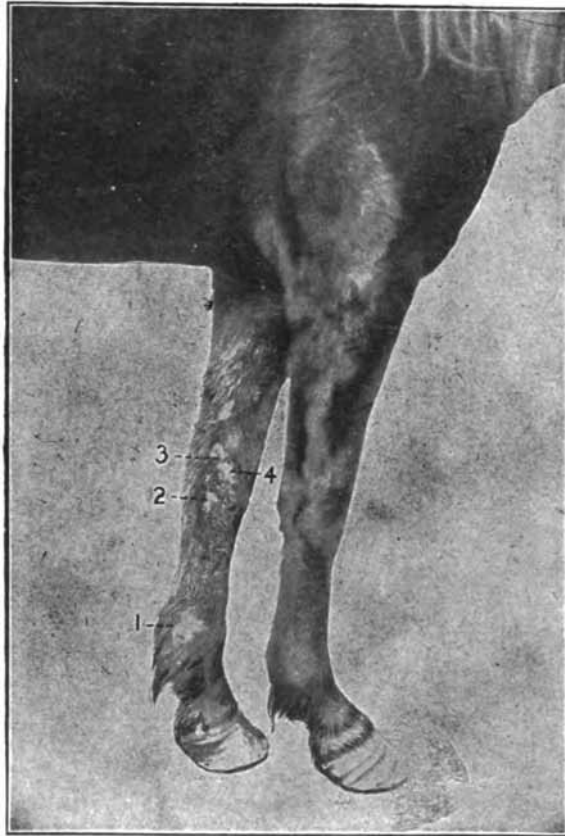

Fig. 201—Cutaneous Glanders—Farcy.

1. A large erosion or ulcer (farcy bud) on the internal surface of fetlock.
- 2, 3 and 4. Other ulcers appearing along the course of the lymphatics.

lesions are usually few in number and they may be formed by two or more nodules becoming confluent. The central caseous necrotic tissue in the small foci frequently becomes calcified. Calcification is usually not evident in the large pulmonary lesions. The bronchial and mediastinal glands are invariably involved and they may be caseous, calcified or indurated.

Nodular lesions of the skin are found in the superficial portion of the dermis or in the subcutaneous tissue. The nodules in the skin rarely become larger than a pea but those of the subcutaneous tissue may become as large as a hen's egg. The central portion of the cutaneous and subcutaneous nodules and

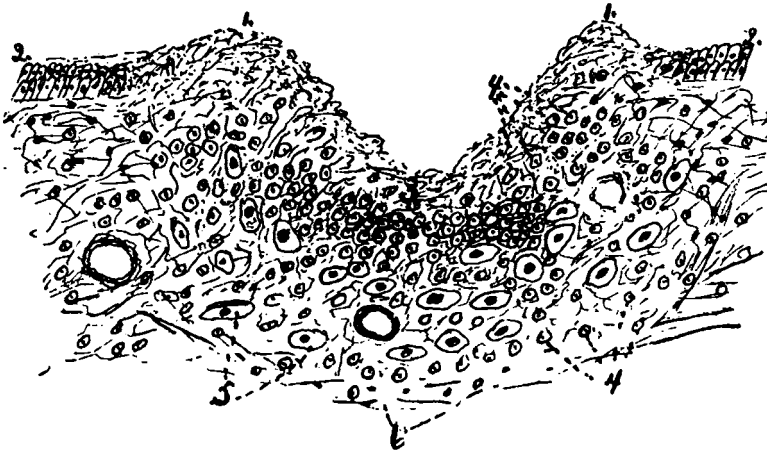


Fig. 202—Microscopic Section through a glanderous ulcer.

1. Margin of ulcer-necrotic tissue.
2. Normal nasal mucous membrane.
2. Showing depth of erosion.
4. Small round cells.
5. Epithelioid cells.
6. Fibrous tissue.

the superficial tissue covering them become necrotic and a sticky, tenacious, semi-fluid material is discharged onto the surface. The related lymphatic vessels are all engorged and the lymph nodes are enlarged and later become indurated.

The tissue destroyed in the lesions of cutaneous glanders may be partially regenerated, but are more frequently repaired by the substitution of fibrous tissue thus producing a thickened fibrous skin.

Small nodular lesions have been noted in the spleen, liver and kidney. The splenic lesions may be caseous or calcified. Hepatic lesions are usually caseous. The portal lymph nodes are usually involved when lesions are present in the liver and

the lymph nodes along the hilus of the spleen are invaded in splenic lesions.

Microscopic.—A small lesion is the result of a diffuse proliferation of lymphoid and endotheloid cells and migration of polymorph leucocytes. The proliferated cells may accumulate in groups, thus producing nodules. In the beginning there is usually a well marked hyperemic zone around the cellular center. The cells constituting the central portion of the lesion later undergo necrosis and about the same time the hyperemic zone becomes less evident. A fibrous capsule may or may not enclose the lesion, depending upon whether it is diffuse or nodular.

In the nodular form of the disease there is a proliferation of fibroblasts in the tissue that was previously hyperemic. The fibroblasts produce the capsule that characterizes nodular glanders. In the older subsurface centers there is formed caseous material and in the small centers calcareous particles. In surface lesions, necrosis or fibrosis is evident.

Diagnosis.—*Mallein* is a filtrate obtained from a glycerinated bouillon culture of the *Bacterium mallei*. Mallein is of diagnostic value only. The cause of the reaction of glandered horses to mallein is due to increased tissue action. The reaction noted in glanders consists in a thermic disturbance, a swelling at the point of inoculation, stiffness in gait, general depression and there is usually frequent urination. The temperature variations in glanders range from 2° F. to 5° F. The maximum rise of temperature usually occurs in from ten to twelve hours after malleination, though it may not appear until the eighteenth hour after injection of the mallein. The high temperature evidenced in a mallein reaction is maintained for a period of from 24 to 60 hours. The swelling is usually quite large and is very sensitive. The lymphatic vessels that are related to the swollen area become engorged and present a knotted appearance. The swelling characterizing a mallein reaction persists for several days. Stiffness of gait may be due largely to the disturbance induced by the swelling at the point of injection, but at least in some cases it is evident that the stiffness of gait is not proportional to the size of the swelling. Aside from stiffness the reacting animal has a dejected appearance. The cause of frequent urination is not known.

Agglutination.—The bacterium *mallei* produces an agglutinin which causes the animal body to produce an agglutinin. A specific agglutinin is found in small quantities in the blood serum of normal horses and in larger quantities in horses with glanders. The agglutination test for glanders depends upon the same principle, as that upon which the typhoid agglutination

depends. The agglutinin appears to cause the bacterial cell membrane to become sticky and thus the bacteria acted upon adhere to each other when they are brought into contact and clumps or clumping of the bacteria results; this constitutes the agglutination reaction. Blood serum is obtained from the suspected animal and placed in a normal salt solution in which are suspended dead *Bacteria mallei*. A series of four tubes is usually used in order that different dilutions may be made. In the 1st tube the dilution is made 1 to 200, i. e. one part of serum is taken to 200 parts of salt solution in which the *Bacterium mallei* is suspended. In the 2nd tube, the dilution is made 1 to 500, the 3rd tube 1 to 800 and in the 4th tube, 1 to 1200. These tubes are placed in an incubator. The reaction consists in a deposit of clumped or agglutinated *Bacteria mallei* in the bottom of the tube. Normal horse serum usually contains sufficient agglutinin to produce a reaction in tube number one, that is in a dilution of 1 to 200. A deposition in tube number two is considered suspicious and deposits in tubes three and four is positive evidence of glanders. The reaction time is from 24 to 60 hours.

The agglutination test is an accurate means of diagnosis if the test fluid is properly prepared and has been properly preserved and if the operator uses care in making the test. The time required is much less than the time necessary in making the mallein test. Another advantage is that the blood serum of an animal dead of suspected glanders can be as readily tested as the serum from a living animal—hence it is useful in medico-legal cases.

EPITHELIOMA CONTAGIOSUM.

Epithelioma Contagiosum is a specific infective disease of fowls and it may be transmissible to pigeons. The disease is widespread in the United States. It is, according to Cary the most serious drawback to the poultry industry of the south. It is quite prevalent in Hawaii, and has been described in many different localities in Europe.

Etiology.—The cause of contagious epithelioma is unknown. The evidence obtainable at the present time indicates that the etiologic factor is either a protozoon, (coccidium), or an ultra microscopic or filterable virus.

Lesions.—*Macroscopic.*—The disease is initiated by a catarrhal inflammation of the mucous membrane of the head and neck. The disturbance may be localized in the eye, nose or mouth, or

may involve all those parts. The inflammatory disturbance stimulates or is accompanied by a proliferation of epithelial cells in the eye, nose, mouth or even on the wattles and comb. These epithelial new growths are at first grayish, have a smooth, glistening appearance and are surrounded by a hyperaemic zone. Later the growths, which become nodular, undergo degeneration, especially upon the surface. The necrotic tissue may remain and form a scab or it may slough leaving a ragged, brown-

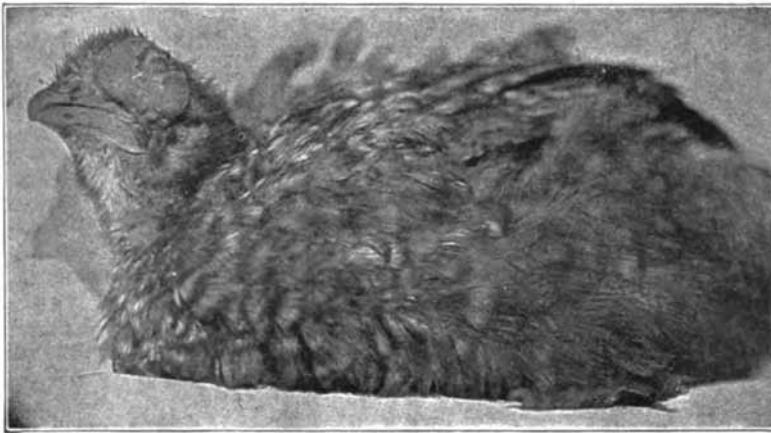


Fig. 202.
Left side of head, showing eye with extensive accumulation of caseous necrotic material.

ish or grayish indurated surface. These nodules may become as large as a pigeon's egg. They frequently entirely obstruct vision and in some cases destroy the eye; those appearing in the nostril may seriously interfere with respiration or even obstruct the air passages; and nodules in the buccal cavity may prevent eating or the prehension of food; while those that occur in or upon the wattles and comb may be so extensive that these structures are practically destroyed. These nodules may entirely undergo necrosis, the necrotic tissue becoming dry and scaly or necrosis may begin in the center of the nodule and be of a liquefying character and when the entire nodule has undergone necrosis the mass is discharged as a thick, watery fluid containing flakes of coagulated necrotic tissue. Again the discharge may be thick and creamy or it may even be of a caseous nature.

Microscopic.—These nodules are found to be composed largely of epithelial cells supported by irregular bands of connective tissue in which there is a limited blood supply. The majority of cells are very large. Some of these cells contain oval refractile bodies that have been considered as protozoa by some.




Fig. 204.

Right side, showing growth from eye, nasal cleft, and mouth.

These bodies are also observed between the cells. The epithelial cells, especially those in the center of the nodule, usually show more or less of a nuclear disintegration. The marginal cells in the nodules are usually more or less flattened. The cell nests

may develop from glandular or surface epithelium, which, in the attempt to repair the eroded surface, becomes entangled in the ragged edges of the ulcers and develop as an epithelioma.

The cell nests increase in size by a multiplication of the peripheral epithelial cells. The rapidly multiplying marginal cells

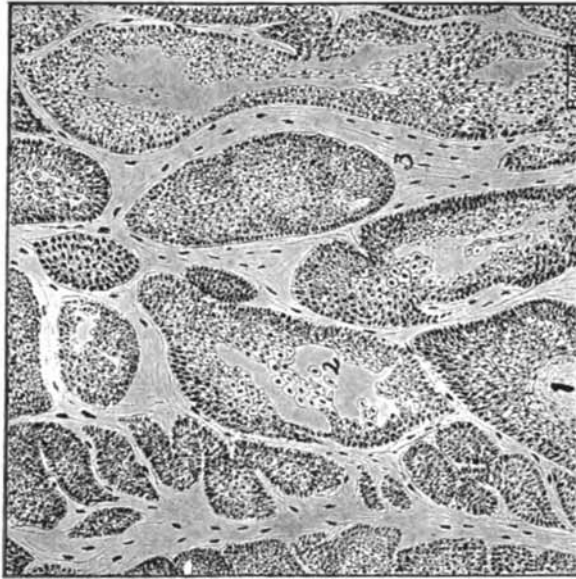


Fig. 205.—Microscopic section of *Epithelioma contagiosum*.

1. Surface of growth from nasal mucous membrane.
2. Area of epithelial cells, cells large in center, becoming smaller and finally blending with the connective tissue.
3. Apparently connective tissue undergoing mucoid degeneration.
4. Probably blood vessels, but the cells are smaller than normal red blood cells of the chicken. The cells are also quite irregular in shape.
5. Degeneration of central cells. The nucleus of the cell first degenerates and finally the cell body.

consume practically all of the central cells and there is central necrosis of the cell nests.

The nests are irregular in size and outline and they are grouped to form the nodules. The nodules may or may not have bands of clear, hyaline substance that represents fibrous tissue undergoing hyaline or mucoid degeneration.

GLOSSARY.

- Ablated** (L.Ab, from and Ferre, to bear). Removal of a part as by cutting off.
- Abnormalities** (L.Ab, from and Norma, rule). Conditions not in accord with the usual.
- Aborted** (L.Ab, from and Oriri, to arise). Prevented from full development.
- Abraded** (L.Ab, from and Radere, to rub). Having the surface tissue rubbed off.
- Abcess** (L.Ab, from and Ceder, to depart). A circumscribed, molecular disintegration of sub-surface tissue.
- Absorption** (L.Ab, from and Sorbere, to suck in). The process of taking up substances into the tissues.
- Accessory** (L. Accessorius, additional). In addition to.
- Achromatosis** (Gr.A, without, Chroma, color and osis, a condition of). A condition of absence of color.
- Acidophile** (L.Acere, to be sour and Gr. Philein, to love). Readily stainable with acid dyes.
- Acini** (L.Acinus, a grape). The small- (st lobules or parts of a compound structure.
- Acromegaly** (Gr.Okros, end and Megalos, large). A condition characterized by overgrowth of the extremities and face.
- Actinomycosis** (Gr.Aktis, a ray, Mukes, fungus and osis, a condition of). A disease caused by the "ray fungus." Cladothrix actinomyces.
- Adenoma** (Gr.Aden, gland and Oma, tumor). An epithelial tumor resembling a gland in structure.
- Adipocere** (L.Adeps, fat and Cera, wax). A wax-like substance formed by exposure of tissue of a cadaver to moisture with air excluded.
- Aerobic** (Gr.Aer, air and Bios, life). Requiring free oxygen (air) in order to live and multiply.
- Agglutinin** (L.Agglutinare, to stick together). An adaptation product of the body cells produced by immunization with corresponding cells which causes a clumping or coalescing of the kinds of cells used in immunization.
- Agglutinogen** (L.Agglutinare, to stick together). A substance present in bacterial immunization which gives rise to the production of agglutinins by the body cells.
- Alveolar** (L.Alveolus, a small lobe). Pertaining to an alveolus. (A small cavity for a tooth or histologic division in a lung, gland, etc.)
- Amboceptor** (Gr.Ambo, both and L. Capere, to take). One of the types of receptors or intermediary bodies in Ehrlich's lateral side-chain theory.
- Amitosis** (Gr.A, without and Mitos, thread.) Direct division of cells without formation of thread-like structures.
- Amniotic** (Gr.Amnon, a foetal membrane.) Pertaining to the amnion, one of the foetal membranes.
- Amoeba** (Gr.Amolbe, a change.) A colorless, single-celled, animal organism that constantly undergoes changes of form.
- Amylaceous** (Gr.Amulon, starch.) Of the nature of, or containing starch.
- Amylin** (Gr.Amulos, starch.) The insoluble wall of a starch grain. Starch cellulose.
- Amyloid** (Gr.Amulos, starch and Eidos, form.) Like starch.
- Anabolism** (Gr.Ana, up and Ballein, to throw.) The transformation of food-stuffs into complex tissue-elements.
- Anaerobic** (Gr.A, without, Aer, air and Bios, life.) Able to live in the absence of free oxygen or air.
- Anaphase** (Gr.Ana, up and Phasis, phase.) The third stage in mitotic cell division.
- Anasarca** (Gr.Ana, up and Sarx, flesh.). An accumulation of non-inflammatory serum in the sub-cutaneous areolar tissue.
- Anastomosis** (Gr.Ana up and Stomoein, to bring to a mouth.) The establishment of a communication between two distinct portions of the same organ (Usually vessels).
- Anemia** (Gr.A, without and Haima, blood.) A deficiency of blood or of any of its constituents.
- Angioblast** (Gr.Aggelon, a vessel and Blastos, germ.) One of the cells of angioblastic origin concerned in the formation of vessels.

- Angioma** (Gr. Aggeion, vessel and Oma, tumor.) A tumor composed of vessels independently of pre-existing blood or lymph vessels.
- Anhydremia** (Gr. A, without, Hudor, water and Haima, blood.) A diminution of the watery constituents of the blood.
- Ankylosis** (Gr. Agkulos, stiffened, and osis, a condition of.) A union of bones in an articulation.
- Anlagen** (Ger. Anlagen.) The foundation or design of a structure, the beginning.
- Anomaly** (Gr. A, without and Homalos, average.) A marked deviation from the normal.
- Antenatal** (L. Ante, before and Natus, born.) Existing before birth.
- Anthracoosis** (Gr. Anthrax, black and osis, a condition of.) A lung disease characterized by deposition of coal dust.
- Antitoxin** (Gr. Anti, against and Toxikon, poison.) A substance elaborated by the body-cells to counteract the toxins of other cells.
- Aplasia** (Gr. A, without and Plasia, formation.) A condition of failure of development.
- Apnoea** (Gr. A, without and Pnoein, to breathe.) A transient cessation of respiration.
- Argyriasis** (L. Argentum, silver and osis, a condition of.) A condition of pigmentation by deposition of silver.
- Arteriolith** (Gr. Arteria, to keep air, trachea and Lithos, stone.) A calculus or stone in an artery.
- Arteriosclerosis** (Gr. Arteria, trachea, Skleros, hard and osis, a condition of.) A chronic inflammation of arteries with hardening of the walls, especially of the intima.
- Arthropoda** (Gr. Arthron, a joint and Pous, foot.) A class of animals having jointed legs.
- Ascites** (Gr. Askos, a bag.) An abnormal collection of non-inflammatory fluid in the peritoneal cavity.
- Assimilation** (L. Ad. to and Similare, to make like.) The process of taking up food-stuffs by the tissues and making them a part of themselves.
- Asthenic** (Gr. A, without and Sthenos, strength.) Characterized by absence of strength or violence.
- Asymmetrical** (Gr. A, without, Sun, together and Metron, measure.) Being unlike in corresponding organs or parts of opposite sides of a body that are normally of the same size.
- Atavismal** (Gr. Atavus, grandfather.) A condition of reappearance in an individual of a peculiarity possessed by a more or less remote progenitor.
- Atelectasis** (Gr. A, without, Telos, form and Ektasis, expansion.) Imperfect expansion or collapse of the air vesicles of the lung.
- Atheromatous** (Gr. Athere, gruel, Oma, tumor and ous, of the nature of.) Of the nature of an aethroma. (A sebaceous cyst containing a grumous material.)
- Atresia** (Gr. A, without and Tretos, perforated.) Failure of a normal opening or canal to develop.
- Atrophy** (Gr. A, without and Trophe, nourishment.) A condition in which there is a decrease in size or number of the composing cells of an organ or tissue.
- Atypical** (Gr. A, without and Tupos, type.) Not conforming to type, irregular.
- Autosite** (Gr. Autos, self and Sitos, food.) A monster capable of independent existence after birth.
- Avidae** (L. Avis, bird.) A family of vertebrates.
- Bactericidal** (Gr. Bakterion, a little stick and L. Coedere, to kill.) Destructive to bacteria.
- Basophile** (Gr. Basis, foundation and Phelein, to love.) A substance that readily combines with basic dyes.
- Benign** (L. Benignus, kind.) Not dangerous to health or life.
- Bifida** (L. Bis, twice and Findere, to cleave.) Divided into two parts.)
- Biologic** (Gr. Bios, life and Logos, study.) Pertaining to Biology. (The study of the structure, function and organization of living forms.)
- Buccal** (L. Bucca, cheek.) Pertaining to the cheeks.
- Bursittae** (L. Bursa, purse.) Small burrs or vessels. A disease of the skin characterized by necrosis.
- Calcified** (L. Calx, lime and Fiere, to become.) A condition of deposition of calcareous matter in tissues.
- Canalization** (L. Canalis, a canal.) The process of formation of canals.
- Caries** (L. Caries, rotten.) The molecular necrosis of bone, enamel, dentine, etc. corresponding to necrosis in soft tissue.
- Carcinoma** (Gr. Karkinos, crab and Oma, tumor.) A malignant epithelial newgrowth.
- Catarrh** (Gr. Katarrhein, to flow down.) An inflammatory condition of a mucous membrane in which there is an excessive production of mucus.
- Caustic** (Gr. Kalein, to burn.) A sub-

- stance that destroys tissue. More violent than corrosive.
- Cellulose** (L.Cellula, a small cell and ovis, a condition of.) The principal constituent of cell-membranes.
- Cementum** (L.Caementum, a rough stone.) A plastic material capable of becoming hard and of binding together contiguous materials.
- Centrosome** (Gr.Kentron, center and Soma, body.) A structural part of a cell in active mitotic cell-division.
- Ceruminous** (L.Cera, wax and ovis, a condition of.) Of the nature of cerumen. (The wax of the ear.)
- Chalcosis** (Gr.Chalix, gravel and ovis, a condition of.) A disease of the lungs caused by the inhalation of dust.
- Chemotaxis** (Gr.Chemia, chemistry and Tassein, to arrange.) The property of cell attraction or repulsion due to chemic substances.
- Chlamydo** (Ger.Chemus, a cloak.) A cloak or mantle. (Used as a limiting prefix.)
- Cholelithiasis** (Gr.Chole, bile, Lithos, stone and ovis, a condition of.) The condition in which there are calculi in the gall-bladder or ducts.
- Cholesteatoma** (Gr.Chole, bile, Stear, fat and Oma, tumor.) A tumor composed of pearl-like masses of epithelial tissue mingled with more or less cholesterol.
- Choroid** (Gr.Chorion, chorion and Eidos, like.) The vascular tunic of the eye continuous with iris and between the sclerotic coat and retina.
- Chromatin** (Gr.Chroma, color.) The part of the protoplasm of a cell that takes up stains.
- Chromatolysis** (Gr.Chroma, color and Luein, to loose.) The destruction of coloring matter.
- Chromosome** (Gr.Chroma, color and Soma, body.) One of the minute bodies into which the chromatin of the cell is resolved in indirect cell-division (Mitosis.)
- Cicatricial** (L.Cicatrix, a scar.) Of or pertaining to a cicatrix.
- Cicatrix** (L.Cicatrix, scar.) The connective tissue that replaces a local loss of tissue.
- Circumscribed** (L.Circum, around and Scribere to write.) Of limited or defined extent.
- Cirrhosis** (Gr. Kirrhos, reddish-yellow.) An overgrowth of connective tissue in an organ usually the result of chronic inflammation.
- Cirsoid** (Gr.Kirsos, a varix and Eidos, form) Resembling a varix. (A dilated and tortuous vessel.
- Clonic** (Gr.Klonos, commotion.) Characterized by spasmodic and convulsive muscular contractions alternating with relaxations.
- Clot** (A.S.Clate, a burr.) A special solidification of the blood outside of a vessel.
- Coagulated** (L.Coagulare, to curdle.) A condition in which there is a coagulum.
- Coagulum** (Coagulare, to curdle.) A solidification of the blood occurring in a dead vessel.
- Coagulation** (L.Coagulare, to curdle.) The process of forming a coagulum.
- Coalesce** (L.Coalescere, to grow together.) The union of two or more parts of things.
- Coccidiosis** (Gr.Kokkos, a berry and ovis, a condition of.) The condition of being affected with Coccidia, a genus of unicellular protozoa.
- Collagen** (Gr.Kolla, glue and Gennaein, to produce.) A substance of the body, especially of cartilage, that is converted into a gelatin by boiling.
- Collagenous** (Gr.Kolla, glue and Gennaein, to produce.) of the nature of Collagen.
- Collateral** (L.Con, together and Latus side.) Of the nature of an accessory, not direct.
- Colliquation** (L.Con, together and Liquare, to melt.) The liquefaction or breaking down of a tissue or organ.
- Coma** (Gr.Koma, a deep sleep.) A state of unconsciousness not influenced by external stimuli, control of vital functions still persisting.
- Compensatory** (L.Compensare, to equalize.) Restoring a balance or deficiency of a part by means of some other part or organ.
- Complement** (L.Cum, together and Piere, to fill.) That which supplies a deficiency.
- Complex** (L.Cum, together and Piere, to fill.) The totality of a thing. A thing taken as a whole with consideration of its make-up of parts.
- Component** (L.Cum, together and Ponere, to place.) One of the parts that make up a body.
- Concentric** (L. Cum, together and Centrum, center.) Arranged in an equidistant manner about a common point.
- Congenital** (L.Cum, together and Gr. Gennaein, to produce.) Existing for occurring at birth.

- Congestion** (L.Con, together and Cere, to bring.) An abnormal collection and retention of blood in the vessels of a part.
- Conglomerate** (L.Cum, together and Glomerare, to heap up.) Arranged in a mass together indiscriminately.
- Conidia** (Gr.Konis, dust and diminutive term.) The deciduous, axial spores of certain fungi.
- Conjugation** (L.Cum, together and Jugare, to yoke.) A condition of being joined.
- Contiguity** (L.Cum, together and Tangere, to touch.) A condition of being in contact. (Spoken of two different kinds of tissue.)
- Continuity** (L. Cum, together and Tigere, to touch.) A condition of being without interruption of part. (Within the same tissue.)
- Conventionally** (L.Con, together and Venire, to come.) According to agreement.
- Cornified** (L.Cornu, horn and Facere, to make.) The condition of having been made or having become horny.
- Corporation** (L.Corporus, a body.) A collective body considered as one or taken as a whole.
- Corpuscle** (L.Corporus, body and diminutive term.) A small body or structure. Usually the cell-content of the blood.
- Correlated** (L. Con, together and Relatio, relation.) Related to.
- Corrosive** (L.Con, together and Rodere, to gnaw.) A substance that destroys tissue (less violent than a caustic).
- Cortical** (L.Cortex, bark.) Of or pertaining to the cortex, the surface layer.
- Cotyledons** (Gr.Kotyledon, a socket.) An enlarged vascular organ of the chorion.
- Croupous** (A.S.Kropan, to cry aloud.) Of the nature of croup. Characterized by a development of a membranous deposit or exudate on the surface of a mucous membrane.
- Cutaneous** (L.Cutis, skin.) Pertaining to the skin.
- Cycle** (Gr.Kuklos, a circle.) A round of years. A period of time.
- Cystadenoma** (Gr.Kustis, bladder, Aden, gland and Oma, tumor.) An adenoma containing cysts.
- Cystic** (Gr.Kustis, a bladder.) Pertaining to or resembling a cyst.
- Cytoplasm** (Gr.Kutos, cell and Plessein, to mold.) The essential, viscid substance of a living cell.—Proto-plasm.
- Cytosis** (Gr.Kutos, cell and osis, a condition of.) Cell proliferation.
- Death** (A.S.Death.) The total cessation of life.
- Debris** (L.Dis, apart and Briser, to break.) The material resulting from the destruction of anything.
- Decubital** (L.Decubitus, a lying down.) The position of lying down.
- Degeneration** (L.De, away from and Gerere, to become.) A morbid conversion of the elements of a tissue into new substance.
- Deleterious** (L.Deletere, to destroy.) Characterized by a hurtful or destructive tendency.
- Denticle** (L.Dens, tooth and diminutive term.) A small tooth or projecting point.
- Depleted** (L.De, from and Plere, to fill.) Condition of diminished amount of fluid in a body or part.
- Dermatologic** (Gr.Derma, skin and Logos, study.) Pertaining to dermatology. The study of the skin.
- Desiccant** (L.Desiccare, to dry up.) A substance that has the property of drying up other substances.
- Desiccated** (L.Desiccare, to dry up.) A condition of being dried up.
- Detritus** (L.De, away from and Terere, to rub.) Finely divided material worn off from substances by rubbing.
- Diabroals** (Gr.Dia, through and Bibroskein, to eat.) A condition of having been broken through corrosive action.
- Diapedesis** (Gr.Dia, through and Pedaein, to leap.) The passage of blood through an unruptured vessel-wall.
- Diaster** (Gr.Dis, two and Aster, star.) The so-called double star or wreath in the mitotic cell division.
- Diastole** (Gr.Dia, through and Stole, a drawing.) The period of dilatation of the chamber of the heart.
- Dichotomous** (Gr.Dicha, asunder and Temnein, to cut.) Regularly dividing into pairs from bottom to top.
- Diffuse** (L.Dis, apart and Fundere, to pour.) Not limited in extent.
- Digestion** (L.Dis, apart and Gerere, to carry.) The preparation of food-stuffs for absorption and assimilation.
- Diphtheritic** (Gr.Diphtheria, skin or membrane.) Pertaining to diphtheria, or characterized by formation of false membrane in and upon a mucous membrane.
- Disintegrated** (L.Dis, apart and Integer, a whole.) Broken up or decomposed.
- Disimilation** (L.Dis, apart and Simu-

- lare, to make like.) To cause to appear different.
- Dissociated** (L. Dis, apart and Sociare, to associate.) A condition of being separated or broken up.
- Dropsy** (Gr. Hudrops, dropsy.) The collection and retention of a non-inflammatory lymph transudate within a tissue or body-cavity.
- Eburnated** (L. Ebur, ivory.) An increased density of bone, similiar to ivory.
- Echymosis** (Gr. Ek, out and Chumoma, a flowing out.) An extravasation of blood into the subcutaneous tissues.
- Ectropla** (Gr. Ek, out and Trepein, to turn.) Eversion or turning out of the edge of a part, especially of the eyelid.
- Efferescence** (L. Effervescere, to boil up.) Giving off bubbles of gas.
- Effusion** (L. Effundere, to pour out.) The escape of a liquid exudate into a tissue or part, especially of serum or blood.
- Elimination** (L. Ex, out and Limen, threshold.) The expulsion of anything from the body, especially of waste products.
- Emaciation** (Emaçiare, to become lean.) A condition resulting from a general wasting away of all tissues of the body.
- Embolus** (Gr. En, in and Ballein, to throw.) An obstruction in a vessel by matter from another point.
- Embryonal** (Gr. En, in and Bruein, to grow) Pertaining to an embryo. The foetus in the early stages of its development.
- Emphysema** (Gr. Emphusaein, to inflate.) A condition in which there is an accumulation of gas in the interstices of the connective tissue.
- Empyema** (Gr. En, in and Puon, pus.) Pus in a body cavity.
- Encephaloid** (Gr. Egkephalos, brain.) Of the nature of brain tissue.
- Endemic** (Gr. En, in and Demos, people.) A disease found in a certain place more or less constantly.
- Endomysium** (Gr. Endon, within and Mus, muscle.) The connective tissue structure separating muscle-fibre bundles.
- Endothellium** (Gr. Endo, within the Thele nipple and Oma, tumor.) A tumor composed of endothelial cells.
- Endothellium** (Gr. Endo, within and Thele, nipple.) Cells covering the inner surface of vessels not communicating with the outer air.
- Endotoxin** (Gr. Endon, within and Toxikon, poison.) A poisonous substance found within the cell body of a bacterium.
- Enterolith** (Gr. Enteron, bowel and Lithos, stone.) A concretion found in the intestines: An intestinal calculus.
- Enterorrhagia** (Gr. Enteron, bowel and Hregunal, to burst forth.) Hemorrhage into the intestines.
- Enucleated** (L. Ex, out of and Nucleus, kernel.) Removed in such a way that the body comes out clean and whole from its capsule (as of a tumor.)
- Ensootic** (Gr. En, in and Zoon, animal.) Pertaining to a disease of lower animals and found in a certain place more or less constantly.
- Enzym** (Gr. En in and Zume, leaven.) A ferment formed within the body.
- Enzymotic** (Gr. En, in and Zume, leaven.) Pertaining to leaven, (Enzym.)
- Eosinophilic** (Gr. Eos, dawn and Phillein to love.) Showing a peculiar affinity for eosin or acid stains in general.
- Ependymal** (Gr. Epi, upon and Enduma, a garment.) Pertaining to the Ependyma. The lining membrane of the cerebral ventricles and of the central canal.
- Ephemeral** (Gr. Epi, upon and Hemera, day.) Lasting but a day; temporary.
- Epidermal** (Gr. Epi, upon and Derma, skin.) Pertaining to the epidermis, the outer layer of the skin.
- Epilepsy** (Gr. Epi, upon and Lepsis, seizure.) Paroxysmal loss of consciousness with convulsions lasting but a short time.
- Epistaxis** (Gr. Epi, upon and Stazein, to cause to drop.) Hemorrhage from the nose.
- Epithellium** (Gr. Epi, upon and Thele, nipple.) Cells forming the epidermis and lining vessels that communicate with the external air.
- Etiology** (Gr. Aitios, cause and Logos, study.) The study of the causes of disease.
- Evolutionary** (L. Ex, out and Volvere, to roll.) Pertaining to evolution: The process of development from simple to complex form.
- Exanthematous** (Gr. Ex, out of and Ant-hema, a breaking forth and ous pertaining to.) Of the character of Exanthema: An eruption of the skin.
- Exciting** (L. Ex, out and Citare, to stir.) Calling forth directly.
- Excrement** (L. Ex, out and Cernere, to separate.) Matter cast out as waste from the body (especially the feces.)
- Excretion** (L. Ex, out and Cernere, to

- separate.) The discharge by the tissues of waste products.
- Exfoliate** (L.Ex, from and *Foliare*, to give forth leaves.) To separate into thin layers.
- Exfoliation** (L.Ex, from and *Foliare*, to give forth leaves.) The process of separating into thin layers.
- Exophthalmic** (Gr.Ex, out and *Ophthalmos*, eye.) Pertaining to abnormal extrusion of the eye-ball.
- Extirpation** (L.Ex, out and *Stirps*, stem.) Complete removal or eradication of a part.
- Extravasation** (L.Extra, outside, and *Vas*, vessel.) The escape of fluid from its containing cavity or vessel. (Especially applied to the blood.)
- Extra-uterine** (L.Extra, outside of and *Uterus*, uterus.) Outside of the uterus.
- Extrinsic** (Extra, without and *Secus*, otherwise.) Coming from the outside: Not directly belonging to a part.
- Exudate** (Ex, out and *Sudare*, to sweat.) A portion of the blood that has passed into a tissue from its vessels because of inflammatory disturbances.
- Exudation** (L.Ex, out and *Sudare*, to sweat.) The production of an exudate.
- Faceted** (Fr.Facette, a little face.) Provided with many small plane surfaces.
- Facultative** (L.Facultas, capability.) Capable of assuming a part or condition (spoken of bacteria.)
- Fever** (L.Fibres.) An abnormally high temperature.
- Fibrinopurulent** (L.Fibra, fibre and *Pus*, pus.) Composed of fibrin and pus.
- Fibrinous** (L.Fibra, fiber.) Of the nature of or consisting of fibrin.
- Fibroglia** (L.Fibra, thread and *Glia*, glue.) The glue-like fibres of some tumors.
- Filamentous** (L.Filum, a thread and *ous* of the nature of.) Like a small thread in structure.
- Filaria** (L.Filum, a thread.) A genus of nematode worms, thread-like, endoparasitic.
- Filum terminale** (L.Filum, a thread and *Terminale*, terminal.) The long, slender, thread-like termination of the spinal cord.
- Flagella** (L.Flagella, a whip.) A motile whip-like process (usually applied to some bacteria).
- Foci** (L.Focus, a fire-place.) The principal seats of a disease.
- Foetus** (L.Foetus, offspring.) Unborn off-spring of viviparous animals in later developmental stage.
- Follicle** (L.Follis, a bellows and diminutive term.) A small sac or gland.
- Fractous** (L.Frangere, to break.) Apt to become difficult to control.
- Fracture** (L.Frangere, to break.) A break in the continuity of osseous tissue (bone.)
- Function** (L.Fungi, to perform.) The normal action or work of a part.
- Fusiform** (L.Fusus, a spindle and *Forma*, form.) Like a spindle in form.
- Galactopherous** (Gr.Gala, milk and *Ferein*, to bear.) Producing milk.
- Gangrene** (Gr.Gangraina, a sore.) That type of necrosis characterized by putrefaction of the necrotic tissue.
- Gemmation** (L.Gemma, bud.) The act of budding or reproduction by budding.
- Gestation** (L.Gestare, to bear.) The period from fertilization of the ovum to its expulsion from the uterus.
- Glia cells** (L.Glia, glue.) Neuroglia or the supporting-structure cells of nerve-tissue.
- Glioma** (Gr.Glia, glue and *Oma*, tumor.) A tumor composed of neuroglia cells.
- Glycogen** (Gr.Glukos, sweet and *Gennaein* to produce.) A substance formed from carbohydrates in the body and stored up in certain structures: often called animal starch.
- Granulation** (L.Granula, a little grain.) The formation of new tissue in the repair of local loss of tissue and composed of capillary vessels enclosed by groups of connective tissue cells.
- Haptophore** (Gr.Haptain, to seize and *Phorein*, to carry.) The stable, non-poisonous element of a toxin which enables it to unite with an antitoxin (Ehrlich's lateral side-chain theory.)
- Helminths** (Gr.Helmins, a worm.) A branch of invertebrates known as worms.
- Hematemesis** (Gr.Haima, blood and *Emesis*, vomiting.) The vomiting of blood. Gastric hemorrhage.
- Hematidrosis** (Gr.Haima, blood and *Hidrosis*, sweating.) The sweating of blood or of a blood-like substance.
- Hematin** (Gr.Haima, blood.) A product of decomposition of Hemoglobin.
- Hematocoele** (Gr.Haima, blood and *Kele*, tumor.) The extravasation of blood into a cavity, especially the tunica vaginalis testis.
- Hematogenous** (Gr.Haima, blood and

- Gennaein, to produce.) Derived from or having origin in the blood.
- Hematoidin** (Gr.Haima, blood and Eidos, resemblance.) A yellowish-brown, iron-free substance obtained from hemoglobin of the blood.
- Hematoma** (Gr.Haima, blood and Oma, tumor.) A circumscribed collection of extravasated blood.
- Hematometra** (Gr.Haima, blood and Metra, uterus.) An accumulation of blood in the uterine cavity, extravasated from the mucosa.
- Hematuria** (Gr.Haima, blood and Ouron, urine.) Urine containing whole blood. A condition of bloody urine.
- Hemochromogen** (Gr.Haima, blood, Chroma, color and Gennaein, to produce.) A crystalline coloring matter derived from the hemoglobin of the blood.
- Hemocoelia** (Gr.Haima, blood and Kollia, belly.) An accumulation of blood within the peritoneal cavity.
- Hemogenous** (Gr.Haima, blood and Gennaein.) Derived from the blood or having origin in the blood.
- Hemoglobin** (Gr.Haima, blood and L. Globus, globe.) The coloring matter of the red blood corpuscles.
- Hemoglobinuria** (Gr.Haima, blood, L. Globus, a globe and Gr.Ouron, urine.) A discharge of urine containing hemoglobin. A condition of hemoglobin in the urine.
- Hemolysis** (Gr.Haima, blood and Luein, to loose.) Destruction of the blood or of its corpuscles.
- Hemoptysis** (Gr.Haima, blood and Ptuein, to spit.) Spitting blood from the respiratory passages—pulmonary hemorrhage.
- Hemorrhage** (Gr.Haima, blood and Hragnum, to burst forth). The escape of blood through a vessel wall.
- Hemosideria** (Gr.Haima, blood and Sideros, iron.) A golden-yellow pigment containing iron and derived from the hemoglobin of the blood.
- Hemothorax** (Gr.Haima, blood and Thorax, thorax.) An accumulation of blood in the thoracic cavity.
- Hepatogenous** (Gr.Hepa, liver and Gennaein, to produce.) Produced by or in the liver.
- Hermaphrodite** (Hermes and Aphrodite, Greek deities.) An individual that possesses more or less completely both male and female genital organs.
- Hernia** (Gr.Hernos, a sprout.) The protrusion of an organ through an abnormal opening in the wall of its containing cavity.
- Heterogeneous** (Gr.Heteros, other and Genos, kind.) Composed of different substances.
- Humor** (L.Humor, moisture.) A fluid or semi-fluid part of the body.
- Hyalin** (Gr.Hualos, glass.) A translucent substance. The chief nitrogen constituent of hydrated cysts.
- Hyaloplasm** (Gr.Hualos, glass and Plasm, to mold.) The fluid portion of the cell-protoplasm.
- Hydrargyrosis** (Gr.Hudor, water and Arguros, silver (Mercury).) A deposit of mercury in the tissues.
- Hydremia** (Gr.Hudor, water and Haima, blood.) A condition in which the fluid of the blood is in excess of the normal proportion of cells.
- Hydrocele** (Gr.Hudor, water and Kele, tumor.) A collection of oedematous fluid within the tunica vaginalis.
- Hydrocephalus** (Gr.Hudor, water and Kephale, head.) A collection of oedematous fluid in the serous cavities of the brain or its meninges.
- Hydropericardium** (Gr.Hudor, water, Peri, around and Kardia, heart.) A collection of oedematous fluid in the pericardial sac.
- Hydrople** (Gr. Hudrops, dropsy.) Pertaining to or affected with dropsy.
- Hydrops** (Gr.Hudrops, dropsy.) Dropsy: An abnormal collection and retention of serum in the cellular tissue or in a body cavity.
- Hydrothorax** (Gr.Hudor, water and Thorax, thorax.) Abnormal accumulation of an oedematous fluid in the pleural cavity.
- Hyperchromatosis** (Gr.Huper, above, Chroma, color and osis, a condition of.) A condition of excessive deposition of pigment in the tissues.
- Hyperemia** (Gr.Huper, above and Haima, blood.) An increase in the blood supply to a part.
- Hypernephroma** (Gr.Huper, above Nephros, kidney and Oma, tumor.) A tumor composed of tissue similar to adrenal tissue.
- Hyperplasia** (Gr.Huper, above and Plasis, formation.) An increase in the number of cells in a part.
- Hyperplastic** (Gr.Huper, above and Plasis, formation.) Pertaining to hyperplasia.
- Hypersensitive** (Gr.Huper, above and L.Sensue, feeling.) A condition of increased or abnormal tendency to reaction to a stimulus.
- Hypertrophy** (Gr.Huper, above and Trophé, nourishment.) An excessive

- increase in the size of the cells of a tissue.
- Hyphae** (Gr.Hupha, a web.) The filaments composing the mycelium of a fungus.
- Hyphomycetes** (Gr.Hupha, a web and Mukos, a fungus.) A group of fungi including the molds. Some are pathogenic.
- Hypoplasia** (Gr.Hupo, under and Plasia, formation.) Defective or incomplete development of a tissue.
- Hypothesis** (Gr.Hupo, under and Tithe-nal, to put.) A proposition taken for granted in order to draw a conclusion to aid in explanation of certain facts.
- Ichorous** (Gr.Ichor, serum or pus.) Of the nature of ichor: An acrid, thin, puriform discharge.
- Ichthyosis** (Gr.Ichthus, a fish and ois, a condition of.) A condition like the scales of a fish.
- Icterus** (Gr.Ikteros, yellow.) Jaundice, a yellow pigmentation of the tissues with the coloring matter of the bile.
- Immunity** (L.In, not and Munis, serving.) A condition of exemption from a disease.
- Impacted** (L.In, in and Pingere, to drive.) Driven firmly in or dislodged with difficulty.
- Inanition** (L.Inanis, empty.) A wasting of the body from lack of food or from inability to assimilate it.
- Inbreeding** (A.S. In, and Brodan, to nourish.) The production of offspring by closely related parents.
- Incorporated** (L.In, and Corpus, body.) Thoroughly united with a body in a compact mass.
- Indurated** (L.In, and Durus, hard.) Rendered hard.
- Inert** (L.In, not and Ars, art.) Without action.
- Infarct** (L.In, in and Farcire, to stuff.) A wedge-shaped area (hemorrhagic or anemic) in an organ produced by obstruction of a terminal vessel.
- Infection** (L.In, in and Facere, to make.) The invasion of the body by pathogenic micro-parasites and the sum-total of the disturbances produced by their presence therein.
- Infectious** (L. In, into and Facere, to make.) Capable of communicating a disease.
- Inflammation** (L.In, and Flamma, flame.) The reaction of a living animal tissue to an irritant accompanied by circulatory disturbances and by destructive or proliferative tissue changes.
- Ingested** (L.In, in and Gerere, to bring.) Taken into the stomach or alimentary tract.
- Inherited** (L.In, to and Haerere, to cleave.) Born to or belonging to by birth.
- Inhibiting** (L.In, in and Habere, to hold.) Holding in check or hindering from doing a thing.
- Inimical** (L.In, not and Amicus, friend.) Having a hostile tendency. Liable to injure.
- Inoculating** (L.In, into and Oculus, a bud.) The introduction of a virus of a disease into a wound or abrasion of the skin.
- Inosculation** (L.In, into, and Os, mouth.) The joining of blood vessels by direct communication.
- Insidious** (L.Insidioe, ambush.) Coming on stealthily or imperceptibly.
- Inspissated** (L.In, intensive term and Spissare, to thicken.) Thickens by removal of fluid.
- Insusceptibility** (L.In, not and Suscipere, to receive.) Not having a liability to acquire a disease.
- Intercellular** (L.Inter, between and Cella, cell.) Existing between the cells of a tissue.
- Interfunicular** (L.Inter, between and Funiculus, cord.) Existing between the bundles of tissue.
- Intermittent** (L.Inter, between and Mittere, to send.) Characterized by intervals between.
- Interstice** (L.Inter, between and Stare, to stand.) Spaces between or to stand between.
- Interstitial** (L.Inter, between and Sistere, to place.) Pertaining to structures between the cells of a part. (Stroma.)
- Intracellular** (L.Intra, within and Cella, cell.) Existing within the cells of a tissue.
- Intrinsic** (L.Intra, within and Secus, otherwise.) Situated entirely within or pertaining exclusively to a part.
- Intussusception** (L.Intus, within and Suscipere, to receive.) A slipping of one part of an organ (usually intestine.) into the parts beyond.
- Invagination** (L.In, within and Vagina, a sheath.) The unsheathing of a tissue.
- Involucre** (L.In, in and Volvere, to wrap.) The covering or sheath containing the sequestrum of necrosed bone.
- Irritant** (L.Irritare, to excite.) Anything that produces an excessive action or functioning in a responsive tissue.

- Ischemia** (Gr. *Ischein*, to check and *Haima*, blood.) A local anemia.
- Ischiopagus** (Gr. *Ischion*, hip and *Pagos*, union.) A monster with two heads and with bodies united at the hips.
- Karyokinesis** (Gr. *Karuon*, nucleus and *Kinesis*, motion.) Indirect cell-division with formation of thread-like structures. (Mitosis.)
- Karyolysis** (Gr. *Karuon*, nucleus and *Luein*, to loose.) The morbid destruction of the cell nucleus.
- Katabolism** (Gr. *Katam*, down and *Ballain*, to throw.) The transformation of complex tissue-elements into simpler ones in the production of energy.
- Keratitis** (Gr. *Keras*, horn or cornea and *Itis*, inflammation.) Inflammation of the cornea.
- Keratosis** (Gr. *Keras*, horn or cornea and *osis*, a condition of.) A disease of the skin characterized by an overgrowth of horny tissue.
- Kinetic** (Gr. *Kinein*, to move.) Pertaining to motion.
- Keloid** (Gr. *Kele*, a claw and *Eidos*, like.) A raised, cutaneous dense overgrowth of white fibrous connective tissue in a cicatrix, very common in the negro.
- Lacerated** (L. *Lacerare*, to tear.) Condition of being torn apart leaving ragged edges.
- Lacunae** (L. *Lacuna*, a small lake.) Small pits or depressions: Hollow spaces.
- Laminated** (L. *Lamina*, a plate or scale.) Made up of laminae, of thin flat plates.
- Lecithin** (Gr. *Lekithos*, the yolk of an egg.) A complex nitrogenous substance found widely distributed in the body tissues.
- Lelomyoma** (Gr. *Leios*, smooth *Mus*, muscle and *Oma*, tumor.) A tumor composed of unstriped muscle tissue.
- Lesion** (L. *Laesio*, to hurt.) A morbid structural change.
- Leucoderma** (Gr. *Leukos*, white and *Derma*, skin.) A condition of abnormal whiteness of the skin—Albinism in patches.
- Leucosain** (Gr. *Leukos*, white of egg and *Oma*.) A product of metabolism of the tissues of the body and normally present in them.
- Leucocytosis** (Gr. *Leukos*, white, *Kutos*, cell and *osis*, a condition of.) An increase in the relative number of leucocytes in the blood.
- Leucoprotase** (Gr. *Leukos*, white and *Protos*, first.) A ferment.
- Leukemia** (Gr. *Leukos*, white and *Haima*, blood.) A condition in which there is a proportional increase of leucocytes in the blood.
- Lobulate** (Gr. *Lobus*, a lobe and diminutive term.) Containing small lobes.
- Lumen** (L. *Lumen*, light.) The cavity surrounded by walls of a tubular vessel.
- Lymph** (L. *Lympha*, water.) That portion of the blood which passes through the capillary walls into the perivascular spaces and consists of diluted plasma, leucocytes and usually waste material.
- Lymphogenous** (L. *Lympha*, water and Gr. *Gennaen*, to produce.) Producing lymph.
- Lymphocyte** (L. *Lympha*, water and Gr. *Kutos*, cell.) A variety of leucocyte found in lymph glands. They are small, with very large nucleus.
- Lymphorrhagia** (L. *Lympha*, water and Gr. *Hragnunai*, to burst forth.) The flow of lymph from a ruptured lymph-vessel.
- Lysis** (Gr. *Luein*, to loose.) A cell product with power of cleavage of other cells or substances.
- Lysis** (Gr. *Luein*, to loose.) A gradual decline. Generally used in combination to signify destruction or breaking up.
- Maceration** (L. *Macerere*, to make soft.) The softening of a solid by soaking in a liquid.
- Macroscopic** (Gr. *Makros*, long and *Skopein*, to view.) Visible with the unaided eye or without the use of a microscope.
- Malformation** (L. *Malus*, bad and *Forma*, form.) An abnormal development of an organ or part.
- Malign** (L. *Malus*, bad.) Likely to kill.
- Mammalia** (L. *Mamma*, breast.) A class of vertebrates that suckle their young.
- Margination** (L. *Marginare*, to furnish with a border.) The act of furnishing with a distinct border. (The accumulation of leucocytes on the interior of a vessel wall.)
- Mast-cell** (Ger. *Mast-zellen*, food-cell.) A large type of leucocytes filled with basophilic granules, highly stainable.
- Melanin** (Gr. *Melas*, black.) A black pigment, natural in some tissues, often pathologic.
- Melanosis** (Gr. *Melas*, black, *osis*, a con-

- dition of.) A condition of abnormal pigmentation with melanin.
- Metabolism** (Gr. Meta, after and Baliein, to throw.) The phenomena by which foodstuffs are transformed into complex tissue-elements or complex tissue-elements are converted into simpler ones in the production of energy.
- Metamorphosis** (Gr. Meta, after and Morphoein, to change, and osis, a condition of.) A change of shape or structure, usually a degeneration.
- Metaphase** (Gr. Meta, after and Phasis, phase.) The second period in indirect cell-division. (Mitosis.)
- Metaplasia** (Gr. Meta, after and Plasis, formation.) The conversion of a developed or matured tissue into another closely related tissue.
- Metastatic** (Gr. Meta, after and Stasis, halt.) Pertaining to Metastasis. The transfer of a disease process from one organ to another by means of blood or lymph.
- Metrorrhagia** (Gr. Metra, uterus and Hregnual, to burst forth.) Hemorrhage from the uterine mucosa, the extravasate being almost wholly retained in the uterus.
- Micron** (Gr. Mikros, small.) One one-thousandth of a millimeter (1-25,000 of an inch). Represented by the greek letter mu.
- Microparasite** (Gr. Mikros, small, Para, beside and Sitos food.) A parasite requiring high magnification for observation.
- Microphyte** (Gr. Mikros, small and Phuton, plant.) A microscopic plant.
- Microscope** (Gr. Mikros, small and Skopein, to view.) Not visible with the unaided eye.
- Microzoon** (Gr. Mikros, small and Zoon animal.) A microscopic animal organism.
- Micturition** (L. Micturire, to urinate.) The passage of urine. Staling.
- Miliary** (L. Millium, millet.) Consisting of small tubercles or nodules of the size of millet seed.
- Mitosis** (Gr. Mitos, thread and osis, a condition of.) Indirect cell-division with formation of thread-like structures. Karyokinesis.
- Mole** (L. Moles, a mass.) A mass formed in the uterus by arrested development or degeneration of a foetus. Also a Nevus.
- Monaster** (Gr. Monos, single and Aster, star.) The single star or wreath in indirect cell-division (mitosis).
- Monochorionic** (Gr. Monos, single and Chorion, a foetal membrane.) Having a single chorion.
- Mononuclear** (Gr. Monos, single and L. Nucleus, nucleus.) Having but one nucleus.
- Morbid** (L. Morbus, disease.) Pertaining to disease.
- Moribund** (L. Moriri, to die.) In a dying condition.
- Morphology** (Gr. Morphe, form and Logos, study.) The study of the form and structure of organized beings.
- Mucus** (L. Mucua.) The viscid fluid secreted by special glands of mucous membranes.
- Multiparous** (L. Multus, many and Pare, to produce.) Bringing forth more than one offspring at a birth.
- Mycelial** (Gr. Mukes, a fungus and Helos, an overgrowth.) Pertaining to a mycelium.
- Mycelium** (Gr. Mukes, a fungus and Helos, an overgrowth.) The vegetative filaments of a fungus.
- Mycosis** (Gr. Mukes, fungus and osis, a condition of.) A growth of fungus in the tissue.
- Myeloid** (Gr. Muelos, marrow and Eidos, like.) Resembling marrow.
- Myoblast** (Gr. Mus, muscle and Blastos, germ.) A cell developing into a muscle fibre.
- Myoma** (Gr. Mus, muscle and Oma, tumor.) A tumor composed of muscle tissue.
- Myositis** (Gr. Mus, muscle and Itis, inflammation.) Inflammation of muscle tissue.
- Myxodema** (Gr. Muxos, mucus and Oidema, oedema.) A condition in which tissues, especially the hands and face, are infiltrated with a mucus-like substance.
- Myxoma** (Gr. Muxos, mucus and Oma, tumor.) A connective-tissue tumor made up of mucin-containing intercellular substance.
- Nascent** (L. Nasciscor, to arise.) Just coming into existence. Just liberated from a chemical compound.
- Necrobiosis** (Gr. Nekros, a corpse and Bios, life.) Gradual and progressive death of a cell or of a group of cells.
- Necrosis** (Gr. Nekros, a corpse.) Death of a tissue suddenly, in mass while surrounded by living tissue.
- Neoformation** (Gr. Neos, new and L. Forma, form.) A circumscribed new growth of tissue of abnormal structure and location and functionless. Tumor.
- Neoplasm** (Gr. Neos, new and Plassein,

- to mold.) A neof ormation, a tumor.
- Neurilemma** (Gr.Neuron, nerve and Lemma, a husk.) The covering-sheath of a nerve-fibre.
- Neuroglia** (Gr.Neuron, nerve and Glia, glue.) The tissue forming the basis of the supporting framework of the central nervous tissue.
- Neuroma** (Gr.Neuron, nerve and Oma, tumor.) A tumor composed of nerve tissue.
- Neuter** (L.Neuter, neither.) Neither the one nor the other. Inactive. Neither acid nor alkaline.
- Neutrophile** (L.Neuter, neither and Gr. Philein, to love.) A cell or structure stainable by neutral dyes.
- Nevus** (L.Nevus, a mole.) A mole. A congenital angioma of the skin. Birthmark.
- Nidus** (L.Nidus, a nest.) The original point of a morbid process or focus of infection.
- Noxious** (L.Noxious, harmful.) Having harmful properties.
- Nucleolus** (L.Nucleus, a small nut and diminutive term.) A small body within the nucleus of a cell.
- Nucleoplasm** (L.Nucleus, a small nut and Gr.Plassen, to mold.) The protoplasm of a nucleus.
- Nucleus** (L.Nucleus, a small nut.) The essential part of a living cell.
- Obligatory** (L.Obligare, to bind.) Bound by conditions, Not facultative.
- Odontoma** (Gr.Odons, tooth and Oma, tumor.) A tumor of tooth-like structure.
- Oedema** (Gr.Oidema, a swelling.) The accumulation and retention of lymph in lymph vessels and spaces. Dropsy.
- Oogenesis** (Gr. Oon, egg and Gennaen, to produce.) The origin and development of the egg.
- Ophthalmia** (Gr.Ophthalmos, the eye.) Inflammation of the structures of the eye.
- Opsonin** (Gr.Opsono, a dainty food.) A product of the body-cells that prepares bacteria for phagocytosis.
- Optimum** (L.Optimus, best.) A condition characterized by the most favorable conditions.
- Organized** (Gr.Organon, organ.) Converted into an organ or organ-like structure.
- Oscillation** (L.Oscillare, to vibrate.) A regular motion back and forth within narrow limits.
- Osmotic** (Gr.Osmos, impulse.) Pertaining to osmosis. The passage of liquids and substances in solution through a membrane.
- Ossification** (L.Ossa, bone and Facere, to make.) The formation of bone.
- Osteitis** (Gr.Osteon, bone and Itis, inflammation.) Inflammation of bone.
- Osteoblast** (Gr.Osteon, bone and Blastos, germ.) A cell of mesoblastic origin concerned in the formation of bone.
- Osteoclast** (Gr.Osteon, bone and Klain, to break.) A large multinuclear cell concerned in the removal of bone.
- Osteophyte** (Gr.Osteon, bone and Phuton, plant.) A bony outgrowth, tree-like in character.
- Otologie** (Gr.Ous, ear and Logos, study.) Pertaining to Otology: The study of the ear.
- Oxyphile** (Gr.Oxus, sharp and Philein, to love.) Stainable with acid dyes.
- Palpated** (L.Palpare, to feel of.) Examined with the hand to determine conditions beneath.
- Paracentesis** (Gr.Para, near and Kentesis, puncture.) Surgical puncture of the walls of a cavity.
- Paralysis** (Gr.Para, near and Luein, to loose.) Loss of sensation or motion in a part.
- Parasite** (Gr.Para, near and Sitos, food.) An organism that gains protection or sustenance or both at the expense of another organism.
- Parenchyma** (Gr.Para, near En, in and Cheem, foundation, to pour in.) The foundation, or essential or functioning portion of a structure.
- Parenchymatous** (Gr.Para, near En, in and Cheem, foundation, to pour in.) Pertaining to or affecting the parenchyma.
- Parietes** (L.Paries, wall.) The enveloping or investing structure of a body cavity.
- Parturition** (L.Parturire, to bring forth.) The act of giving birth to young.
- Pathogenesis** (Gr.Pathos, suffering and Gennaen, to produce.) The origin of disease.
- Pathology** (Gr.Pathos, suffering and Logos, study.) The study of disease.
- Peptons** (Gr.Pepton, digesting.) Proteids formed by the action of pepsin on albumins during digestion.
- Perichondrium** (Gr.Peri, around and Chondros, cartilage.) The fibrous connective-tissue covering of cartilage.
- Perimysium** (Gr.Peri around and Mus, muscle.) The sheath of connective-tissue around a fasciculus of muscle fibres.

- Periosteoid** (Peri, around, Osteon, bone and oid, of the nature of.) Of the nature of periosteum: The sheath of connective tissue around bones excepting on articular surfaces.
- Peripheral** (Gr.Peri, around and Pher-ein, to carry.) Pertaining to the periphery: The external boundary.
- Petrification** (Gr.Petra, a stone and L-Facere, to make.) Conversion into a stone-like substance.
- Phagocytic** (Gr.Phagein, to eat and Kutos, cell.) Pertaining to a phagocyte.
- Phagocytosis** (Gr.Phagein, to eat, Kutos, cell and osis, condition of.) The active functioning of phagocytes. A blood cell that ingests and destroys harmful matter in the tissues.)
- Phlebolith** (Gr.Phlebs, a vein and Lithos, a stone.) A calculus or concretion in a vein.
- Phlegmonous** (Gr.Phlegmone, phlegmon.) Pertaining to phlegmon. (An inflammation characterized by the spreading of purulent fluid in the tissues.)
- Phosphorescence** (Gr.Phosphoros, phosphorous.) The emission of light without appreciable production of heat.
- Photogenic** (Gr.Photos, light and Genna-in, to produce.) Causing or producing light.
- Physiology** (Gr.Phusis, nature and Logos, study.) The study of the functions of the organs of the living body.
- Phytoparasite** (Gr.Phutos, plant, Para, near and Sitos, food.) A parasite vegetable organism.
- Pigmented** (L.Pingere, to paint) A condition to deposition of coloring matter in the tissues.
- Placental** (Gr.Plakous, a cake.) Pertaining to the placenta. The organ of the uterine wall to which the foetus is attached and from which it obtains its nourishment.
- Placentoma** (Gr.Plakous, a cake and Oma, a tumor.) A tumor composed of placental tissue.
- Pleomorphism** (Gr.Pleon, more and Orphe, form.) The state of having more than one form.
- Plexiform** (L.Plexus, braid and Forma, form.) Having the appearance or structure similar to a Plexus. (A network of vessels.)
- Plumbosis** (L.Plumbum, lead and osis, a condition of.) A condition of poisoning by or deposition of lead in the tissues.
- Pneumonokoniosis** (Gr.Pneumon, lung and Konis, dust, osis a condition of.) A condition of chronic induration in the lung tissues due to the deposition of inhaled dust.
- Post-natal** (L.Post, after and Nansisel, to be born) Occuring after birth.
- Polar** (Gr.Polos, pole.) Pertaining to a pole. (Either extremity of an axis.)
- Polydactylism** (Gr.Polus, many and Dektulos, finger.) The condition of having many digits.
- Polygonal** (Gr.Polus, many and Gonos, angle.) Having many angles or sides. (Spoken of a surface.)
- Polyhedral** (Gr.Polus, many and Hedra, side.) Having many sides or surfaces. (Spoken of a solid.)
- Polymeric** (Gr.Polus, many and Meros, part.) Pertaining to the existence of a large number of parts.
- Polymorphonuclear** (Gr.Polus, many, Morphe, form and L.Nucleus, nucleus.) Having nuclei of many forms.
- Potential** (L.Potens, powerful) Capable of doing work or of acting.
- Predisposition** (L.Prae, before, Dis, apart and Ponere, to place.) The condition of liability to acquire a disease.
- Primitive** (L.Primus, first) First in point of time: Original.
- Progeny** (Gr.Pro, before and Genna-in, to produce.) Offspring or descendants.
- Progressive** (L.Pro, before and Gredi, to step.) Gradually advancing or moving forward.
- Prolapse** (L.Pro, forward and Labi, to slip.) The falling downward or forward of a part.
- Proliferate** (L.Pro, forward an Ferre, to bear.) To form new tissue of the same kind (usually excessive.)
- Prolific** (L.Pro, forward and Labi, to slip.) The quality of being able to proliferate.
- Prophase** (Gr.Pro, before and Phasis, phase.) The first stage in indirect cell division (Mitosis.)
- Proteoses** (Gr.Protos, first.) Substances formed in gastric digestion and into intermediate between a proteid and a peptone.
- Protoplasm** (Gr.Protos, first and Plasse-in, to mold.) The viscid, essential substance of a living cell.
- Prototype** (Gr.protos, first and Tupos, type.) An original type, one after which others are copied.
- Protozoa** (Gr.Protos, first and Zoon, animal.) A class of unicellular, animal microorganisms.
- Pseudo** (L.Pseudo, false.) False.

- Psoaspermic** (Gr.Psoa, Itch and Sperma, seed.) Of the nature of or like a Psoasperm. A protozoon. A coccidium.
- Ptomain** (Gr.Ptoma, a corpse.) A product formed in the decomposition of dead animals tissues.
- Purulent** (L.Pus, pus.) Of the nature or associated with pus, upon a surface.
- Pus** (L.Pus, pus.) Liquefied, necrotic tissue composed of altered leucocytes, tissue shreds and usually microparasites, suspended in a fluid (liquor puris.)
- Pustule** (L.Pus, and diminutive term.) A vesicle containing pus.
- Pyogenic** (Gr.Puon, pus and Gennaen, to produce.) Capable of producing pus.
- Pyorrhoea** (Gr.Puon, pus and Hroia, a flow.) A persistent discharge of pus upon a surface.
- Pyrexia** (Gr.Pur, fire and Hexis, a habit.) An abnormal elevation of a temperature. (Fever.)
- Radicular** (L.Radix, root and diminutive term.) Pertaining to or like a radicle or root.
- Ranula** (L.Rana, frog and diminutive term.) A cystic tumor in the mouth (especially on the tongue) due to the obstruction of a gland-duct.
- Receptors** (L.Recipere, to receive.) The "Side-chains" of a body cell (Ehrlich's side-chain theory.)
- Regeneration** (L.Re, again and Genare, to beget.) The process by which destroyed tissues are replaced.
- Remittent** (L.Re, back and Mittere, to send.) Characterized by abatement or subsidence or repetition.
- Resorbed** (L.Re, again and Sorbere, to absorb.) Taken up again into the system. Spoken of a substance that has passed out and accumulated in the tissues.
- Reticular** (L.Reticulum, a little net (Rete). Resembling a net. Formed by a net-work.
- Retrogressive** (L.Retro, backward and Gradus, step.) Of the nature of retrogression. Going backward from a pre-existing condition.
- Rhabdomyoma** (Gr.Rhabdos, a rod, Mus, muscle and Oma, tumor.) A form of muscle-tumor (Myoma), characterized by the presence of striated muscle fibres.
- Rhexis** (Gr.Rhexis, rupture.) The rupture of an organ or vessel.
- Rythm** (Gr.Hruthmos, rythm.) The recurrence of a motion or sound at regular intervals.
- Rupture** (L.Rumpere, to break.) A condition of being broken apart by violence.
- Sacculate** (L.Saccus, a sac and diminutive term.) To form small sacs.
- Sanies** (L.Sanies.) A thin, fetid, sero-purulent fluid discharge from an ulcer, fistula, etc.
- Sanious** (L.Sanies.) Pertaining to or of the nature of Sanies.
- Sapremia** (Gr.Sapros, rotten and Haima, blood.) The entrance into the blood of the products of putrefactive microorganisms.
- Saprogenic** (Gr.Sapros, putrid and Gennaen, to produce.) Causing or producing putrefaction.
- Saprophytic** (Gr.Sapros, rotten and Phytos, plant.) Pertaining to Saprophytes: (Vegetable organisms living on decaying organic matter.)
- Sarcolemma** (Gr.Sarx, flesh and Lemma, a sheath.) The delicate sheath enveloping a muscle fibre.
- Sarcoma** (Gr.Sarx, flesh and Oma, tumor.) A tumor made up of embryonal connective tissue cells.
- Schistosis** (Gr. Schistos, a cleft and osis, a condition of.) A condition of being split or cleft.
- Scirrhus** (Gr.Skirrhos, hard.) Of the nature of a Scirrhus. (A hard tumor: A Carcinoma.)
- Sclera** (Gr.Skleros, hard.) The firm outer coat of the eye-ball continuous with the cornea and optic nerve.
- Secretion** (L.Secernere, to secrete.) The process of separating out a substance from the blood.
- Segmentation-cells** (L.Segmentum from Secare, to cut.) One of the cells of an ovum formed by dividing into two equal parts.
- Senile** (L.Senex, old.) Pertaining to old age.
- Sequel** (L.Sequi, to follow.) A following upon or a resultant of.
- Sequestration** (L.Sequestrare, to separate.) The formation of a sequestrum.
- Sequestrum** (L.Sequestrare, to separate.) A piece of dead bone that has become separated from the sound bone during necrosis.
- Siderosis** (Gr.Sideros, iron and osis, a condition of.) A condition of pigmentation by the deposit, especially in the lungs, of particles of iron.
- Siluroid** (Gr.Siluros, a species of fish.) Pertaining to Siluroidei, an order of fishes.
- Simultaneous** (L.Simul, at the same

- time.) Existing or happening at the same time.
- Sinusoid** (L. Sinus, a cavity and old, of the nature of.) Like a sinus: (A hollow or cavity or tract.)
- Slough** (M.E.Slough, the skin of a snake.) A mass of soft tissue destroyed by necrosis.
- Sloughing** (M.E.Slough, skin of a snake.) The process of becoming a slough.
- Soliped** (L.Solus, alone and Pes, foot.) An animal with a single hoof or digit.
- Somatic** (Gr.Soma, body.) Pertaining to the body, especially to the framework as distinguished from the viscera.
- Specific** (L.Species, species.) Of or pertaining to a species. Produced by a particular kind of organism.
- Specificity** (L.Species, species and Facere, to make.) The quality of being specific.
- Spermatogenesis** (Gr.Sperma, semen and Gennaen, to produce.) The development of Spermatozoa.
- Sphacelus** (Gr.sphakelos, dead.) A mass of soft tissue destroyed by necrosis.
- Spirom** (L.Spira, a coil.) The close or mother-skein of chromatin fibrils in indirect cell division. (Mitosis.)
- Spongoplasm** (Gr.Spoggos, a sponge and Plassen, to mold.) The fine protoplasmic threads forming the reticulum of a cell.
- Spontaneous** (L.Spons, will.) Occurring without external influence.
- Spore** (Gr.Sporos, seed.) A reproductive, resting element of lower organisms.
- Sporulation** (Gr.Sporos, seed and L.Ferre, to make.) The production of spores.
- Stalactite** (Gr.Stalazein, to drop.) A pendant cone of calcium salts like an icicle.
- Stasis** (L. Stare to stand.) A standing still or stoppage of motion, especially of blood, in a part.
- Stenosis** (Gr.Stenos, narrow.) A narrowing of the lumen of a vessel.
- Sterile** (L.Sterilis, barren.) Incapable of reproducing.
- Sthenic** (Gr.Sthenos, strength.) Characterized by strength or severity.
- Strata** (L.Stratum, stratum.) A series of layers.
- Stroma** (Gr.Stroma, a bed.) The tissue forming the ground substance or framework for the essential part of an organ. Interstitial tissue.
- Suggillation** (L.Suggillare, to beat black and blue.) An extensive, capillary, tissue-hemorrhage.
- Suppuration** (L.Sub, under and Pus, pus.) The formation of pus. (Surface or subsurface.)
- Susceptible** (L.Sub, under and Cipere, to take.) Having a liability to acquire a disease.
- Swelling** (A.S.Swellan, to grow larger.) An elevation or elevated area (especially abnormal.)
- Symptom** (Gr.Sun, together and Ptoma, a falling.) Sequential functional disturbances due to disease.
- Synectium** (Gr.Sun, together and Kutos, cell.) A fusion of several cells into a single cell.
- Syncope** (Gr.Sun, together and Koptein, to strike.) A partial or complete, temporary suspension of heart action.
- Synthesis** (Gr.Sun, together and Tithenai, to put.) The formation of a compound by putting together its constituents.
- Systole** (Gr.Sun, together and Stellein, to place.) The period of the heart's contraction especially of the ventricles.—Opposed to Diastole.
- Telophase** (Gr.Telos, end and Phasis, phase.) The fourth and last stage in indirect cell division. (Mitosis.)
- Telangiectatic** (Gr.Telos, end Aggeion, a vessel and Ektasis, a dilatation.) Of or pertaining to Telangiectasis. (A permanent dilatation of groups of capillaries and arterioles.
- Tenable** (L.Tenere, to hold.) Able to be held or supported.
- Teratoma** (Gr.Teras, monster and Oma, tumor.) A tumor composed of tissues derived from all three germ-layers.
- Tetanic** (Gr.Tetanos, tetanus) Pertaining to or resembling tetanus. Characterized by tonic muscular spasms.
- Thermic** (Gr.Therme, heat.) Of or pertaining to heat.
- Thermogenic** (Gr.Thermos, heat and Gennaen, to produce.) Pertaining to causing or producing heat.
- Thermogenesis** (Gr.Therme, heat and Gennaen, to produce.) The generation or production of heat.
- Thermolysis** (Gr.Therme, heat and Luein, to loose.) The loss of heat.
- Thoracischlopagus** (Gr.Thorax, thorax, Ischion, hip and Pagos, union.) A monster with two heads but with bodies and hips united.
- Thrombosis** (Gr.Thrombos, a clot and osis, a condition of.) A condition of the existence of a thrombus.

- Thrombus** (Gr.Thrombos, a clot.) A coagulum formed within a living blood-vessel.
- Tolerance** (L.Tolerare, to endure.) Ability to endure the continuation of an act.
- Tonic** (Gr.Tonikos, tone.) Pertaining to tone. Characterized by continuous tension or contraction, or an agent that tends to restore normal tone.
- Tophi** (Gr.Tophos, a stone.) Hard stone-like deposits.
- Torsion** (L.Torquere, to twist.) A twisting or the act of twisting.
- Toxin** (Gr.Toxikon, a poison.) A nitrogenous product formed by cells. Bacterial toxin.
- Transudate** (L.Trans, through and Sudare, to sweat.) A fluid that has passed through a membrane. Especially non-inflammatory blood serum that has passed through vessel walls.
- Transudation** (L.Trans, through and Sudare, to sweat.) The production of a transudate.
- Traumatism** (Gr.Trauma, a wound and ism, a condition of.) A condition due to an injury or wound.
- Tricephalus** (Gr.Tris, three and Kep-hale, head.) A monster having three heads.
- Trophic** (Gr.Trophic, food.) Pertaining to nutrition.
- Tubercle** (L.Tuber, a swelling and diminutive term.) A small nodule.
- Tumefied** (L.Tumere, to swell and Facere, to make.) In a swollen condition.
- Tumor** (L. Tumere, to swell.) A morbid enlargement. A growth of new tissue non-inflammatory, persistent and independent of the surrounding structures, atypical in structure and function.
- Ulcer** (L.Ulcus.) A denuded surface resulting from a continuous and sometimes progressive cellular necrosis.
- Ulceration** (L.Ulcus, an ulcer.) The formation of an ulcer.
- Ultramicroscopic** (L.Ultra, beyond, Gr.-Mikros, small and Skopein, to look at.) Too small to be seen with a microscope.
- Uniparous** (L.Unus, one and Parere, to produce.) Bringing forth one offspring at a birth.
- Vaccine** (L.Vacca, cow.) An attenuated virus used for inoculation purposes.
- Vacuolated** (L.Vacuus, empty.) A condition of the presence of vacuoles.
- Vacuole** (L.Vacuus, empty.) A space or cavity in the protoplasm of a cell.
- Vascularization** (L.Vasculum, a small vessel.) The process of becoming vascular or of being supplied with vessels.
- Vehicle** (L.Vehere, to carry.) A substance serving to carry or hold another.
- Vesicle** (L.Vesica, a bladder and diminutive term.) A circumscribed accumulation of inflammatory serous exudate in the deeper layers of the epidermis or of the mucosa, usually about pinhead size.
- Villus** (L.Villus, a tuft of hair.) One of the minute projections of the mucous membrane of the intestinal canal.
- Virulency** (L.Virus, a poison.) Pertaining to extreme poisonousness, disease producing power or strength.
- Virulent** (L.Virus, a poison.) Very powerful or Poisonous.
- Vitiligo** (L.Vitiligo, vitiligo.) A skin-disease characterized by disappearance of normal pigment in patches.
- Volvalus** (L.Volvere, to roll.) A Twisting of an organ so as to occlude its lumen.
- Wound** (A.S.Wund, wound.) The result of the sudden interruption of the Continuity of a tissue or tissues.
- Zymogenie** (Zume, leaven and Gennaein, to produce.) Causing or pertaining to fermentation.

INDEX

A

- Abdomino-schisis, 98.
Abscess, cold, 170.
Abscess formation, 169.
Abscess, hot, 170.
Abscess, metastatic, 170.
Absorption of necrotic tissue, 261.
Acardia, 93.
Acaudia, 94.
Acephalus, 93.
Achorion Schoenleini, 49.
Achromatosis, 249.
Acidophiles in inflammation, 152.
Acme, fever, 341.
Acquired disease, 37.
Acquired immunity, 82.
Acquired immunity theories, 87.
Acromegaly, 190.
Actinomycosis, 355.
 Avenue of entrance, 357.
 Differential diagnosis, 360.
 Distribution, 355.
 Etiology, 356.
 Extension, 360.
 Lesions, 358.
 Source of infection, 356.
 Susceptible animals, 355.
Active and acquired immunity, 83.
Acute disease, 35.
Acute inflammation, 173.
Adenoma, 326.
Adenoma clinically, 327.
Adenoma, microscopic, 326.
Adeno-sarcoma, 328.
Adeno-sarcoma, microscopic, 329.
Adipose absorption, 204.
Adipose depositories, 203.
Adipose digestion, 204.
Adipose regeneration, 181.
Aerobic bacteria, 58.
Agastria, 93.
Agglutination test, glanders, 368.
Agnathus, 94.
Albino, 249.
Alveolar-sarcoma, 309.
Amboceptor, 90, 91.
Amelus, 94.
Amitosis, 24.
Amputation neuroma, 182.
Amylus, 93.
Amylin, 210.
Amyloid formation, 211.
Amyloid formation appearance, 211.
Amyloid formation, cause, 211.
Amyloid formation, effects, 211.
Amyloid formation, tissue affected, 211.
Amyloid reaction, 210.
Amyloid test, 211.
Anabolism, 31.
Anærobism, 58.
Anaphase, 28.
Anasarca, 120.
Anatomical alterations, heart, 110.
Anemia, 132.
Angioma, 293.
Anhydremia, 112.
Anomalies, 92.
Ante-natal disease, 37.
Ante-natal hypertrophy, 189.
Anthraxis, 248.
Aplasia, 93.
Apnoea, 77.
Apoplexy, 77.
Aprosopus, 94.
Apus, 94.
Argyriasis, 248.
Arrested development, 93.

Arteriolith, 238.
 Arteriosclerosis, 111.
 Arthropoda, 69.
 Ascites, 119.
 Aspergillus fumigatus, 50.
 Aspergillus, niger, 51.
 Asthenic fever, 342.
 Atheroma, 337.
 Atheromatous degeneration, 229.
 Atresia, 99.
 Atresia anus, 99.
 Atresia iridis, 99.
 Atresia oculi, 99.
 Atresia oris, 99.
 Atresia urethra, 99.
 Atrichia, 93.
 Atrophy, 196.
 Atrophy, appearance, 198.
 Atrophy, cause, 197.
 Atrophy, effects, 199.
 Atrophy, pathologic, 197.
 Atrophy, physiologic, 197.
 Atrophy, senile, 197.
 Autosite, 109.
 Avian tubercular lesion, 352.
 Axone, rate of growth, 182.
 Axone regeneration, 182.

B

Bacilli, 53.
 Bacteria, 52.
 Bacterial immunity, 86.
 Bacterial pigmentation, 60.
 Bacterial proteids, 62.
 Bacterial toxins, 61.
 Bacterium mallei, 362.
 Bacterium tuberculosis, 345.
 Bacterium necrophorus, 253, 254.
 Basophiles, 152.
 Benign tumors, 275.
 Bile concrement, 240.
 Biliar calculi, 236.
 Birth mark, 294.
 Blister, 42.
 Blister test, 265.
 Blood flow in inflammation, 147.
 Blood oscillation, 148.

Blood pressure, 111.
 Blood quality, 111.
 Blood, quantity, 111.
 Blood regeneration, 178.
 Blood stasis, 149.
 Blood vessel regeneration, 178.
 Bovine tubercular lesions, 360.
 Bursattae, 251.

C

Calcareous infiltration, 227.
 Calcareous infiltration, appearance, 228.
 Calcareous infiltration, cause, 227.
 Calcareous infiltration, effects, 229.
 Calcareous infiltration, tissue affected, 229.
 Calculi, 230.
 Calculi arteries, 238.
 Calculi bile ducts, 236.
 Calculi, cause, 230.
 Calculi, color, 231.
 Calculi, composition, 231.
 Calculi, foetus-litho pedium, 238.
 Calculi, gall bladder, 236.
 Calculi, intestine, 236.
 Calculi, kidney, pelvis, 233.
 Calculi, mammary ducts and sinuses, 237.
 Calculi, number, 231.
 Calculi of prepuce, 235.
 Calculi of salivary gland ducts, 235.
 Calculi, shape, 231.
 Calculi, size, 231.
 Calculi, structure, 231.
 Calculi, stomach, 236.
 Calculi, ureter, 234.
 Calculi, urethra, 234.
 Calculi, urinary bladder, 234.
 Calculi, uriniferous tubules, 233.
 Canalization, 178.
 Cancellated osteoma, 288.
 Carcinoma, 320.
 Carcinoma, clinically, 323.
 Carcinoma, differentiation, 323.
 Carcinoma, encephaloid, 320.
 Carcinoma, metastasis, 323.

- Carcinoma, microscopic, 322.
 Carcinoma, scirrhous, 321.
 Capillary telangiectasis, 294.
 Cartilage regeneration, 180.
 Cartilage tumor, 283.
 Caseation necrosis, 257.
 Castration, fatty changes, 205.
 Catarrhal inflammation, 174.
 Cavernous hemangioma, 294.
 Cell, definition, 20.
 Cell growth, 23.
 Cell motion, 29.
 Cell reproduction, 24.
 Cell shape, 23.
 Cell size, 23.
 Cell structure, 21.
 Cell waste, 32.
 Cementoma, 294.
 Centrosome, 22.
 Cerumenous concretions, 241.
 Cervical ectopia cordis, 103.
 Cheiloschisis, 96.
 Chemical causes of disease, 44.
 Chemical composition of exudate, 150.
 Chemical necrosis, 253.
 Chemical reaction, cloudy swelling, 200.
 Chemical reaction, retrograde changes, 195.
 Chemotaxis, 159.
 Chilblains, 144.
 Cholelith, 236.
 Cholesteatoma, 335.
 Chondroma, 283.
 Chondroma, clinically, 285.
 Chondroma, microscopic, 284.
 Chondro-sarcoma, 317.
 Chorio-carcinoma, 331.
 Chorio-epithelioma, 331.
 Chromosome, 27.
 Chronic disease, 35.
 Chronic inflammation, 173.
 Chylous ascites, 117.
 Cicatrization, 185.
 Cilia, 31.
 Circulatory disturbances, 110.
 Cirsoid hemangioma, 295.
 Cladothrix actinomyces, 356.
 Cloacal persistence, 103.
 Cloudy swelling, 200.
 Cloudy swelling, appearance, 202.
 Cloudy swelling, cause, 200.
 Cloudy swelling, effects, 202.
 Cloudy swelling, tissue affected, 202.
 Coagulation necrosis, 256.
 Cobra, 48.
 Coccidium, 371.
 Coccus, 53.
 Colliquation necrosis, 256.
 Colloid formation, 217.
 Colloid formation, appearance, 218.
 Colloid formation, cause, 217.
 Colloid formation, effects 220.
 Colloid tests, 217.
 Color blending, 35.
 Compensatory hypertrophy, 188.
 Complement, 90, 91.
 Complete duplicates, 106.
 Composite odontoma, 293.
 Compound follicular odontoma, 292.
 Concentric hypertrophy, 188.
 Concretions, 238.
 Concretions, bile, 240.
 Concretions, cerumen, 240.
 Concretions, fecal matter, 239.
 Concretions, hair, 238.
 Concretions, milk, 240.
 Concretions, parasitic, 241.
 Concretions, pus, 240.
 Concretions, source, 238.
 Congenital diseases, 37.
 Connective tissue regeneration, 179.
 Contiguity, 75.
 Continued fever, 342.
 Continuity, 75.
 Convalescence, fever, 341.
 Corneal, reaction, 141.
 Cornification, 224.
 Corrosive poisoning, 44.
 Craniopagi, 107.
 Craniorrhachischisis, 95.
 Cranioschisis, 95.
 Crisis, 341.
 Cyclopia, 98.

Cysts, 335.
 Cysts, degeneration, 337.
 Cysts, dermoid, 338.
 Cysts, extravasation, 337.
 Cysts, exudation, 337.
 Cysts, multilocular, 335.
 Cysts, parasitic, 337.
 Cystic calculi, 234.
 Cystoma, 335.

D

Death, 77, 262.
 Death, pathologic, 263.
 Death, physiologic, 262.
 Death signs, 264.
 Death tests, 265.
 Decomposition, 265.
 Deciduoma malignum, 331.
 Decline, fever, 337.
 Degeneration cysts, 334.
 Dentigerous cysts, 334.
 Dentine regeneration, 181.
 Depigmentation, 250.
 Dermoid cysts, 333.
 Diabrosis, 113.
 Diapedesis, 113.
 Dicaudis, 100.
 Dicephalus, 108.
 Diphtheritic inflammation, 171.
 Diplo-coccus, 53.
 Dipygusamelus, 94.
 Dislocation, 40.
 Direct cell division, 24.
 Disease, 35.
 Disease extension, 74.
 Disease termination, 75.
 Dropsy, 118.
 Duplicities, assymetrical, 107.
 Duplicities, free, 106.
 Duplicities, incomplete, 107.
 Duplicities, monochorionic, 106.

E

Eburnated osteoma, 288.
 Ectopia gastrum, 98.
 Egagaropile, 238.

Ehrlich's lateral chain theory, 87.
 Electric causes of disease, 44.
 Embolism, 128.
 Embolism, effects, 130.
 Embolus, 128.
 Embolus air, 128.
 Embolus, bacterial, 128.
 Embolus cells, 128.
 Embolus, location, 129.
 Embolus, parasitic, 128.
 Embolus, thrombic fragments, 128.
 Embryonic epithelial tumors, 321.
 Empyemia, 170.
 Encapsulation of necrotic tissue, 261.
 Encephaloid carcinoma, 321.
 Endermic goitre, 218.
 Endothelial cells in inflammation, 152.
 Endothelioma, 310.
 Endotoxins, 62.
 Enterolith, 236.
 Enterorrhagia, 115.
 Ephemeral fever, 342.
 Epistaxis, 114.
 Epithelial odontoma, 291.
 Epithelial pearls, 225.
 Epithelial regeneration, 181, 182.
 Epithelioma, 324.
 Epithelioma, clinically, 326.
 Epithelioma, microscopic, 325.
 Epithelioma, pearl, 325.
 Epithelioma, seritonale, 331.
 Epithelioma contagiosum, 370.
 Epithelioma contagiosum, cause, 371.
 Epithelioma contagiosum, lesion, 371, 372.
 Epithelization, 185.
 Ergot, 46, 255.
 Erythrocytes in inflammation, 152.
 Etiology, 19.
 Etiology of disease, 38.
 Exciting cause of disease, 40.
 Exfoliation, 261.
 Exhaustion theory of immunity, 87.
 Exophthalmic goitre, 217.
 Extension of disease, 74.
 Extravasate, 184.

Extravasation cysts, 337.
 Exuberant granulation, 187.
 Exudate, 150.
 Exudate, cause, determining kind, 155.
 Exudate, chemical composition, 150.
 Exudate, histological composition, 151.
 Exudate, effects, 155, 157.
 Exudate, fibrinous, 154.
 Exudate, hemorrhagic, 154.
 Exudate, purulent, 155.
 Exudate, serous, 154.
 Exudate, significance of, 156.
 Exudation cyst, 337.

F

Fatty changes, 203.
 Fatty changes, pathologic, 207.
 Fatty changes, pathologic, appearance, 208.
 Fatty changes, pathologic, cause, 207.
 Fatty changes, pathologic, effects, 210.
 Fatty changes, Physiologic, 205.
 Fatty changes, physiologic, appearance, 206.
 Fatty changes, physiologic, cause, 205.
 Fatty changes, physiologic, effects, 206.
 Fatty infiltration, 205.
 Fatty necrosis, 258.
 Favus, 49.
 Fecal concretions, 239.
 Fever, 339.
 Fever, acme, 341.
 Fever, asthenic, 342.
 Fever, continuous, 342.
 Fever, convalescence, 341.
 Fever, course, 340.
 Fever, decline, 341.
 Fever, ephemeral, 341.
 Fever, intermittent, 342.
 Fever, onset, 340.
 Fever, sthenic, 342.

Fibrinous exudate, 154.
 Fibroblasts, 179.
 Fibroma, 278.
 Fibroma, clinically, 280.
 Fibroma, differentiation, 281.
 Fibroma, hard, 279.
 Fibroma, soft, 280.
 Fibro-sarcoma, 312.
 Fibrous hyperplasia, 192.
 Fission, 56.
 Fistulous tracts, 170.
 Flagella, 54.
 Follicular odontoma, 291.
 Focal necrosis, 259.
 Fracture, 40, 183.
 Fracture, repair, 180.
 Freckles, 247.
 Function, variations, 196, 197.

G

Gangrene, 257.
 Gastric calculi, 236.
 Gastroliths, 236.
 General diseases, 38.
 Giantism, 189.
 Glanders, 361.
 Glanders, agglutination test, 368.
 Glanders, avenue of infection, 362.
 Glanders, cause, 362.
 Glanders, diagnosis, 368, 369.
 Glanders, lesions, 363.
 Glanders, mallein test, 368.
 Glanders, course of infection, 362.
 Glioma, 289.
 Glycogen, 221.
 Glycogen composition, 221.
 Glycogen tests, 221.
 Glycogenic infiltration, 221.
 Glycogenic infiltration, appearance, 222.
 Glycogenic infiltration, cause, 222.
 Glycogenic infiltration, effects, 222.
 Goitre, 217.
 Granulation, 185.
 Granulation, exuberant, 187.
 Growth of tumors, 272.

H

- Hair balls, 238.
 Haptophores, 89, 90, 91.
 Health, 35.
 Healing by primary union, 184.
 Healing by granulation, 185.
 Heart anatomical changes, 110.
 Heart diminished action, 110.
 Heart increased action, 110.
 Helminthes, 63.
 Helminthes response to stimuli, 140.
 Hemangioma, 294.
 Hemangioma cavernosum, 294.
 Hemangioma cirroid, 295.
 Hemangioma hyperthopicum, 295.
 Hemangioma simplex, 294.
 Hemangiosarcoma, 318.
 Hematemesis, 114.
 Hematidrosis, 115.
 Hematocele, 115.
 Hematogenous pigmentation, 243.
 Hematoma, 115.
 Hematometra, 115.
 Hematuria, 115.
 Hemic poisons, 45.
 Hemocoelia, 114.
 Hemoglobin in pigmentation, 244.
 Hemolysis, 343.
 Hemophilia, 112.
 Hemoptysis, 114.
 Hemorrhage, 77, 112.
 Hemorrhage, cause, 113.
 Hemorrhage, ecchymotic, 114.
 Hemorrhage, epistaxis, 114.
 Hemorrhage, effects, 115.
 Hemorrhage, petechial, 113.
 Hemorrhage, suggillation, 114.
 Hemorrhagic exudate, 154.
 Hemosiderin, 245.
 Hemotoidin, 245.
 Hemothorax, 115.
 Hepatogenous pigmentation, 246.
 Heredity, 35.
 Heredity in fatty changes, 205.
 Hermaphroditism, 103.
 Hermaphrodite, bilateral, 104.
 Hermaphrodite, lateral, 104.
 Hermaphrodite, false, 104.
 Hermaphrodite, true, 104.
 Hermaphrodite, unilateral, 104.
 Hernia, 40.
 Histoid tumor, 269.
 Humoral theory of immunity, 89.
 Hyalin, 212.
 Hyalin, chemical composition, 213.
 Hyaline formation, 212.
 Hyaline formation, appearance, 213.
 Hyaline formation, cause, 213.
 Hyaline formation, effects, 214.
 Hydrargirosis, 248.
 Hydrops, 118.
 Hydrothorax, 119.
 Hydropericardium, 119.
 Hydrocele, 119.
 Hydrocephalus, 119.
 Hyperchromatosis, 243.
 Hyperæmia, 113.
 Hyperæmia, arterial, 135.
 Hyperæmia, arterial, appearance, 136.
 Hyperæmia, arterial, cause, 135.
 Hyperæmia, arterial, effects, 136.
 Hyperæmia, arterial, pathologic, 137.
 Hyperæmia, arterial, physiologic, 137.
 Hyperæmia, arterial, therapeutic, 137.
 Hyperæmia, Bier's, 134.
 Hyperæmia, venous, 133.
 Hyperæmia, venous, appearance, 133.
 Hyperæmia, venous, cause, 133.
 Hyperæmia, venous, effects, 134.
 Hyperæmia, venous, pathologic, 134.
 Hyperæmia, venous, therapeutic, 134.
 Hypernephroma, 329.
 Hyperplasia, 188.
 Hyperplasia, appearance, 192.
 Hyperplasia, cause, 192.
 Hyperplasia, effects, 193.
 Hyperplasia, fibrous, 192.
 Hyperplasia, interstitial, 191, 192.
 Hyperplasia, parenchymatous, 191.
 Hypertrophy, 188.
 Hypertrophy, ante natal, 189.
 Hypertrophy, appearance, 190.
 Hypertrophy, cause, 189.

- Hypertrophy, compensatory, 188.
 Hypertrophy, concentric, 188.
 Hypertrophy, effects, 190.
 Hypertrophy, general, 189.
 Hypertrophy, inherited, 189.
 Hypertrophy, numerical, 192.
 Hypertrophy, post natal, 189.
 Hypertrophy, false, 188.
 Hypochromatosis, 249.
 Hypoplasia, 93, 94.
- I**
- Icterus, 246.
 Immediate union, 184.
 Immunity, 78.
 Immunity, acquired, 82.
 Immunity, active acquired, 83.
 Immunity, bacterial, 86.
 Immunity, inherited, 80.
 Immunity, passive, 86.
 Immunity, toxic, 84.
 Inanition, necrosis, 254.
 Incision test, 265.
 Indirect cell division, 26.
 Infarct, 131.
 Infarct, anemic, 131.
 Infarct, hemorrhagic, 131.
 Infarction, 131.
 Infective granulomata, 341.
 Inflammation, 138.
 Inflammation, acute, 173.
 Inflammation, catarrhal, 174.
 Inflammation, causes, 143.
 Inflammation, chronic, 173.
 Inflammation, croupous, 171.
 Inflammation, diphtheritic, 171.
 Inflammation, effects, 161.
 Inflammation, factors concerned in, 146.
 Inflammation, hemorrhagic, 172.
 Inflammation, infective, 167.
 Inflammation, interstitial, 173.
 Inflammation, non-suppurative, 167.
 Inflammation, parenchymatous, 173.
 Inflammation, phlegmonous, 170.
 Inflammation, proliferative, 174.
 Inflammation, purulent, 169, 174.
 Inflammation, pustular, 174.
 Inflammation, signs, 160.
 Inflammation, simple, 166.
 Inflammation, specific, 174.
 Inflammation, suppurative, 167.
 Inflammation, termination, 174, 175.
 Inflammation, ulcerative, 174.
 Inflammation, vascular changes, 146, 147, 148.
 Inflammation, vesicular, 174.
 Inflammatory exudate, 150.
 Inflammatory exudation, 149.
 Inherited disease, 35.
 Inherited epilepsy, 37.
 Inherited immunity, 80.
 Inherited malformations, 36.
 Inherited ophthalmia, 37.
 Inherited tumors, 36.
 Inspissated bile, 240.
 Inspissated pus, 240.
 Intermittent fever, 342.
 Interstitial hyperplasia, 191, 192.
 Interstitial inflammation, 170.
 Interstitial expansion, tumor, 272.
 Intestinal calculi, 236.
 Involucre, 261.
 Iodothyreoglobulin, 217.
 Irritability, 32.
 Irritant, 139.
 Ischiopagus, 107.
 Ischiopagus parasiticus, 107.
- J**
- Jack sores, 260.
- K**
- Karyokinesis, 26.
 Katabolism, 31.
 Keloid, 281.
 Keratosis, 224.
 Keratosis, appearance, 225.
 Keratosis, cause, 224.
 Keratosis, effects, 225.

L

Lactation a factor in fatty changes, 205.
 Lacteal calculi, 237.
 Lacteal concretions, 241.
 Lamellæ formation, 181.
 Larkspur, 46.
 Leiomyoma, 296, 297.
 Lesion, 19.
 Leucocytes in inflammation, 151.
 Leucocytes, basophilic, 152.
 Leucocytes, eosinophilic, 151.
 Leucocytes, neutrophilic, 151.
 Leucocytic margination, 150.
 Leucoderma, 250.
 Leucomains, 48.
 Lipoma, 285.
 Lipoma, clinically, 287.
 Lipoma, microscopically, 287.
 Liquor puris, 155.
 Lithopedia, 238.
 Local disease, 38.
 Loco, 47.
 Luxation, 40.
 Lymphocytes in inflammation, 153.
 Lymphangioma, 296.
 Lymphorrhagia, 117.
 Lymphorrhagia, cause, 117.
 Lymphorrhagia, effects, 117.
 Lymphomata, 303.
 Lymphosarcoma, 303.
 Lysis, 341.

M

Malformations, 92.
 Malformations, atypical, 93.
 Malformations, multiple, 101.
 Malformations, single, 93.
 Malformations, typical, 93.
 Malign tumor, 275.
 Mallein, 368.
 Malleination, 368.
 Margination, leucocytic, 150.
 Mechanic causes of diseases, 40.
 Melanin, 247.
 Melano-sarcoma, 315.

Melanosis, 247.
 Membrane, cell, 22.
 Meningocele, 96.
 Metabolism, 31.
 Metaphase, 27.
 Metaplasia, 193.
 Metastases, carcinoma, 323.
 Metastatic tumor, 272.
 Metrorrhagia, 115.
 Microcardia, 94.
 Microcephalus, 94.
 Micrococcus, 53.
 Micrognathus, 94.
 Micromelus, 95.
 Microphthalmia, 94.
 Miliar tubercle, 349.
 Mirror test, 265.
 Mitosis, 26.
 Mixed cell sarcoma, 308.
 Mole, 93.
 Monophagus amelus, 94.
 Monophygosapus, 94.
 Monothoracisamelus, 94.
 Monothoracisapus, 94.
 Moribund stage fever, 341.
 Mosaic coloring, 35.
 Moulds, 49.
 Movement, amoeboid, 30.
 Movement, ciliar, 31.
 Movement, intracellular, 29.
 Mucoïd changes, 214.
 Mucoïd changes, appearance, 215.
 Mucoïd changes, causes, 215.
 Mucoïd changes, effects, 216.
 Mucoïd changes, pathologic, 215.
 Mucoïd changes, physiologic, 214.
 Mucoïd tissue regeneration, 179.
 Mucus, 214.
 Multilocular cysts, 335.
 Multiplicity, 101.
 Mummifying necrosis, 257.
 Muscular tissue regeneration, 182.
 Myeloid sarcoma, 96.
 Myelomeningocele, 96.
 Myocarditis, 110.
 Myoma, 296.
 Myositis ossificans, 226.

Myxoedema, 215.
 Myxoma, 282.
 Myxoma clinically, 283.
 Myxoma microscopically, 282.
 Myxosarcoma, 316.

N

Necrobioses, 251.
 Necrosis, 251.
 Necrosis caseation, 257.
 Necrosis chemical, 253.
 Necrosis coagulation, 256.
 Necrosis colliquation, 256.
 Necrosis fatty, 258.
 Necrosis focal, 259.
 Necrosis inanition, 254.
 Necrosis mummifying, 257.
 Necrosis putrefying, 257.
 Necrosis senile, 258.
 Necrosis subsurface, 256.
 Necrosis surface, 256.
 Necrosis thermic, 254.
 Necrotic stomatitis, 251.
 Nerve tissue regeneration, 182.
 Neuroma, 293.
 Neuromata amputation, 182.
 Neurotoxic poison, 45.
 Neus, 294.
 Neutrophile, 151.
 Nucleus, 22.
 Numerical hypertrophy, 191.
 Nutritive disturbances in atrophy,
 197.

O

Obstructive necrosis, 252.
 Ochronosis, 245.
 Odontoma, 289.
 Odontoma composite, 293.
 Odontoma compound follicular, 292.
 Odontoma, epithelial, 291.
 Odontoma fibrous, 291.
 Odontoma follicular, 291.
 Odontoma, radicular, 293.
 Oedema, 148.
 Oedema appearance, 120.
 Oedema cause, 118.

Oedema effects, 121.
 Oedema varieties, 119.
 Olein, 203.
 Onset fever, 340.
 Ospora porrigenes, 48.
 Ophthalmic tubercular test, 355.
 Organoid tumor, 269.
 Osseous regeneration, 180.
 Ossification, 226.
 Ossification appearance, 226.
 Ossification cause, 226.
 Ossification effects, 226.
 Osteoblasts, 180.
 Osteoclasts, 180.
 Osteoma, 288.
 Osteoma cancellated, 288.
 Osteoma clinically, 289.
 Osteoma eburnated, 288.
 Osteoma microscopic, 289.
 Osteo-cystoma dentiferum capsular,
 292.
 Osteophytes, 226.
 Osteo sarcoma, 318.

P

Palatoschisis, 96.
 Palmatin, 203.
 Papilloma, 318.
 Parasitic causes of disease, 48.
 Parasitic cysts, 337.
 Parasitic theory of tumors, 276.
 Parenchymatous degeneration, 220.
 Parenchymatous hyperplasia, 191.
 Parenchymatous inflammation, 173.
 Parenchymatous poisons, 44.
 Partial recovery, 77.
 Pathogenesis, 19.
 Pathology definition, 19.
 Pathology comparative, 19.
 Pathology general, 19.
 Pathology human, 19.
 Pathology special, 19.
 Pathology veterinary, 19.
 Pathologic anatomy, 19.
 Pathologic atrophy, 197.
 Pathologic death, 263.
 Pathologic physiology, 19.

- Pearl cell epithelioma, 325.
 Peripheral infiltration, 272.
 Persistent foetal structures, 103.
 Phagocyte, 159.
 Phagocytosis, 159.
 Phagocytosis theory, 87.
 Phlebolith, 237.
 Phlegmonous inflammation, 170.
 Phosphorescence, 60.
 Photic cause of disease, 43.
 Physic cause of disease, 42.
 Phyto-parasites, 48.
 Phyto-toxin, 79.
 Pigmentary changes, 241.
 Pigmentation bile, 246.
 Pigmentation carbon, 248.
 Pigmentation cells, 247.
 Pigmentation effects, 249.
 Pigmentation hemoglobin, 243.
 Pigmentation hemosiderin, 245.
 Pigmentation, hemotoidin, 245.
 Pigmentation Iron, 248.
 Pigmentation lead, 248.
 Pigmentation mercury, 248.
 Pigmentation, silver, 248.
 Placentoma, 331.
 Plumbosis, 248.
 Pneumomycosis aspergillosis, 50.
 Pneumonokoniosis, 248.
 Porcine tubercular lesion, 351.
 Polydactylism, 100.
 Polumelusthoracicus, 100.
 Poison, 44.
 Post mortem staining, 264.
 Post natal disease, 38.
 Post natal hypertrophy, 189.
 Predisposition, 35.
 Predisposing causes of disease, 38-40.
 Predisposing causes of age, 38.
 Predisposing causes of breed, 39.
 Predisposing causes of climate, 39.
 Predisposing causes of color, 39.
 Predisposing causes of food and water, 40.
 Predisposing causes of genus, 39.
 Predisposing causes of imitation, 40.
 Predisposing causes of location, 39.
 Predisposing causes of occupation, 40.
 Predisposing causes of overwork, 40.
 Predisposing causes of previous disease, 40.
 Predisposing causes of season, 39.
 Predisposing causes of sex, 39.
 Preputial calculi, 235.
 Pressure atrophy, 196.
 Primary tumors, 272.
 Progressive tissue changes, 177.
 Proliferative inflammation, 174.
 Prophase, 26.
 Prostatic concretions, 241.
 Protoplasm, 20.
 Provisional callous, 181.
 Protozoa, 63.
 Protozoa response to stimuli, 140.
 Pseudo-hermaphrodite, 104.
 Pseudo-hypertrophy, 188.
 Ptomain, 61.
 Purulent inflammation, 169-174.
 Putrefaction, 61.
 Pus, 155-167-168.
 Pus concretions, 240.
 Pustule, 170.
 Pustular inflammation, 174.
 Pygopagus, 106.
 Pyorrhoea, 169.
 Pyrexia, 339.
- R**
- Rachischisis, 95.
 Ranulae, 237.
 Rattlesnake, 48.
 Reaction aseptic injury, 142.
 Reaction, septic injury, 142.
 Receptor, 89-90-91.
 Recovery, 75.
 Regeneration, 177.
 Regeneration adipose, 181.
 Regeneration blood, 178.
 Regeneration blood vessels, 178.
 Regeneration cartilage, 180.
 Regeneration connective tissue, 179.
 Regeneration dentine, 181.
 Regeneration epithelium, 181.

- Regeneration** mucoid, 179.
 Regeneration muscle, 182.
 Regeneration nerve, 182.
 Regeneration osseous tissue, 180.
 Regeneration white fibrous, 179.
 Regeneration yellow elastic, 180.
 Regenerative inflammation, 175.
 Regenerative power, 177.
 Remittent fever, 342.
 Reinnervation, 182.
 Renal adeno-sarcoma, 328.
 Renal tubular calculi, 233.
 Renal pelvis, 233.
 Resistance to tumors, 273.
 Retention cyst, 337.
 Retention theory of immunity, 87.
 Retrogressive tissue changes, 195-6.
 Retrogressive tissue in tumors 274.
 Rhabdomyoma, 297.
 Rhexis, 113.
 Rigor mortis, 264.
 Ringworm, 49.
 Round cell sarcoma, 302.
 Rupture, 40-183.
- S**
- Saccharomyces**, 51.
 Saccharomyces cerevisiae, 51.
 Saccharomyces farciminosus, 52.
 Salivary calculi, 235.
 Saponification, 258.
 Sarcinae, 53.
 Sarcoma, 298.
 Sarcoma alveolar, 309.
 Sarcoma cells, 300.
 Sarcoma mixed cell, 308.
 Sarcoma myeloid cell, 306.
 Sarcoma round cell, 306.
 Sarcoma structure., 301.
 Sarco-chondroma, 317.
 Sarco-endothelioma, 312.
 Sarco-fibroma, 312.
 Sarco-hemangioma, 318.
 Sarco-lymphoma, 303.
 Sarco melanoma, 315.
 Sarco-myxoma, 316.
 Sarco-osteoma, 318.
- Schistosis, 95.
 Schizomycetes, 52.
 Scirrhus carcinoma, 321.
 Sebaceous cyst, 337.
 Secondary tumors, 272.
 Senile atrophy, 197.
 Senile necrosis, 258.
Sequestration, 261.
 Sequestrum, 261.
 Serous exudate, 154.
 Serous inflammation, 220.
 Serous inflammation appearance, 220.
 Serous inflammation cause, 220.
 Serous inflammation effects, 220.
 Siderosis, 248.
 Significance of inflammatory exu-
 date, 156.
 Signs of death, 264.
 Signs of inflammation, 160.
 Situs Viscerum inversus, 102.
 Sodium urate, 223.
 Specific inflammation, 174.
 Specificity law of, 178.
 Spina bifida, 96.
 Spindle cell sarcoma, 325.
 Sporotrichium audouinii, 49.
 Sporulation, 56.
 Stadium decrementi, 341.
 Stadium incrementi, 340.
 Staining, post mortem, 264.
 Stearin, 203.
 Sternopagus, 107.
 Sthenic fever, 342.
 Streptococcus, 53.
 Stimulus, 139.
 Stocking, 121.
 Substitution, 185.
 Sub-surface necrosis, 256.
 Suppuration, 167.
 Suppuration subsurface, 170.
 Suppuration surface, 167.
 Suppurative osteitis, 169.
 Surface necrosis, 156.
 Symmetrical duplicates, 106.
 Synactosis, 95-8.
 Syncope, 77.
 Syncytium, 153.

- Syncytioma malignum, 331.
 Syndactylus, 98.
 Symmelus apus, 99.
 Symmelus dipus, 98.
 Symmelus monopus, 99.
 Synorchism, 99.
 Synophthalmia, 98.
- T**
- Tattooing, 248.
 Temperature, cause of cloudy swelling, 201.
 * Temperature, cause of degenerations, 196.
 Telophase, 28.
 Teratoid tumors, 269.
 Teratoma, 332.
 Termination of disease, 75.
 Tests for death, 265.
 Thermic causes of disease, 42.
 Thermic necrosis, 254.
 Thermogenesis, 340.
 Thermolysis, 340.
 Thoracopagus, 107.
 Thoracoschisis, 97.
 Thrombosis, 122.
 Thrombosis cause, 123.
 Thrombosis, effects, 127.
 Thrombus, 122.
 Thrombus annular, 124.
 Thrombus appearance, 124.
 Thrombus calcification, 127.
 Thrombus complete, 124.
 Thrombus decolorization, 125.
 Thrombus, extension, 124.
 Thrombus infective softening, 126.
 Thrombus location, 123.
 Thrombus organization, 126.
 Thrombus parietal, 124.
 Thrombus red, 124.
 Thrombus simple softening, 125.
 Thrombus white, 124.
 Tinea tonsurans, 49.
 Tophi, 223.
 Toxic immunity, 84.
 Toxophore, 89-90-91.
 Transportation of visceral organs, 102.
 Traumatic wounds, 184.
 Tricephalus, 109.
 Tricophyton tonsurans, 49.
 Tubercle, 349.
 Tuberculin, 354.
 Tuberculin test, 354.
 Tuberculosis, 344.
 Tuberculosis extent, 344.
 Tuberculosis etiology, 345.
 Tuberculosis avenue of infection, 346.
 Tuberculosis source of infection, 346.
 Tuberculosis lesions, 347.
 Tuberculosis extension, 353.
 Tuberculosis elimination, 354.
 Tumors, 267.
 Tumors benign, 277.
 Tumors body resistance, 273.
 Tumors cause, 275.
 Tumors cells, 269.
 Tumors clinically, 275.
 Tumors color, 271.
 Tumors consistency, 272.
 Tumors extension, 272.
 Tumors frequency, 268.
 Tumors growth, 272.
 Tumors histoid, 277.
 Tumors intercellular substance, 269.
 Tumors malign, 277.
 Tumors metastasis, 272.
 Tumors mottled, 271.
 Tumors number, 272.
 Tumors nutritive supply, 269.
 Tumors organoid, 277.
 Tumors primary, 272.
 Tumors retrogressive changes, 274.
 Tumors secondary, 272.
 Tumors shape, 271.
 Tumors size, 270.
 Tumors structure, 268.
 Tumors teratoid, 277.
 Tumors varieties, 277.
 Twins, 106.

U

Ulcer, 164.
 Ulceration, 164.
 Ulcerative inflammation, 174.
 Union dorsal, 106.
 Union posterior, 106.
 Union ventral, 106.
 Urates, 223.
 Uratic infiltration, 223.
 Uratic infiltration appearance, 223.
 Uratic infiltration cause, 223.
 Uratic infiltration effects, 224.
 Ureter calculi, 234.
 Urethral calculi, 234.
 Uric acid, 223.

V

Valvular insufficiency, 110.
 Valvular stenosis, 110.
 Varieties of tumors, 277.
 Vascular buds, 178.
 Vascular constriction, inflammation,
 146.
 Vascular dilation, 147.
 Vascular permeability, 111.
 Vascular regeneration, 178.
 Vascular variations, 111.
 Vascularization, 178-185.
 Venesection in fatty changes, 205.

Venom, 48.
 Vesicle, 42.
 Vesicular inflammation, 174.
 Viper, 48.
 Vitiligo, 250.

W

Wandering cells, 152.
 White fibrous regeneration, 179.
 Wound, 40.
 Wound cause, 184.
 Wound healing, 184-5.
 Wound subsurface, 184.
 Wound surface, 184.
 Wound traumatic, 184.

X

Xanthosis, 245.
 Xiphopagi, 107.

Y

Yellow elastic regeneration, 184.

Z

Zooparasites, 63.
 Zootoxins, 78.

Kinsley

RSL
-1162

Vet. pathology

LIBRARY
COLLEGE OF AGRICULTURE
UNIVERSITY OF WISCONSIN
MADISON





b89047189329a